

Are your **MRI contrast agents** cost-effective?

Learn more about generic **Gadolinium-Based Contrast Agents**.



**FRESENIUS
KABI**

caring for life

AJNR

**Evaluation of high-resolution CT and MR
cisternography in the diagnosis of
cerebrospinal fluid fistula.**

P G Shetty, M M Shroff, D V Sahani and M V Kirtane

AJNR Am J Neuroradiol 1998, 19 (4) 633-639

<http://www.ajnr.org/content/19/4/633>

This information is current as
of April 19, 2024.

Evaluation of High-Resolution CT and MR Cisternography in the Diagnosis of Cerebrospinal Fluid Fistula

Prashant G. Shetty, Manu M. Shroff, Dushyant V. Sahani, and Milind V. Kirtane

PURPOSE: We undertook this study to determine the accuracy of MR cisternography and plain high-resolution CT as a noninvasive alternative to CT cisternography in the diagnosis of CSF fistula in patients with clinically suspected CSF rhinorrhea.

METHODS: Forty-five consecutive patients with clinically suspected CSF rhinorrhea were examined prospectively for CSF fistula with MR cisternography and plain high-resolution CT. Twenty-one patients also underwent CT cisternography. The MR imaging technique included 3-mm thin-section T1-weighted coronal sequences and fast spin-echo T2-weighted coronal, axial, and sagittal sequences in the supine position. The plain high-resolution CT study included 3-mm and sometimes 1- to 1.5-mm thin coronal sections in the prone position. Similar sequences were used after injecting nonionic contrast material intrathecally via lumbar puncture for the CT cisternographic study. The plain high-resolution CT and MR cisternographic studies were compared with results of CT cisternography; surgical findings were used as the standard of reference.

RESULTS: Plain high-resolution CT successfully depicted the presence or absence of CSF fistula in 42 of 45 patients, whereas MR cisternography was correct in 40 patients. MR cisternography or plain high-resolution CT correctly showed the site(s) of CSF fistula leakage in 36 of the 38 cases proved surgically. The combined techniques also correctly indicated the absence of CSF leakage in seven cases, six of which were confirmed at CT cisternography. Both MR cisternography and high-resolution CT failed to definitively locate the CSF fistula in two patients. High-resolution CT was accurate in 93% of patients, whereas MR cisternography was accurate in 89% of patients. The combination of high-resolution CT and MR cisternography was accurate in 96% of patients.

CONCLUSION: In the presence of clinically diagnosed CSF leakage, the combination of MR cisternography and plain high-resolution CT is highly accurate in locating the site and extent of CSF fistula and should be considered a viable noninvasive alternative to CT cisternography.

CSF fistula has always been a diagnostic challenge. It is imperative to precisely locate the site of CSF fistula whenever surgical intervention is considered. Accurate localization enhances the chance of successful preoperative identification of the site of CSF fistula and dural repair, thereby eliminating the chance

of negative or recurrent explorations. Accurate preoperative localization has become especially important since the emergence of newer minimally invasive surgical techniques in which nasal endoscopes are used for the treatment of CSF fistula and the field of view is limited.

Numerous techniques, including plain skull radiography, pluridirectional tomography, intraoperative injection of fluorescein dye, positive contrast (iopendylate) studies, and radionuclide cisternography, are all helpful in a limited way. For over a decade, CT cisternography has been considered the most reliable and accurate method of diagnosing CSF fistula; however, this technique is invasive and time-consuming, and is contraindicated in patients with active meningitis.

MR cisternography is a noninvasive technique that can detect a CSF fistula by the inherent bright signal

Received July 21, 1997; accepted after revision October 20.

Supported by the National Health and Education Society.

Presented in part at the Annual National Neurosurgery Conference, Calcutta, India, December 1996.

From the Departments of Imaging (P.G.S., M.M.S., D.V.S.) and Otolaryngology (M.V.K.), P. D. Hinduja National Hospital and Medical Research Centre, Bombay, India.

Address reprint requests to Prashant G. Shetty, P. D. Hinduja National Hospital and Medical Research Centre, Veer Savarkar Marg, Mahim, Bombay 400 016, India.

TABLE 1: Pathogenesis of CSF rhinorrhea in 45 patients with clinically suspected CSF fistula

	No. of Patients
Trauma	21
Noniatrogenic	18
Iatrogenic	3
Spontaneous	24

of CSF on T2-weighted images. High-resolution CT is highly effective in the demonstration of small defects in bone at the site of a CSF fistula. Both these techniques are safe, less time-consuming than CT cisternography, and have a high patient compliance rate.

Methods

Forty-five consecutive patients with clinically diagnosed CSF rhinorrhea underwent MR cisternography and plain high-resolution CT for the diagnosis of CSF fistula. The two tests were performed within a day of each other in all patients. No provocative maneuvers were used during the studies. Twenty-one of the patients also underwent CT cisternography within 2 weeks of the noninvasive studies. The MR cisternographic and plain high-resolution CT studies in all patients were interpreted separately by two neuroradiologists, who reached a consensus after combining the results from preoperative localization of the CSF fistula. When both high-resolution CT and MR cisternography were in agreement as to the location of a CSF fistula, CT cisternography was performed only at the behest of the referring clinician. This was especially the case early in the series. CT cisternography was performed most commonly when results of MR cisternography and high-resolution CT were not in agreement (four patients) or were negative (six patients).

The CT protocol was conducted on CT 9800 Hi Lite Quick and Hi Speed CT/i scanners in which 1- to 1.5-mm contiguous coronal sections were obtained through the region of interest after 3-mm routine sections were obtained through the floor of the anterior cranial fossa, the roof of the sphenoidal sinus, and the temporal bones (in five cases) in the prone position. The field of view was 120 mm and the matrix was 512×512 . Axial sections were obtained in patients with suspected CSF leakage at the temporal bones. A bone algorithm was used for greater bone detail. The high-resolution CT criteria included a bone defect with CSF-density fluid communicating from the subarachnoid space extracranially, a bone defect with air communicating from the paranasal sinuses intracranially, and/or herniation of brain/meninges extracranially.

MR cisternography was performed using a 1.5-T Magnetom SP 6000 (Siemens, Erlangen) unit. Coronal, axial, and sagittal fast spin-echo T2-weighted images were obtained with parameters of 6000/90/1 (TR/TE/excitation) in the supine position, because we found that patients felt uncomfortable in the head coil in the prone position, which led to degradation of image quality. T1-weighted coronal sections were obtained with 3-mm thin sections with a 0.1 distance factor, a field of view of 230 mm, and a matrix of 192×256 . The MR criteria for locating CSF leakage included a CSF column communicating from the subarachnoid space extracranially and/or herniation of brain tissue/meninges extracranially.

Subjects ranged in age from 3 to 62 years; 28 were male and 17 were female. Twenty-eight patients had active CSF leakage at the time of the study; in 21 cases the CSF fistula was generated by trauma, in the remaining 24 patients it arose spontaneously (Table 1). None of the patients with spontaneous CSF fistula had raised intracranial pressure. The presence of a bone defect without concomitant communication of CSF/air or herniation of brain tissue/meninges extracranially was not

considered a site of CSF fistula. Thirty-eight of the 45 patients underwent surgical treatment for CSF fistula. Patients with CSF fistula at the cribriform plate, fovea ethmoidalis, or sphenoid roof underwent nasal endoscopic surgery.

The term active CSF leakage indicates the presence of CSF leakage at the time of clinical presentation; likewise, inactive CSF leakage indicates lack of CSF leakage at the time of clinical presentation. The surgeons identified the site of CSF leakage at the time of surgery, correlating their findings with those on the imaging study.

Results

Of the 45 patients, six with inactive CSF leakage did not have a CSF fistula either on MR cisternograms or high-resolution CT scans. CT cisternography also did not reveal CSF fistula in these patients. Of these six patients, three had recurrent low-grade pyogenic meningitis; one of these three (case 36) underwent surgery for mastoiditis; no parameningeal focus was identified in the other two. The remaining three patients had paranasal inflammatory mucosal disease. None of the six had clinical evidence of CSF leakage during a 1-year follow-up period. One patient had nasal drip (clinically active CSF leak) 6 months after surgery, but no definite evidence of CSF fistula was identified on plain high-resolution CT or MR cisternography. CT cisternography was not performed in this patient, as laboratory analysis of the fluid excluded the presence of CSF.

Of the remaining 38 patients, both MR cisternography and plain high-resolution CT could not convincingly demonstrate CSF fistula in two patients. In one of these (case 3), with active CSF leakage, CT cisternography showed the site to be at the junction of the fovea ethmoidalis and cribriform plate, which was confirmed surgically. In the second patient (case 25), with inactive CSF leakage, the CSF fistula was at the lamina cribrosa of the internal auditory canal, and this patient proved to have a Mondini deformity at surgery; CT cisternography was not performed. CT cisternography (performed in 21 patients) produced findings that were in complete agreement with surgical results; there was also a high degree of concordance between CT cisternography and plain high-resolution CT and MR cisternography.

In three patients, high-resolution CT convincingly showed the CSF fistula where MR cisternography failed. Two patients (cases 11 and 38) had 2-mm defects at the cribriform plate, whereas the third patient (case 31) had a posttraumatic fracture involving the lamina cribrosa and vestibulocochlear complex. CT cisternography and surgery confirmed the site of CSF fistula in these patients. In one patient (case 33), MR cisternography showed the fistula to be at the roof of the frontal sinus. High-resolution CT of this patient showed the bone defect without the CSF column density. CT cisternography and surgery confirmed the site of CSF fistula. MR cisternography correctly identified the site of CSF fistula in 40 of 45 patients (accuracy, 89%). Plain high-resolution CT successfully depicted the site of CSF fistula in 42 patients (accuracy, 93%). MR cisternography and

TABLE 2: Sites of documented CSF fistula

	No. of Patients
Cribriform plate	13
Fovea ethmoidalis	2
Cribriform plate and fovea ethmoidalis	8
Frontal sinus	4
Planum sphenoidale	3
Sphenoidal sinus	2
Lamina cribrosa of internal auditory canal	4
Frontal sinus and fovea ethmoidalis	2
Cribriform plate to planum sphenoidale	1
Posterior wall of internal auditory canal	1
Frontal sinus to planum sphenoidale	1

high-resolution CT were in agreement in 38 of 45 patients (accuracy, 85%). At least one of these techniques correctly identified the presence or absence of CSF fistula in 43 patients (sensitivity, 95%; accuracy, 96%).

While MR cisternography had a sensitivity and specificity of 87% and 100%, respectively, high-resolution CT had a sensitivity of 92% and a specificity of 100%. When MR cisternography and plain high-resolution CT were combined, and the study was considered positive on the basis of detection of CSF fistula by any one of the two studies, accuracy was 96%, sensitivity was 95%, and specificity was 100%. The most common site of CSF fistula was the cribriform plate (12 patients, 32%), whereas seven patients (18%) had leakage at the junction of the cribriform plate and fovea ethmoidalis (Table 2). Interestingly, four patients (11%) had CSF leakage through the lamina cribrosa (two traumatic and two congenital, associated with Mondini deformity). Three patients with multiple trauma had CSF fistulas at more than one site. Two patients had additional bone defects besides those at the site of CSF fistula that did not show any evidence of CSF leakage at imaging or endoscopic surgery.

CT cisternography was performed in 21 (46%) of the 45 patients. Although this technique provided additional useful information in only one patient, it increased confidence in excluding CSF fistula in six patients. The CSF leakage stopped immediately after surgery in all 37 patients. No patient who was followed up had any clinical evidence of CSF rhinorrhea. Of the five patients who consented to follow-up imaging studies, none showed radiologic evidence of CSF fistula. CT cisternography indicated the presence or absence of CSF leakage in all 21 patients in whom it was performed. It also helped increase the confidence of the radiologist and the clinician in the diagnosis of CSF leakage during the initial part of the study as well as in the six patients in whom CSF fistula was not evident on the noninvasive studies.

Discussion

Over the years, different techniques have yielded varying rates of success in attempts to accurately locate CSF fistulas. Precise localization of a CSF

fistula helps in surgical planning and enhances the chance of successful dural repair, thus precluding negative or recurrent explorations. Surgical plugging of a CSF fistula is important, as the fistula can be a source of recurrent pyogenic meningitis (1). Current investigators have put the risk of recurrent pyogenic meningitis at 4% (1, 2).

For more than a decade contrast-enhanced CT cisternography has been considered the standard of reference for the diagnosis of CSF fistula (3). CT cisternography has a higher success rate than other techniques in locating CSF leaks, reaching 92% in active leaks and 40% in inactive leaks (4). However, CT cisternography is invasive, time-consuming, slightly uncomfortable for the patient, and carries a slight risk for such complications as headache and infection; moreover, it is relatively contraindicated in patients with active meningitis (4) or raised intracranial pressure.

The recent quantum leap in computer technology has resulted in better quality images, both in CT and MR imaging. Thinner sections (up to 1 mm) with high spatial resolution can be obtained with the modern CT scanner in a much shorter period of time. T2-weighted fast spin-echo MR imaging provides better quality thin-section images in a shorter time, thus reducing motion-related artifacts. This technique also allows a definite reduction in the degree of paramagnetic susceptibility artifacts emanating from the air-bone interface at the skull base as well as from dental fillings and braces as compared with conventional T2-weighted imaging (6). Previous studies have shown that detection of a CSF fistula by plain CT alone is low (7, 8). Eljamel et al (9) showed that plain high-resolution CT was accurate in the localization of inactive CSF fistula in 10 of the 21 patients in their series. However, in our series, high-resolution CT correctly identified a CSF fistula or the lack of it in 16 of 17 patients with inactive CSF leak (Table 3). Of the remaining 28 patients, with active CSF leakage, high-resolution CT could correctly identify the fistula or its absence in 26 cases (accuracy, 93%). High-resolution CT is extremely useful in the identification of bone defects (Fig 1). It is also useful in detecting fractures that are or could be the site(s) of CSF leakage.

MR cisternography can noninvasively demonstrate CSF leakage in multiple planes without the disadvantage of ionizing radiation. On the T2-weighted fast spin-echo sequence, the bright signal emanating from the CSF column is well seen against the black background of air in the paranasal sinuses (Fig 2). The bone defect may, however, not always be well appreciated on MR images. The literature is limited concerning the use of MR cisternography for localization of CSF fistulas, but recent studies have recommended its use as a primary investigative tool for diagnosing CSF fistula (4, 9-12).

In our study, MR cisternography could accurately depict a CSF fistula or its absence in 24 of 28 patients (accuracy, 86%) with active CSF rhinorrhea (Table 3). These results are contrary to the findings described by Eljamel et al (9), who hypothesized that

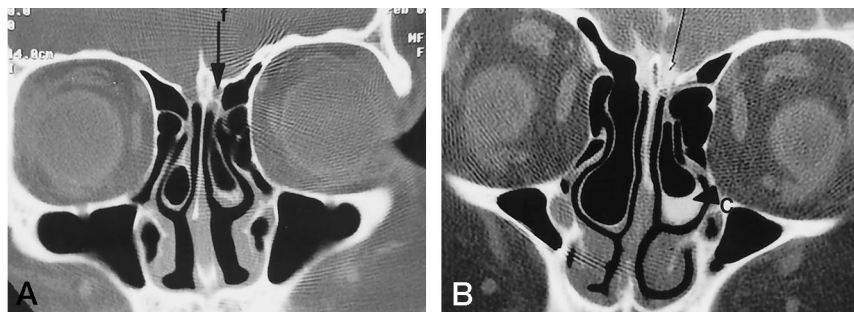


FIG 1. A, Plain high-resolution coronal CT scan, 1-mm thick, through the cribriform plate reveals a bone defect in the left cribriform plate (arrow) with a CSF-density column extending extracranially.

B, After cisternography, coronal high-resolution CT scan through the same region reveals contrast leakage through the bone defect (arrow). Note pooled contrast material (C) within the left concha bullosa (arrowhead).

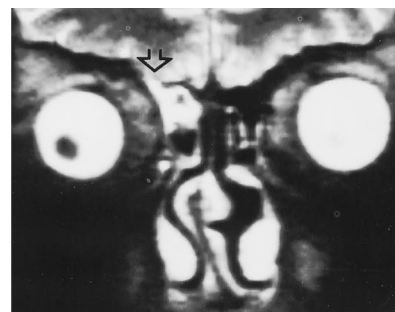


FIG 2. Fast spin-echo T2-weighted coronal MR image through the frontal sinus shows a hyperintense CSF column extending extracranially through the defect at the roof of the right frontal sinus (arrow).

MR cisternography may not be useful for studying patients with active CSF leakage. Their contention was that the high flow rate of CSF may result in loss of signal indistinguishable from bone, thus resulting in false-negative studies. However, in our experience, we had no difficulty in identifying the CSF column at the site of the fistula in patients with active CSF leakage. We believe that flow of CSF through the bony defect and complex maze of air cells of the bony labyrinth in the paranasal sinuses is not fast enough to cause loss of signal.

MR cisternography complements high-resolution CT in demonstrating the extracranial extension of the CSF column (Fig 3). Indirect evidence of CSF fistula is provided by the presence of a low-lying gyrus rectus if the leak is in the region of the cribriform plate (gyrus rectus sign). This is possibly caused by the negative pressure created by the fistula (Fig 4). This sign was positive in 14 (52%) of the 27 cases of CSF fistula seen in the region of the cribriform plate. Four more patients had brain tissue herniation at other sites of CSF fistula. The leaked CSF that sometimes gets collected in the paranasal sinuses has a characteristic signal that can generally distinguish it from inflammatory paranasal secretions (Fig 5). The pooled extracranial CSF is typically more hypointense than the proteinaceous inflammatory secretions on T1-weighted images, which have a brighter signal (11). However, it may sometimes be difficult to distinguish pooled CSF from acute sinus secretions, as the mucosal secretions can also appear relatively dark on T1-weighted images and bright on T2-weighted images.

In our series, four patients had CSF leakage through the lamina cribrosa of the internal auditory canal. In two of these patients, the pathogenesis was traumatic whereas in the other two the leakage was caused by a Mondini deformity (Fig 6). Spontaneous CSF fistula through the lamina cribrosa of the internal auditory canal is a well-described entity (12–14). In one child, with Mondini deformity (case 25), both MR cisternography and high-resolution CT were equivocal (statistically false negative) in the diagnosis of CSF leakage, although the patient underwent surgery on the basis of indirect findings on MR cister-

TABLE 3: Types of CSF leakage

Inactive CSF Leakage (17 Patients)	
MRC:	HRCT:
TP = 10	TP = 10
TN = 6	TN = 6
FN = 1	FN = 1
FP = 0	FP = 0
MRC/HRCT: accuracy = 94%, sensitivity = 91%, specificity = 100%, PVP = 100%, PVN = 86%.	
Active CSF Leakage (28 Patients)	
MRC:	HRCT:
TP = 23	TP = 25
TN = 1	TN = 1
FN = 4	FN = 2
Accuracy = 86%	Accuracy = 93%
Sensitivity = 85%	Sensitivity = 93%
Specificity = 100%	Specificity = 100%
PVP = 100%	PVP = 100%
PVN = 20%	PVN = 33%
Combined Active and Inactive CSF Fistulas	
MRC:	HRCT:
Accuracy = 89%	Accuracy = 93%
Sensitivity = 87%	Sensitivity = 92%
Specificity = 100%	Specificity = 100%
PVP = 100%	PVP = 100%
PVN = 58%	PVN = 70%

Note.—TP indicates true positive; TN, true negative; FN, false negative; FP, false positive; MRC, MR cisternography; HRCT, high-resolution CT; PVP, predictive value positive; PVN, predictive value negative.

nography and high-resolution CT, because the parents were reluctant to authorize CT cisternography. The indirect findings consisted of fluid in the middle ear cavity and dysplastic vestibulocochlear complex in the clinical setting of bilateral otorrhoea. In another patient, with a posttraumatic lamina cribrosa defect, high-resolution CT showed the defect with leakage of CSF into the middle ear whereas MR cisternography was inconclusive, as the thin bone defect could not be identified.

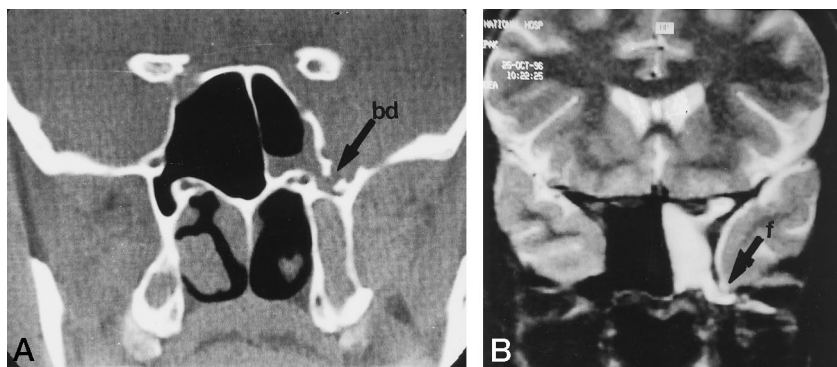


FIG 3. A, Plain high-resolution coronal CT section through the sphenoidal sinus shows a bone defect (bd) at the left lateral recess (arrow) with CSF-density fluid extending into the sphenoidal sinus.
 B, Coronal T2-weighted fast spin-echo MR image through the same region shows hyperintense CSF column extending through this defect (arrow) into the sphenoidal sinus. Note pooling of CSF (f) in the sphenoidal sinus due to supine position of the patient.

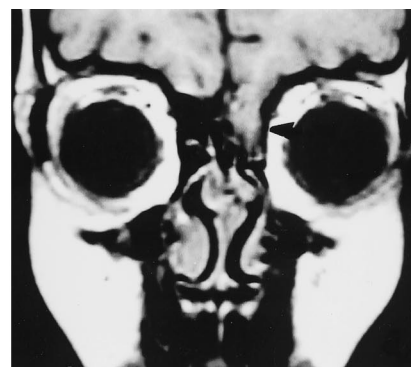


FIG 4. T1-weighted coronal MR image shows presence of herniated gyrus rectus through the left cribriform plate and fovea ethmoidalis (arrowhead).

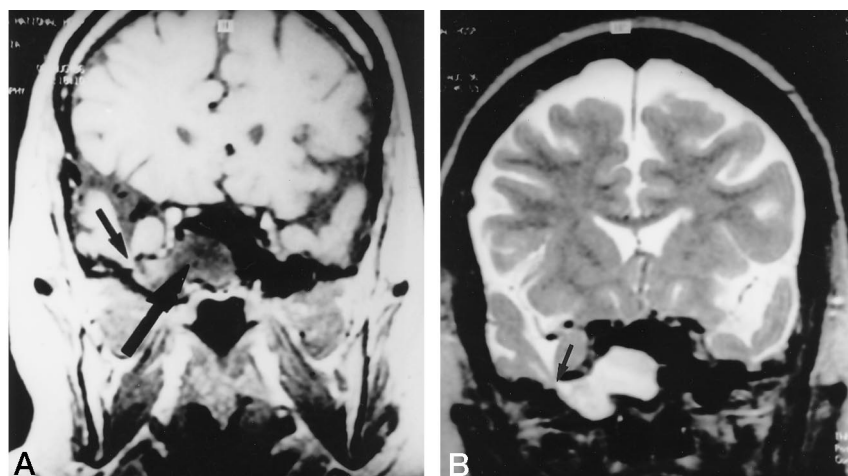


FIG 5. A, T1-weighted coronal MR image through the sphenoidal sinus reveals CSF fistula involving the right lateral recess of the sphenoidal sinus. Brain tissue is seen to extend into this defect (small arrow). Note the characteristic hypointense nature of the pooled CSF in the sphenoidal sinus (large arrow).
 B, Fast spin-echo T2-weighted coronal sequence also shows the CSF fistula (arrow).

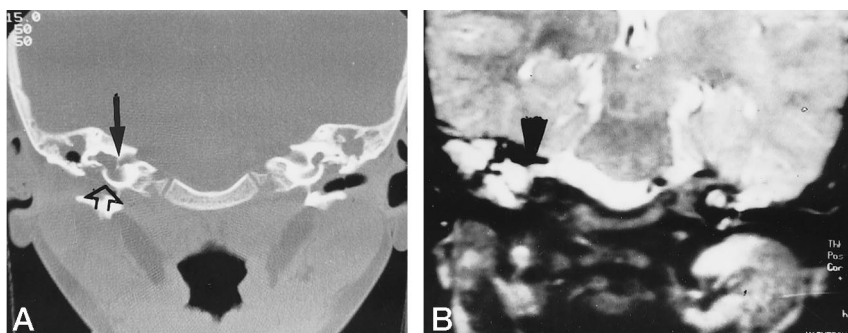


FIG 6. A, Plain high-resolution coronal CT section through the temporal bone reveals a bony defect at the lamina cribrosa of the right internal auditory canal (closed arrow). The vestibulocochlear complex is dysplastic and the cochlea is represented by a saclike diverticulum (open arrow).
 B, Fast spin-echo T2-weighted coronal MR image shows the hyperintense CSF extending through the lamina cribrosa of the internal auditory canal (arrowhead).

High-resolution CT is extremely useful in the detection of thin fractures involving the inner ear structures and therefore greatly increases confidence in the diagnosis of CSF otorrhoea associated with suspected CSF fistula in the temporal bone. High-resolution CT in conjunction with MR cisternography also proved to be useful in the diagnosis of postoperative leakage through the pneumatized posterior wall of the internal auditory canal in a patient with acoustic schwannoma. The ability of CT to obtain 1-mm thin sections coupled with bone algorithm to enhance bone detail has

significantly improved the detection of tiny CSF fistulas. High-resolution CT showed an accuracy, sensitivity, and specificity of 92%, 92%, and 100%, respectively, as opposed to MR cisternography, in which accuracy, sensitivity, and specificity were 89%, 87%, and 100%, respectively. This difference may possibly be attributed to the thinner sections possible with high-resolution CT as compared with MR imaging. However, with the newer MR technology and high-resolution images, the accuracy of this technique may increase. CT is also useful in patients with multiple fractures of the skull base, in

FIG 7. A, Plain high-resolution coronal CT scan reveals a CSF fistula (arrow) at the left cribriform plate and fovea ethmoidalis with a pool of CSF in the ethmoidal air cells.

B, Fast spin-echo T2-weighted coronal MR image through the same region also shows the fistula.

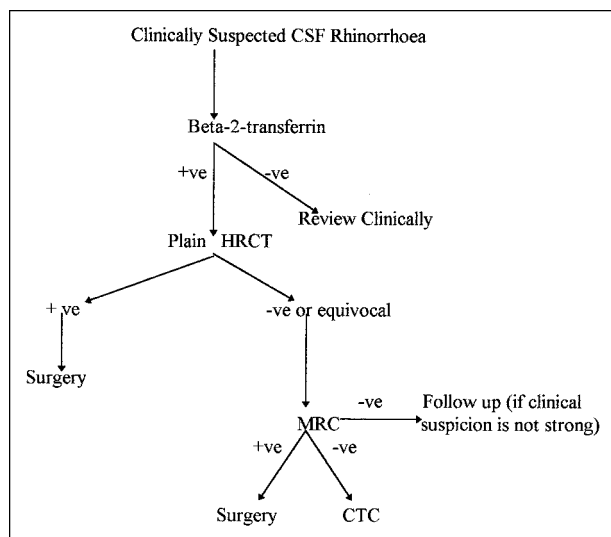
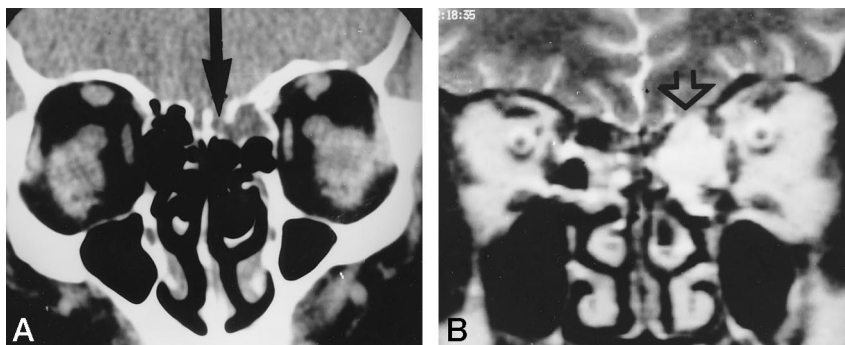


FIG 8. Flow chart shows an algorithm for performing CT cisternography (CTC). +ve, positive; -ve, negative; HRCT, high-resolution CT; MRC, MR cisternography.

that bone defects can be identified and studied with high-resolution CT sections as well as with MR cisternography to document the site(s) of CSF leakage.

While high-resolution CT is useful in detecting bone defects, MR cisternography is helpful in depicting the CSF column extending extracranially (Fig 7). These techniques therefore complement each other, and together the accuracy, sensitivity, and specificity were 96%, 95%, and 100%, respectively. The positive predictive value for both active and inactive CSF leakage on plain high-resolution CT and MR cisternography was 100%. However, these tests may not be very accurate in the detection of CSF leaks in patients in whom CSF rhinorrhea is not clinically indicated. All patients in this study underwent imaging only on the basis of a high clinical index of suspicion for CSF rhinorrhea. It would have been useful to evaluate the nasal fluid by laboratory analysis for the presence of CSF in doubtful cases of CSF leakage. β_2 -transferrin analysis has recently gained favor in the identification of CSF. The protein is highly specific for human CSF, and only a small sample size ($< 1 \text{ cm}^3$) is required without the need for special handling or refrigeration (2). This test was not used in our study population owing to availability constraints; however, it would

certainly have eliminated the need to perform imaging in at least some of the seven patients in whom CSF leakage was not seen at MR cisternography, high-resolution CT, or CT cisternography. Instead, we relied on CT cisternography for these six patients to confirm the absence of a CSF fistula. Also, interobserver variation has not been studied. We suggest that other workers undertake such trials to establish the reliability of this technique with respect to observer and instrument variations. (The negative predictive value for both active and inactive CSF leakage on plain high-resolution CT was 70%; and for MR cisternography it was 58%.)

In two patients, both plain high-resolution CT and MR cisternography could not depict the CSF fistula proved at surgery. In the first patient (case 3), with active CSF leakage at the junction of the fovea ethmoidalis and cribriform plate, surgery showed a hair-line defect extending anteroposteriorly. Even retrospectively this was difficult to appreciate on high-resolution CT and MR cisternography. In the second patient (case 25), with inactive CSF leakage and a Mondini deformity, plain high-resolution CT and MR cisternography revealed indirect evidence of CSF leakage through the lamina cribrosa in the form of fluid in the middle ear cavity and a dysplastic vestibulocochlear complex. No continuous communication of CSF from the basal cisterns to the middle ear cavity was demonstrable by MR cisternography or plain high-resolution CT. The CSF fistula was subsequently proved surgically.

It is important that an experienced radiologist monitor these imaging studies, especially the plain high-resolution CT examination, so as to obtain thinner (up to 1-mm) sections through the region of interest. The optimum window and level for appropriate documentation of subtle CSF fistulas can be obtained only on the CT monitor.

High-resolution CT scans would presumably be difficult to interpret in the presence of soft tissue in the paranasal sinuses (eg, inflammatory secretions or polyps) or in the middle ear cavity, although we did not encounter this problem in our series. It would also be difficult to rely only on high-resolution CT in the presence of multiple fractures of the skull base, as hematoma or fibrous tissue in the paranasal sinuses may preclude optimum evaluation of the correct site(s) of CSF fistula. Similarly, MR cisternography in isolation may not show the fracture site(s) in these

patients, although the CSF column extending extracranially is often seen well. Thus, in cases of multiple fractures of the skull base with a possibility of more than one CSF fistula, a combination of high-resolution CT and MR cisternography may be useful, and CT cisternography may have to be performed only in cases in which the findings are equivocal.

Conclusion

High-resolution CT should be the first line of investigation in patients with clinically diagnosed CSF rhinorrhea (and after confirming the presence of CSF by laboratory analysis in doubtful cases). MR cisternography may be performed if the findings on CT scans are equivocal or if one wishes to focus on the suspected site of CSF leakage seen at CT. If either of these techniques fail to convincingly show a CSF fistula, CT cisternography may be performed as a last resort, preferably with a nasal pledget, as the leakage could be too slow to be detected on a routine study (Fig 8). High-resolution CT or MR cisternography is also useful for following up patients who have had surgery for CSF fistula. We believe this algorithm represents a cost-effective, noninvasive alternative for the demonstration of CSF fistula in patients in whom CSF rhinorrhea is suspected clinically.

Acknowledgments

We thank Ms. Lakshmi for secretarial assistance. Special thanks to Rachna Shah (Lecturer, Preventive and Social Medicine, B.Y.L. Nair Hospital) for her help with the statistical analysis of this work.

References

1. Eljamel MS, Fay PM. **Acute traumatic cerebrospinal fluid fistula: the risk of intracranial infection.** *Br J Neurosurg* 1990;11:205-207
2. Zlab MK, Moore GF, Daly DT, Yonkers AJ. **Cerebrospinal fluid rhinorrhoea; a review of literature.** *Ear Nose Throat J* 1992;71:314-317
3. Creamer MJ, Blendonophy P, Katz R, Russell E. **Coronal computerized tomography and cerebrospinal fluid rhinorrhoea.** *Arch Phys Med Rehabil* 1992;73:599-602
4. Eljamel MS, Pidgeon CN, Toland J, et al. **MRI cisternography and the localisation of CSF fistula.** *Br J Neurosurg* 1994;8:433-437
5. Prere J, Puech JL, Deroover N, et al. **Cerebrospinal fluid rhinorrhoea and meningitis due to post traumatic osteo-meningeal defects in the anterior cranial fossa: diagnosis with water soluble CT cisternography.** *J Neuroradiol* 1986;3:278-285
6. Jone JKM, Mulkern RV, Schwartz RB, et al. **Fast spin echo MR imaging of the brain and spine: current concepts.** *AJR Am J Roentgenol* 1992;158:1313-1320
7. Manelfe C, Cellier P, Sobel D, et al. **Cerebrospinal fluid rhinorrhoea: evaluation with metrizamide cisternography.** *AJR Am J Roentgenol* 1982;138:471-476
8. Ray BS, Bergland RM. **Cerebrospinal fluid fistula: clinical aspects, techniques of localisation and methods of closure.** *J Neurosurg* 1969;30:399-405
9. Eljamel MS, Pidgeon CN. **Localisation of inactive cerebrospinal fluid fistula.** *J Neurosurg* 1995;83:795-798
10. Wakhloo AK, van Velthoven V, Schumacher M, Krauss JK. **Evaluation of MR imaging, digital subtraction cisternography and CT cisternography in diagnosing CSF fistula.** *Acta Neurochir* 1991;111:119-127
11. McConachie NS, Joseph VB, Eljamel MS, Stafford Johnson BD. **Magnetic resonance cisternography of cerebrospinal fluid otorhinorrhoea.** *Int J Neuroradiol* 1995;1:177-181
12. Shetty PG, Shroff MM, Kirtane MV, Karmarkar SS. **CSF otorhinorrhoea in patients with defects through the lamina cribrosa of the internal auditory canal.** *AJNR Am J Neuroradiol* 1997;18:478-481
13. Schuknect HF. **Mondini dysplasia: a clinical and pathological study.** *Ann Otol Rhinol Laryngol* 1980;89:3-23
14. Burton EM, Keith JW, Linden BE, Lazar RH. **CSF fistula in a patient with Mondini's deformity: demonstration by CT cisternography.** *AJNR Am J Neuroradiol* 1990;11:205-207