

**Are your MRI contrast agents cost-effective?**

Learn more about generic Gadolinium-Based Contrast Agents.



**FRESENIUS  
KABI**

caring for life

**AJNR**

**Arytenoid cartilage sclerosis: normal variations and clinical significance.**

I M Schmalfuss, A A Mancuso and R P Tart

*AJNR Am J Neuroradiol* 1998, 19 (4) 719-722

<http://www.ajnr.org/content/19/4/719>

This information is current as  
of April 9, 2024.

# Arytenoid Cartilage Sclerosis: Normal Variations and Clinical Significance

I. M. Schmalfuss, A. A. Mancuso, and R. P. Tart

**PURPOSE:** Our purpose was to determine the variation in location, distribution, and sex predilection of arytenoid cartilage sclerosis in a population of patients without laryngeal cancer as an aid to understanding the significance of this entity when seen in patients with laryngeal cancer.

**METHODS:** One hundred CT examinations of patients of different ages and with no history of laryngeal cancer or radiation therapy were evaluated for the presence of arytenoid cartilage sclerosis. The arytenoid cartilage was subdivided into three regions: superior process, body, and vocal process. Each region was assessed on each side separately on bone window scans.

**RESULTS:** Arytenoid cartilage sclerosis was seen in 16% ( $n = 16$ ) of the patients. Sclerosis was most common in the body ( $n = 12$ ) and least common in the true vocal process ( $n = 2$ ); the left side was the preferred location for all three regions. In 50% of the patients, at least two regions were affected. Eighty-one percent of sclerotic arytenoid cartilage was seen in women.

**CONCLUSION:** Knowledge of the frequency and distribution of arytenoid cartilage sclerosis as a normal variant can aid in determining the risk of arytenoid cartilage involvement in patients with laryngeal cancer.

The radiologist evaluating a CT scan in a patient with laryngeal carcinoma may be faced with the problem of deciding whether a sclerotic portion of laryngeal cartilage is due to tumor involvement or is simply a normal variation. In some patients this decision might affect the treatment plan. Recent work has described the appearance and frequency of sclerosis of the arytenoid cartilage in patients with laryngeal cancer on cross-sectional imaging studies, especially CT scans (1–4). It is now well established that sclerosis of ossified portions of laryngeal cartilage may be the only sign of early cartilage invasion (1–3). However, if sclerosis of cartilage is present next to a tumor, the risk of invasion is only 30% to 50% (1–3). The remaining percentage of sclerotic change is believed to be due to irritation of the cartilage by the adjacent tumor, which produces reactive bony changes without direct invasion. Osteoradionecrosis and/or chronic inflammation (5) could also produce such sclerosis in the absence of tumor, but some of the sclerotic cartilage may represent a normal variation or be due to undiagnosed conditions. To our knowledge, there are no data regarding time of oc-

currence, frequency, distribution, and sex predilection of arytenoid cartilage sclerosis in healthy subjects on cross-sectional imaging studies. Previous studies have analyzed the density of arytenoid cartilage on plain films, predominantly on lateral views of the cervical spine and larynx, or pathoanatomically in cadavers (6, 7). This study seeks to establish the range of appearance of the arytenoid cartilage on CT scans in adults without abnormalities and/or symptoms related to laryngeal disease. Understanding this range of normal variation may help the radiologist to determine the significance of arytenoid cartilage sclerosis in patients with laryngeal cancer.

## Methods

We analyzed 100 CT studies of the neck performed in our institution during 1993. The 100 studies comprised 41 female patients and 59 male patients. Mean age was 48 years, with a standard deviation of 21 years (range, 3 to 94 years) (Fig 1). In two studies, one image through the arytenoid cartilage in each patient was degraded by motion artifacts and the data through this region (in one patient through the superior process and in one patient through the body of the arytenoid cartilage) were marked as “not available,” resulting in a total of 99 scans evaluated at these specific levels.

Only studies from patients without signs or symptoms, clinical findings, or history of laryngeal malignancy or previous radiation therapy to the neck were included for evaluation. To ensure appropriate assessment, image quality was graded on a scale of 1 to 5, with 5 representing excellent image quality and 1 indicating a nondiagnostic study. All scans with a grade lower than 3 (approximately 5%) were excluded from the study.

Received May 27, 1997; accepted after revision October 6.

From the Department of Radiology, University of Florida, Gainesville.

Address reprint requests to Ilona Schmalfuss, MD, Department of Radiology, Box 100 374, University of Florida, Gainesville, FL 32610.

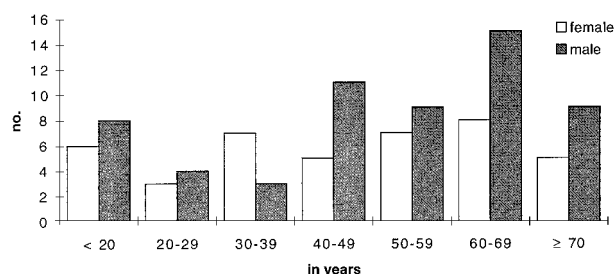


FIG 1. Graph shows distribution of patient population by sex and age group (n = 100).

Limitations in image quality were predominantly due to shoulder and motion artifacts.

The CT scans were obtained with a maximum section thickness of 3 mm and maximum intersection gap of 2 mm. All investigations were performed on a GE 9800 scanner. Scans were obtained with a soft-tissue algorithm and in soft-tissue and bone windows. For the analysis of arytenoid cartilage, only the scans obtained in a bone window were used.

Sclerosis of the superior process, body, and vocal process of the arytenoid cartilage was recorded separately as present or absent for each arytenoid cartilage in every patient. Sclerosis was defined as increased medullary density. All charts of patients with a sclerotic arytenoid cartilage were reviewed to exclude any laryngeal symptoms, remote history of head and neck malignancy, and possible radiation therapy to the neck. Any current or remote disease that might be related to cartilage sclerosis was noted. In addition, patients' smoking history, serum calcium, and uric acid levels were recorded when available.

All scans were independently evaluated by two radiologists familiar with cross-sectional studies of the head and neck area. In case of disagreement, the decision was made by consensus with the help of the most experienced head and neck radiologist in our institution.

Female and male patients with arytenoid cartilage sclerosis were compared by using a nonparametric  $\chi^2$ -test.

## Results

### Overall Findings

Sclerosis of portions or the entire arytenoid cartilage was seen in 16 (16%) of 100 patients. The most commonly involved area of the arytenoid cartilage was the body, the least common area was the vocal process. In 50% of the studies, at least two regions of the arytenoid cartilage were involved. The rest of the studies were divided equally between patients with isolated unilateral or bilateral sclerosis of the superior process or the body.

The left side was involved more often; isolated right-sided sclerosis was seen in only two (12.5%) of 16 scans when sclerosis was present. Bilateral sclerosis was present in seven (44%) of the 16 patients with unusual radiodense arytenoid cartilage. In all those patients, the sclerosis of the arytenoids was symmetric. The remaining seven patients had only left-sided sclerosis of one or multiple subdivisions of the arytenoid cartilage.

Thirteen (81%) of the 16 patients with sclerotic arytenoids were female and three (19%) were male.

### Superior Process of the Arytenoid Cartilage

Eleven (11%) of 99 studies showed sclerosis of the superior process; of these, involvement was bilateral in six cases (55%) and unilateral in five (45%) (Fig 2). In unilateral sclerosis of the superior process, the left side was involved more often than the right: four scans versus one (80% versus 20%). Ten of these 11 studies were of women (91%) while only one was of a man (9%); the male patient had unilateral left-sided sclerosis of the superior process. This female predominance was statistically significant ( $\chi^2 = 13.109$ ,  $P = .0003$ ). Two of the 11 patients with sclerosis of the superior process were 38 and 39 years old, respectively, while the remaining nine were over 50 years old. Isolated sclerosis of one or both superior processes without involvement of any other portion of the arytenoid cartilage was seen in four (25%) of the 16 patients with sclerosis.

### Body of the Arytenoid Cartilage

Twelve (12%) of 99 scans showed sclerosis of the body of the arytenoid cartilage. Sclerosis was bilateral in only two (17%) of the 12 patients and unilateral in 10 (83%) (Fig 3). As seen in unilateral sclerosis of the superior process, the left side was involved more often (eight patients versus two). The female predominance was again statistically significant ( $\chi^2 = 6.787$ ,  $P = .0092$ ), with nine women (75%) and three men (25%) showing sclerosis of this portion of the arytenoids. The youngest patient in this group was 26 years old and one patient was 30 years old; the remaining 10 patients were over 50 years old. Isolated sclerosis of the body, without involvement of any other portion of the arytenoid cartilage, was seen in four (25%) of the 16 patients with sclerosis of at least one portion of the arytenoid cartilage.

### Vocal Process of the Arytenoid Cartilage

Sclerosis of the vocal process was seen on only two (2%) of the 100 scans. Both cases were in women with unilateral left-sided involvement (Fig 4): an 80-year-old woman had additional sclerosis of the body and superior process on the left side and a 30-year-old woman also had involvement of the arytenoid body on the same side. Statistical analysis was not applied owing to the low number of patients in this group.

The results are summarized in the Table. The given frequencies in percent were calculated in regard to the total number (n = 16) of patients with sclerosis of at least one portion of the arytenoid cartilage.

Of the 16 patients with arytenoid cartilage sclerosis, four (25%) were active smokers and two (12%) had a remote history of smoking (both had stopped smoking more than 16 years earlier). For seven patients (44%), no data were available in this regard, and the remaining three (19%) had never smoked.

Serum calcium levels were available in seven (44%) and uric acid levels in eight (50%) of the 16 patients with arytenoid cartilage sclerosis. All the results were normal.

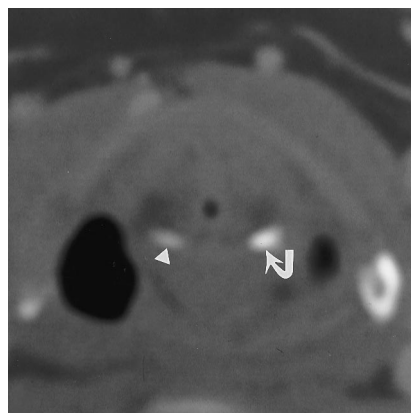


FIG 2. CT scan through the superior process of the arytenoid cartilage obtained in a bone window shows marked sclerosis of the superior process on the left side (*arrow*) as compared with the right (*arrowhead*). This scan was obtained as a follow-up examination in an asymptomatic 39-year-old woman after superficial parotidectomy on the right for benign pleomorphic adenoma 1 year before this study.

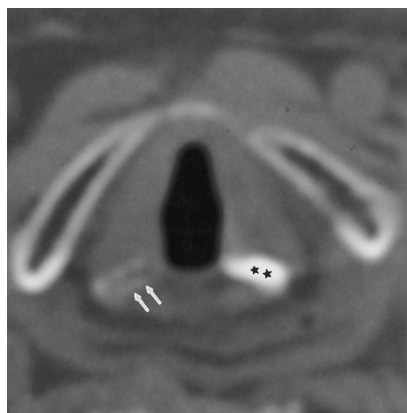


FIG 3. CT scan in a 72-year-old woman with a history of pemphigus with involvement of the face, pharynx, and eye, but normal false and true vocal cord function at the time of this study. Note significant sclerosis of the body of the arytenoid cartilage on the left side (*stars*). The body of the right arytenoid cartilage (*arrows*) is normal in appearance.

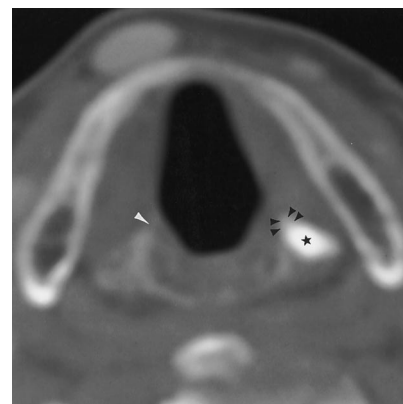


FIG 4. CT scan in an 80-year-old woman at the level of the vocal process of the arytenoid cartilage obtained in a bone window shows marked sclerosis of the body of the arytenoid cartilage (*star*) as well as of the vocal process (*black arrowheads*) on the left side. The vocal process on the right (*white arrowhead*) is normal in appearance. This study was obtained for staging of a hard-palate lesion, which proved to be a carcinoma in situ at pathologic examination.

#### Summary of results subdivided by location of sclerosis, age, and sex

Age Group	No. (%) of Occurrences								
	Superior Process			Body			Vocal Process		
	Right	Left	Bilateral	Right	Left	Bilateral	Right	Left	Bilateral
20-29									
Female	...	...	...	...	...	1 (6.25)	...	...	...
Male	...	...	...	...	...	...	...	...	...
30-39									
Female	...	...	2 (12.5)	...	1 (6.25)	...	...	1 (6.25)	...
Male	...	...	...	...	...	...	...	...	...
40-49									
Female	...	...	...	...	...	...	...	...	...
Male	...	...	...	...	...	...	...	...	...
50-59									
Female	...	...	1 (6.25)	...	1 (6.25)	...	...	...	...
Male	...	1 (6.25)	...	...	1 (6.25)	...	...	...	...
60-69									
Female	...	1 (6.25)	3 (18.75)	...	2 (12.5)	1 (6.25)	...	...	...
Male	...	...	...	...	...	...	...	...	...
≥70									
Female	1 (6.25)	2 (12.5)	...	1 (6.25)	2 (12.5)	...	...	1 (6.25)	...
Male	...	...	...	1 (6.25)	1 (6.25)	...	...	...	...

The chart review of all 16 patients with arytenoid sclerosis revealed three cases in which the arytenoid cartilage could be attributed to a preexisting condition. A 63-year-old woman had a history of rheumatoid arthritis that was treated with prednisone and methotrexate; however, she did not report any laryngeal dysfunction, and the clinical examination of the head and neck region was also unremarkable. Her CT scan showed symmetric, bilateral sclerosis of the superior process of the arytenoid cartilage. A 72-year-old woman had a long-standing history of pemphigus of the face, pharynx, and eye that was treated with

prednisone and cyclophosphamide. On previous and current clinical examinations, no involvement of the larynx itself was seen, and the function of the true and false vocal cords was normal. Scar tissue and small webs were identified superior to the false vocal cord level and in the subglottic region. Scarring in the subglottic region caused a soft subglottic stenosis leading to tracheotomy placement. The CT study showed only left-sided sclerosis of the superior process and body of the arytenoid cartilage. A 63-year-old woman had a remote history of severe burns of the left upper torso, which had occurred 16 years

prior to evaluation of the CT study. No involvement of the larynx and trachea was seen. Since the injury, the patient lost her thumb and incurred cervical contractures on the left side, which were surgically corrected 3 years after the accident. During this surgery, problems with intubation were noted. The evaluated CT scan revealed bilateral and symmetric involvement of the superior process and unilateral left-sided sclerosis of the body of the arytenoid cartilage.

### Discussion

Recent publications have emphasized the presence and significance of sclerotic laryngeal cartilage in patients with carcinoma of the larynx (1, 2, 3, 8). The specific pattern of normal ossification and calcification of the laryngeal skeleton has been described only on plain films or by pathologic evaluation of cadaveric larynges, although the tendency for variation in mineralization and calcification of these cartilages is a generally accepted concept (6, 7). Gläser et al (9) reported that the calcification of the hyaline cartilage is caused by degenerative changes of glycosaminoglycans, which induce precipitation and coagulation of mucopolysaccharide-calcium complexes. Engelmann et al (7) saw the first changes of cell degeneration in a laryngeal cartilage specimen of a 17-year-old girl.

Our results indicate that arytenoid cartilage sclerosis occurs far more commonly in females than in males. This seems to correlate with the trend noted by Curtis et al (6), who found that females tend to show calcification of the vocal process more often than males. No sex distribution was given for calcifications in the other portions of the arytenoid cartilage. Our study also supports a left-sided preference for sclerosis among all evaluated portions of the arytenoid cartilage. There is no such trend in the pathologic literature concerning calcification of normal cartilage (6, 7).

There is only limited information regarding pathologic conditions other than cancer that can cause sclerosis of the arytenoid cartilage. Benjamin et al (5) reported a high correlation between vocal cord granuloma and focal or diffuse sclerosis of the arytenoid cartilage, which was evident in all 21 of their male patients on CT scans. They suggested that the sclerosis might be reactive to hyperemia and other inflammatory changes in the perichondrium. Such an underlying pathogenesis may have been present in our patient with pemphigus and burns; even though laryngeal involvement was not documented at any time,

it might have occurred between clinical examinations. Alternatively, there may have been no symptoms, or they may have been masked by other more significant problems. We believe that the sclerotic changes in the patient with rheumatoid arthritis were not caused by the underlying disease. Previous publications have documented changes only in the cricoarytenoid joints (10, 11). In our patient, the sclerosis was present in both superior processes, which are remote from the cricoarytenoid joint.

### Conclusion

Sclerosis of the arytenoid cartilage is most often seen as a normal variant on the left side in female patients. Sclerosis of the arytenoid cartilage is unusual in males, and if seen in a male patient with laryngeal cancer is more likely to be due to the adjacent tumor.

### References

1. Muñoz A, Ramos A, Ferrando J, et al. **Laryngeal carcinoma: sclerotic appearance of the cricoid and arytenoid cartilage: CT-pathologic correlation.** *Radiology* 1993;189:433-437
2. Becker M, Zbären P, Laeng H, et al. **Neoplastic invasion of the laryngeal cartilage: comparison of MR imaging and CT with histopathologic correlation.** *Radiology* 1995;194:661-669
3. Hermans R, Bellon E, Van Den Bogaert W, et al. **Value of CT-depicted cartilage invasion as a predictor of outcome of laryngeal cancer treated with radiation therapy alone.** *Radiology* 1995;197(P):345
4. Pameijer FA, Mancuso AA, Mendenhall WM, Parson JT, Mukherji SK, Kubilis PS. **Can pretreatment computed tomography predict local control in pyriform sinus carcinoma treated with definitive radiotherapy?** *Head Neck* (in press)
5. Benjamin B, Roche J. **Vocal granuloma, including sclerosis of the arytenoid cartilage: radiographic findings.** *Ann Otol Rhinol Laryngol* 1993;102:756-760
6. Curtis DJ, Allman RM, Brion J, Holborow GS, Brahman SL. **Calcification and ossification in the arytenoid cartilage: incidence and patterns.** *J Forensic Sci* 1985;30:1113-1118
7. Engelmann G, Leutert G. **Zu Alternsveränderungen der Cartilago Arytenoidea.** *Z Mikrosk Anat Forsch* 1989;4:597-619
8. Pameijer FA, Mancuso AA, Mendenhall WM, Parson JT, Kubilis PS. **Can pretreatment computed tomography predict local control in T3 squamous cell carcinoma of the glottic larynx treated with definitive radiotherapy?** *Int J Radiat Oncol Biol Phys* 1997;37:1011-1021
9. Gläser A. **Zur Biorheutischen Orthologie und Pathologie der Tracheobronchialknorpels.** *Z Altersforsch* 1958-1959;3:257-273
10. Brazeau-Lamontague L, Charlin B, Levesque RY, Lussier A. **Criccoarytenoiditis: CT assessment in rheumatoid arthritis.** *Radiology* 1986;158:463-466
11. Charlin B, Brazeau-Lamontague L, Levesque RY, Lussier A. **Criccoarytenoiditis in rheumatoid arthritis: comparison of fibrolaryngoscopic and high resolution computerized tomographic findings.** *J Otolaryngol* 1985;14:381-386