

Are your **MRI contrast agents** cost-effective?

Learn more about generic **Gadolinium-Based Contrast Agents**.



**FRESENIUS
KABI**

caring for life

AJNR

'Leave me alone' lesions of the petrous apex.

K R Moore, H R Harnsberger, C Shelton and H C Davidson

AJNR Am J Neuroradiol 1998, 19 (4) 733-738

<http://www.ajnr.org/content/19/4/733>

This information is current as
of April 20, 2024.

'Leave Me Alone' Lesions of the Petrous Apex

Kevin R. Moore, H. Ric Harnsberger, Clough Shelton, and H. Christian Davidson

PURPOSE: When troublesome MR imaging findings are noted in the petrous apex, the radiologist must determine if the area in question needs surgical therapy. Two nonsurgical entities, asymmetric fatty marrow and fluid-filled petrous air cells (trapped fluid), can be noted on conventional brain MR images and confused with pathologic lesions. Our observation that radiologists do not always confidently define the nonsurgical petrous apex lesions precipitated this investigation.

METHODS: Twenty-three patients with either asymmetric fatty marrow (six) or unilateral effusion in a pneumatized petrous apex (17) on MR images were studied. Eighteen patients underwent high-resolution temporal bone CT. For all patients, the medical charts were reviewed retrospectively and/or the surgical and clinical follow-up findings were reviewed with the referring physician.

RESULTS: In the patients with asymmetric fatty marrow, MR signal intensity followed fat on all sequences. The questioned apex in the patients with trapped fluid showed mixed MR signal characteristics (low to high T1 signal, high T2 signal). CT scans confirmed nonexpansile air-cell opacification.

CONCLUSION: Asymmetric fatty marrow in the petrous apex and petrous air-cell effusions have characteristic MR and CT features that facilitate their correct diagnosis. Effusions with intermediate or high T1 signal are most frequently confused with cholesterol granulomas. In those patients, long-term CT follow-up may be helpful to confirm their stability.

Although approximately 33% of people have pneumatized petrous apices (1, 2), petrous apex lesions are uncommon. With the exception of malignant neoplasms, nearly all abnormalities of the petrous apex are directly related to the presence of pneumatization. The differential diagnosis of petrous apex lesions includes congenital entities (asymmetric fatty marrow, cholesteatoma), infection (apical petrositis), benign obstructive processes (effusion, mucocele, cholesterol granuloma), benign tumor (meningioma, schwannoma), malignant tumor (chordoma, chondrosarcoma, osteosarcoma, plasmacytoma, metastasis), and miscellaneous lesions (histiocytosis X, Paget disease, fibrous dysplasia, petrous carotid artery aneurysm, meningocele/encephalocele). Because the petrous apex is not amenable to direct clinical inspection, imaging studies are a valuable addition to the workup of petrous apex disease.

Of the above entities, two may have MR imaging features that cause concern but are in reality nonsur-

gical lesions. Both asymmetric fatty marrow and unilateral trapped fluid can be misconstrued by the unwary radiologist as a cholesterol granuloma. Unfortunately, these two processes, which might be termed 'leave-me-alone' lesions of the petrous apex, are frequently identified during conventional brain MR imaging performed for unrelated clinical symptoms. Careful inspection of all MR imaging sequences often suggests the correct diagnosis, but in equivocal cases, high-resolution, bone-only, temporal bone CT may be useful. We review these two entities and describe a practical approach to their imaging workup.

Methods

Patient Data

The cases of 23 patients (ages 13 to 64 years) with either asymmetric fatty marrow distribution in the petrous apex or unilateral effusion in a pneumatized petrous apex on conventional brain MR images were collected over an 8-year period (1989 to 1997). In each case, the referring clinician or radiologist identified an area of concern in the petrous apex on conventional brain MR images.

High-resolution CT of the temporal bone was obtained in 18 of these patients. The available hospital or office charts were reviewed retrospectively and/or findings were followed up by conversation with the referring physician. A review of the literature was also performed.

Received July 1, 1997; accepted after revision November 4.

From the Departments of Radiology (K.R.M., H.R.H., H.C.D.) and Otolaryngology-Head and Neck Surgery (C.S.), University of Utah School of Medicine and the Salt Lake Veterans Administration Medical Center, Salt Lake City, Utah.

Address reprint requests to H. Ric Harnsberger, MD, Department of Radiology, 50 N Medical Dr, Salt Lake City, UT 84132.

TABLE 1: Clinical and imaging findings in 23 patients with asymmetric fatty marrow or fluid-filled petrous air cells

Case	Age/ Sex	History	CT Findings	MR Findings*	Original Diagnosis	Final Diagnosis	Questioned Apex	Side of Pneumatization
1	30/F	"Fullness" right ear	Asymmetric fatty marrow	High/high	Atypical paraganglioma or small cholesterol granuloma	Asymmetric fatty marrow	Bilateral	Bilateral (asymmetric)
2	16/F	Nonspecific headache	Asymmetric fatty marrow	High/intermediate	Cholesterol granuloma	Asymmetric fatty marrow	Left	Right only
3	38/F	Focal oral hypesthesia and left-sided hearing loss	Asymmetric fatty marrow	High/low [†]	Asymmetric fatty marrow	Asymmetric fatty marrow	Left	Right only
4	62/F	Organic brain syndrome	None	High* (very high)/high* (very high)	Mucocele or cholesterol granuloma	Asymmetric fatty marrow	Left	Bilateral
5	13/M	Nonspecific headache	Asymmetric fatty marrow	High/intermediate	Cholesterol granuloma	Asymmetric fatty marrow	Left	Right only
6	60/F	Earache, nonspecific headache, and neck/jaw pain	None	High/intermediate	Unknown	Asymmetric fatty marrow	Left	Bilateral
7	34/M	Left SNHL	None	High/high	Unknown	Trapped fluid/blood products or small cholesterol granuloma	Right	Bilateral
8	25/F	Right V, VIII, and left VII cranial neuropathy	Nonexpansile opacified air cells	Low/high	Trapped proteinaceous fluid/protein	Trapped fluid	Left	Bilateral
9	59/F	Sudden onset left SNHL	None	Low* (intermediate)/high	Unknown	Trapped fluid	Left	Bilateral
10	23/F	Headache	Nonexpansile opacified air cells	Intermediate/high	Unknown	Trapped fluid	Left	Bilateral
11	55/M	Left SNHL, tinnitus, and "subtle" left V nerve palsy	Nonexpansile opacified air cells with trabecular thickening	Low* (high)/high	Cholesterol granuloma	Trapped fluid	Left	Bilateral
12	16/M	"Dizzy"	Nonexpansile opacified air cells	High/high	Cholesterol granuloma or hemorrhage	Trapped fluid	Left	Bilateral
13	64/F	Right ear tinnitus and vertigo; no history of ear infections	Nonexpansile opacified air cells	Intermediate* (high)/high	Cholesterol granuloma	Trapped fluid	Right	Bilateral
14	14/M	"Wandering eye"; history of ear infections as toddler	Nonexpansile "cyst" with trabecular thickening but some normal trabeculae present	Intermediate/high	Cholesteatoma	Trapped proteinaceous fluid or mucocele	Left	Bilateral
15	36/M	Nonspecific headache	Nonexpansile opacified air cells	Intermediate/high	Trapped fluid	Trapped proteinaceous fluid or early cholesterol granuloma	Right	Bilateral
16	44/M	Pontine infarct; no otologic symptoms	Nonexpansile opacified air cells	High/high	Trapped fluid	Trapped fluid	Right	Left only
17	34/F	"Weak and dizzy," headache	Nonexpansile opacified air cells	Low* (high)/high	Petrous apicitis	Trapped fluid	Left	Right only
18	33/F	Nonspecific dizziness	Nonexpansile opacified air cells	Intermediate/high	Cholesterol granuloma	Trapped fluid	Left	Bilateral
19	55/M	Nonspecific dizziness	Nonexpansile opacified air cells	Intermediate/high	Unknown	Trapped fluid	Right	Bilateral
20	15/M	Blackouts	Nonexpansile opacified air cells	Low/high	Petrous apicitis	Trapped fluid	Left	Bilateral
21	16/M	Nonspecific headache	None	High/high	Unknown	Trapped proteinaceous fluid or early cholesterol granuloma	Left	Bilateral
22	59/F	Bell's palsy	Nonexpansile opacified air cells	Intermediate/high	Trapped fluid	Trapped fluid	Right	Left only
23	53/M	Left ear pain	Nonexpansile opacified air cells	High/high	Mass lesion	Trapped fluid	Left	Bilateral

* All signal weightings were relative to neck muscle.

[†] Fat-saturation sequence.

[‡] Indicates a separate minor area of different signal intensity (mixed proteinaceous content).

Note.—SNHL = sensorineural hearing loss.

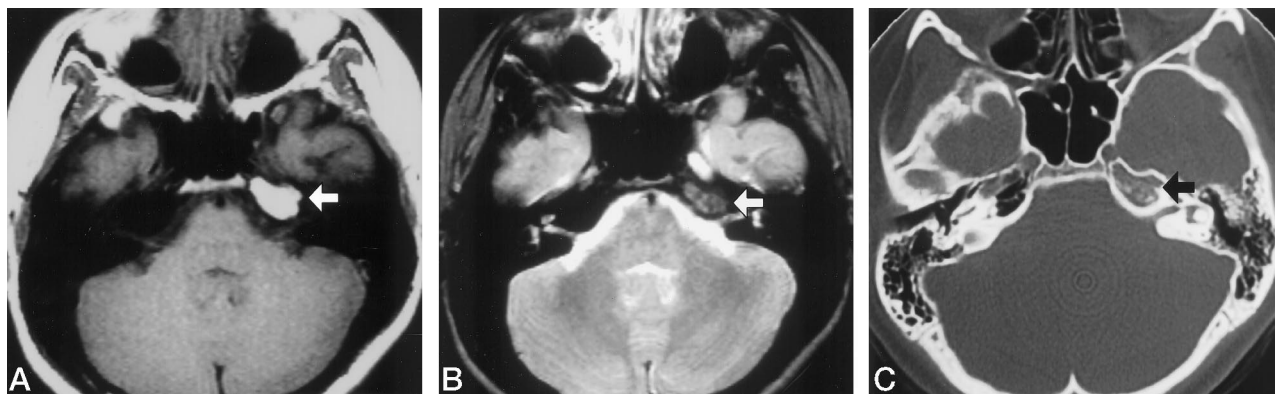


Fig 1. Asymmetric fatty marrow in a 16-year-old girl with nonspecific headaches (case 2).

A and B, MR images show high signal intensity on T1-weighted sequence (385/12/2) (A) and intermediate signal on T2-weighted sequence (2600/80/1) (B) in the left petrous apex (arrows) that follows signal intensity of orbital fat.

C, CT scan confirms a normal pneumatized right petrous apex and a nonexpansile, nonpneumatized left petrous apex with fatty marrow (arrow).

Equipment Specifications

MR imaging was performed on a GE Signa 1.5-T MR unit with standard T1-weighted (380–750/11–23 [TR/TE]) and T2-weighted (2200–4000/80–110) sequences; nine patients had an additional contrast-enhanced T1-weighted sequence. CT was performed with either a GE 9800 CT scanner or a GE HiSpeed Advantage helical scanner with wide window width (4000 HU) and level (350 HU) and a bone-only algorithm.

Definition of Terms

A petrous apex is considered pneumatized if it contains one or more air cells. A patient is considered to have asymmetric fatty marrow in the petrous apex if a marrow space is identified that follows the same signal characteristics as orbital fat on T1- and T2-weighted axial MR images. Also, high signal on T1-weighted images will give way to lower signal on T2-weighted images. A pneumatized petrous apex is considered to have trapped fluid (effusion) if it shows fluid signal on T2-weighted images and reveals nonexpansile, fluid-attenuation opacification of the air cells and preserved air-cell trabeculae on CT scans.

Results

Asymmetric Fatty Marrow

Six patients with asymmetric fatty marrow in the petrous apex were identified. Five patients (cases 2–6) had this fatty marrow collection on the left. One patient (case 1) had a small unilateral focus of fatty marrow within otherwise normally aerated petrous apices (Table 1).

MR signal intensity on the side of interest was high on the T1-weighted images and followed orbital fat signal on the T2-weighted images in all six cases. CT demonstrated a nonexpansile, nonaerated petrous apex with normal marrow space (Fig 1).

Trapped Fluid (Effusion)

Seventeen cases of unilateral opacified petrous apex air cells were identified with conventional brain

MR imaging (Table 1). MR signal intensity ranged from low to high signal on T1-weighted images and was of high signal on T2-weighted images. Two patients (cases 8 and 20) had homogeneous low signal on T1-weighted images and high signal on T2-weighted images (Fig 2). The other 15 patients all had multiple foci of differing signal intensity on T1-weighted images and high signal on T2-weighted images in the questioned petrous apex. Three patients (cases 9, 11, and 17) had predominately low signal on T1-weighted images with mixed foci of intermediate or high signal (Fig 3). Seven additional patients (cases 10, 13–15, 18, 19, and 22) had predominately intermediate signal on T1-weighted images; one patient (case 13) had a single focus of high signal intensity. Five patients (cases 7, 12, 16, 21, and 23) had predominately high signal intensity on the T1-weighted images (Fig 4).

Fourteen patients underwent additional high-resolution CT. No patient had expansion or destruction in the area of increased MR signal intensity. Two patients (cases 11 and 14) had trabecular thickening without expansion, thought to represent changes of chronic inflammation.

Comparison of Clinical History and Imaging Findings

Three patients (cases 1, 3, 6) with asymmetric fatty marrow and 11 patients (cases 7–9, 11–13, 17–19, 22, and 23) with a unilateral petrous apex effusion had neurootologic disorders, including cranial neuropathies, hearing loss, fullness in the ear, vertigo, and/or dizziness. The remaining nine patients had other complaints not referable to the skull base.

All three patients with asymmetric fatty marrow and neurootologic disorders had fatty marrow on the side of interest. Five of the 11 patients with unilateral effusions referred for imaging because of focal neurootologic signs and symptoms had apical air cell opacification on the side of the disorders. One patient (case 11) with neurootologic complaints and a non-

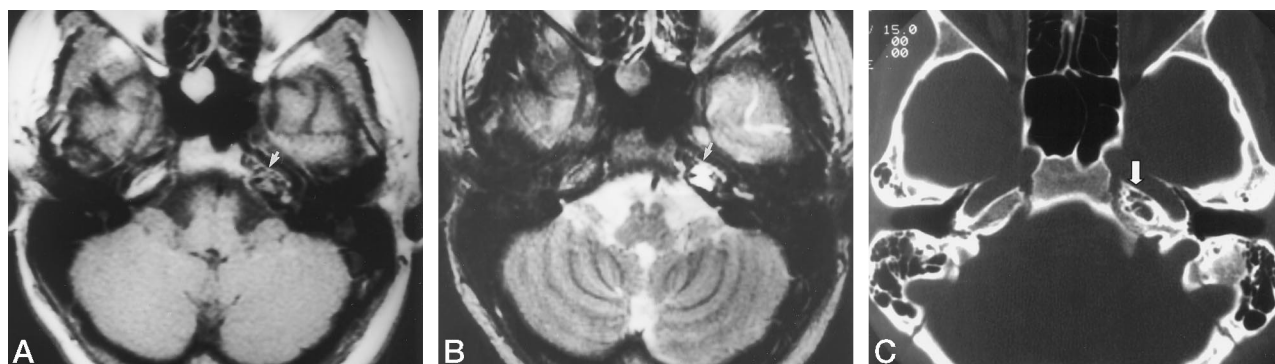


FIG 2. Trapped fluid in a 25-year-old woman with acute right V and VIII and left VII cranial neuropathies (case 8).

A and B, MR images show low signal intensity on T1-weighted sequence (750/11/1) (A) and high signal intensity on T2-weighted sequence (3900/110/1) (B) in the left petrous apex (arrows), consistent with uncomplicated fluid.

C, CT scan confirms nonexpansile fluid attenuation opacification of the pneumatized left petrous apex (arrow). The absence of expansile changes on CT in conjunction with the low signal intensity on T1-weighted images and high signal on T2-weighted images is highly suggestive of trapped fluid in the petrous apex air cells.

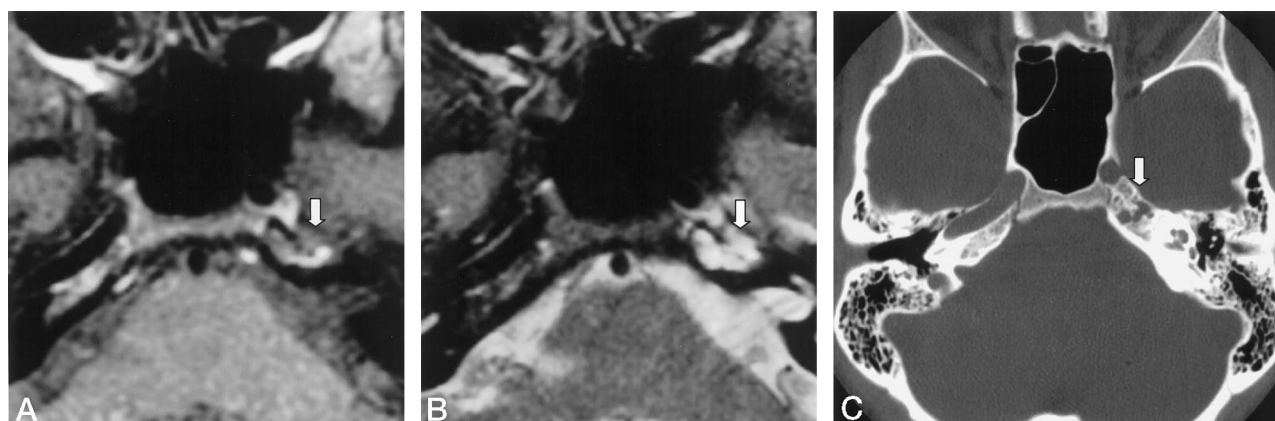


FIG 3. Trapped fluid in a 34-year-old woman with dizziness and headache (case 17).

A and B, MR images of the petrous apex show predominately low signal intensity mixed with foci of high signal intensity on T1-weighted sequence (400/23/2) (A) and high signal intensity on T2-weighted sequence (4000/95/4) (B) (arrows).

C, CT scan confirms nonexpansile fluid attenuation opacification of the pneumatized left petrous apex (arrow). The predominant low signal indicates fluid content. The foci of higher signal intensity are thought to reflect a proteinaceous component.

expansile area of intermediate T1 signal and high T2 signal on the side of the ailments underwent surgical exploration for a presumed cholesterol granuloma. At surgery, normal air cells were noted that contained sterile, slightly brown-tinged free-flowing proteinaceous fluid that was distinctly unlike the classic fluid (with a consistency like dark-chocolate crank-case oil) characteristic of cholesterol granulomas.

Discussion

Normal Anatomy and Pneumatization of the Petrous Apex

The petrous apex is anatomically defined as the portion of the temporal bone lying anteromedial to the inner ear, between the sphenoid bone anteriorly and the occipital bone posteriorly, with the extreme apex terminating at the foramen lacerum (3). Approximately 33% of people have pneumatized petrous apices (1, 2), of which 4% to 7% are asymmetrically pneumatized (1, 4). Temporal bone pneumati-

zation correlates poorly with age (2). In the adult, temporal bone pneumatization is divided into five general areas: middle ear, squamomastoid (mastoid), petrous apex, perilabyrinthine, and accessory air cells. The petrous apex is aerated by extensions from the supralabyrinthine, infralabyrinthine, and peritubal areas via the peritubal, posteromedial, and posterosuperior-subarcuate tracts. The degree of petrous apex pneumatization correlates nearly linearly with squamomastoid (mastoid) pneumatization (2).

Asymmetric Fatty Marrow in the Petrous Apex

Asymmetric fatty marrow in the petrous apex is usually noted as an incidental finding on conventional MR images (4–6) obtained for nonotologic complaints. It is the residual fatty marrow in the nonpneumatized or less pneumatized petrous apex that causes radiologic concern. Correct identification of this normal variant is essential to prevent misdiagnosis or unnecessary further workup or treatment.

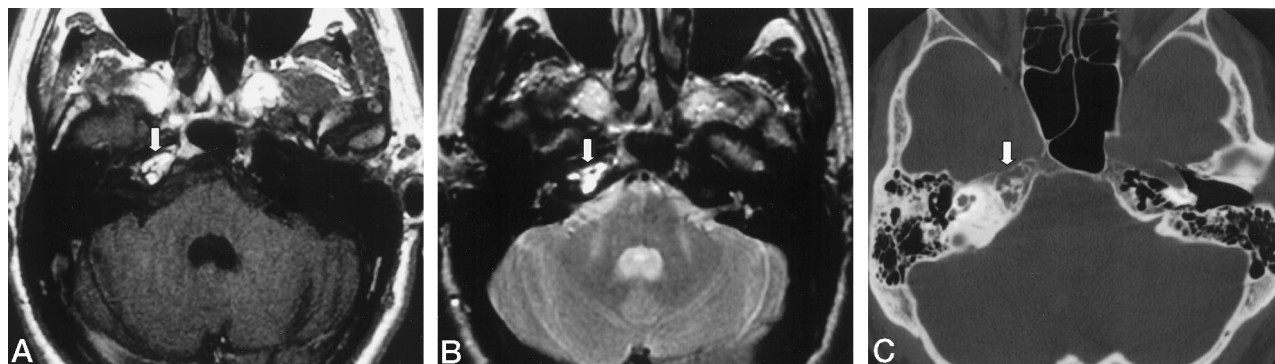


FIG 4. Trapped fluid in a 44-year-old man with pontine infarct (case 16).

A and B, MR images show high signal intensity in the right petrous apex on both T1-weighted (433/12/2) (A) and T2-weighted (2200/80/1) (B) sequences (arrows).

C, CT scan confirms nonexpansile fluid attenuation opacification of the pneumatized right petrous apex (arrow). If lack of expansion is not seen on MR studies, the signal characteristics would suggest the erroneous diagnosis of cholesterol granuloma.

TABLE 2: Imaging recommendations for findings in the petrous apex

Signal Intensity*		High-Resolution CT	Diagnosis	Suggested Imaging Evaluation
T1-Weighted MR Images	T2-Weighted MR Images			
High	Intermediate (spin-echo); high (fast spin-echo)	Asymmetric fatty marrow	Asymmetric fatty marrow	No further imaging
Low	High	Nonexpansile; fluid attenuation	Trapped fluid	No further imaging
Intermediate	High	Nonexpansile; fluid attenuation	Trapped fluid with high protein content	CT to exclude expansile lesion; follow-up CT in 3 years to exclude early cholesterol granuloma, or sooner if symptoms related to this area occur.
High	High	Nonexpansile; fluid attenuation	Trapped fluid with high protein content	CT to exclude expansile lesion; follow-up CT in 3 years to exclude early cholesterol granuloma, or sooner if symptoms related to this area occur

* Relative to neck muscle.

Asymmetric fatty marrow is characterized by high signal intensity on T1-weighted images and by intermediate to high signal intensity on fast spin-echo T2-weighted images. On T2-weighted images, the fatty marrow signal is somewhat lower on conventional spin-echo sequences than on fast spin-echo sequences. The decrease in signal intensity from T1- to T2-weighted images is useful for confirming the presence of fat with spin-echo imaging techniques. Regardless of the T2 imaging technique chosen, it is the recognition that the signal of the petrous apex fatty marrow follows orbital fat on all pulse sequences that makes correct identification straightforward. Fat-saturation or inversion-recovery sequences verify the impression of fatty marrow by fully suppressing its signal. If doubt remains, CT may be used to confirm the presence of normal fatty marrow in the questioned petrous apex. Once asymmetric marrow distribution in a normal nonaerated petrous apex is correctly identified, no further imaging evaluation or follow-up study is necessary.

Trapped Fluid (Effusion) in Petrous Apex Air Cells

Expansile lesions with high signal on both T1- and T2-weighted MR sequences are cholesterol granulomas. Since the advent of MR imaging, cholesterol granulomas have become the most commonly identified pathologic lesion of the petrous apex (7). In our experience, petrous apex effusions are most frequently misinterpreted as cholesterol granulomas when their nonaggressive appearance is not appreciated.

The origin of isolated fluid in petrous apex air cells is presumed to represent previous otitis media with subsequent obstruction of the connections between the middle ear and apical air cells. Brain MR images then show incidentally noted residual fluid in the petrous apex air cells in the asymptomatic adult. CT through this area reveals no evidence of trabecular disruption or expansion. Opacified air cells universally demonstrate high T2 signal, equivalent to adjacent CSF. However, trapped fluid may have low, intermediate, or high signal on T1-weighted images.

Recommendations for further examination of patients with trapped fluid are based on the T1-weighted MR signal characteristics and the CT appearance (Table 2).

Low T1 signal intensity is characteristic of uncomplicated petrous apex air-cell fluid and in our opinion does not require further imaging evaluation unless clinical symptoms are directly referable to this area. Patients with intermediate or high signal on T1-weighted images should be further examined with CT to confirm that there is neither loss of air-cell trabeculation nor expansile characteristics.

The appropriate imaging follow-up for these patients is less well defined. While most nonexpansile opacified air cells with intermediate or high signal on T1-weighted images probably represent proteinaceous trapped fluid, long-term imaging follow-up studies in these patients have not been performed. Additionally, since cholesterol granulomas are usually not diagnosed until they are symptomatic, the natural history and imaging findings of very early lesions are not known. Although we doubt that these lesions with intermediate to high signal on T1-weighted images represent a transitional group in the early developmental stages of a cholesterol granuloma, caution is prudent given the lack of imaging history of early cholesterol granuloma. Therefore, for lesions with intermediate or high T1 signal and no expansion, we recommend follow-up with high-resolution CT in 3 years to confirm stability.

Comparison of History and Imaging Findings

It is our experience that asymmetric fatty marrow or trapped fluid in the petrous apex is most commonly identified either by incidental discovery on an MR study obtained for unrelated clinical signs or symptoms or because of neurotologic disorders that could be referred to the side of the fatty marrow or trapped fluid. This incidental discovery of an unexpected MR finding can lead to uncertainty on the part of the referring clinician and/or radiologist. The neurotologic complaints reported include cranial neuropathies, hearing loss, vertigo, and dizziness. All three patients with asymmetric fatty marrow and five of the

11 patients with unilateral trapped fluid in this series who had neurotologic complaints had a questionable finding in the ipsilateral petrous apex. However, none had imaging findings that would explain their clinical symptoms.

Nine patients with one of these two entities were referred for surgical consultation for a presumed pathologic lesion. In five patients, the nonsurgical entities were correctly diagnosed at the time of initial imaging as incidental after a review of all MR sequences. The remaining nine patients were referred for a second opinion because of concern for a pathologic lesion. Careful inspection of all MR imaging sequences and the use of supplemental CT in difficult cases, in combination with focused review of the clinical findings with the referring physician, should produce the correct diagnosis in nearly all cases.

Conclusions

Lesions of the petrous apex are rare. The radiologist is heavily relied on to sort them into those that require treatment and those that can be ignored. The two major lesions of the petrous apex that do not require treatment are asymmetric fatty marrow and trapped fluid in the petrous apex air cells. Each has characteristic imaging features that allow them to be confidently diagnosed as 'leave-me-alone' lesions.

References

1. Myerson M, Rubin H, Gilbert J. **Anatomic studies of the petrous portion of the temporal bone.** *Arch Otolaryngol* 1934;20:192-210
2. Virapongse C, Sarwwar M, Bhimani S, Sasaki C, Shapiro R. **Computed tomography of temporal bone pneumatization, I: normal pattern and morphology.** *AJR Am J Roentgenol* 1985;145:473-481
3. Larson T. **Petrous apex and cavernous sinus: anatomy and pathology.** *Semin Ultrasound CT MR* 1993;14:232-246
4. Roland P, Meyerhoff W, Judge L, Mickey B. **Asymmetric pneumatization of the petrous apex.** *Arch Otolaryngol Head Neck Surg* 1990;103:80-88
5. Haynes R, Amy J. **Asymmetric temporal bone pneumatization: an MR imaging pitfall.** *AJNR Am J Neuroradiol* 1988;9:803
6. Curtin H, Som P. **The petrous apex.** *Otolaryngol Clin North Am* 1995;28:473-496
7. Greenberg J, Oot R, Wismer G, et al. **Cholesterol granuloma of the petrous apex: MR and CT evaluation.** *AJNR Am J Neuroradiol* 1988;9:1205-1214