

Are your **MRI contrast agents** cost-effective?

Learn more about generic **Gadolinium-Based Contrast Agents**.



**FRESENIUS
KABI**

caring for life

AJNR

Transcranial sonographic monitoring during thrombolytic therapy.

M Kaps and A Link

AJNR Am J Neuroradiol 1998, 19 (4) 758-760

<http://www.ajnr.org/content/19/4/758>

This information is current as
of April 20, 2024.

Transcranial Sonographic Monitoring during Thrombolytic Therapy

Manfred Kaps and Andreas Link

Summary: Two patients with acute occlusion of the middle cerebral artery (MCA) were treated with intravenous alteplase. Neurovascular monitoring, which was performed simultaneously via transcranial sonography, enabled precise documentation of MCA recanalization. This information was used to tailor the dosage and duration of alteplase treatment. Sonographic information concerning the arterial segments involved in the occlusive process, the actual hemodynamic status, and the collateral blood supply may help to identify those patients most likely to benefit from thrombolysis.

The effectiveness of thrombolytic therapy in the treatment of cerebral stroke was demonstrated in a study conducted by the National Institute of Neurological Disorders and Stroke (NINDS) when alteplase (rTPA) was given early, within 3 hours of stroke onset (1). However, in another investigation, carried out by the European Acute Stroke Study (ECASS), alteplase (1.1 mg/kg body weight) given intravenously within 6 hours of stroke onset improved neurologic outcome in a particular subgroup of patients but failed to prove efficacious when the study population was considered as a whole (2). The line demarcating the risks and benefits of thrombolytic therapy is therefore narrow and, in any case, remains to be established for alteplase treatment administered later than 3 hours after stroke onset.

Complete occlusion of the cervical internal carotid artery by in situ thrombosis appears to be more resistant to thrombolysis than do occlusions of the stem and major branches of the cerebral artery (3). Therefore, assessment of patients' potential to benefit from treatment in terms of their particular occlusion patterns should provide better information as to the applicability of thrombolysis.

The actual hemodynamic state is one of the principal determinants of the pathophysiological condition in patients with acute stroke, and is an early predictor of outcome. The specific methods used for neurovascular imaging depend on the equipment

available in any given institution. Although angiography, magnetic resonance (MR) angiography, perfusion, and spiral computed tomography (CT) have been widely recommended, neurosonologic methods have rarely been advocated (4). Transcranial Doppler sonography (TCD) has proved valuable for the assessment of a number of clinical conditions, such as cerebral vasospasm, middle cerebral artery (MCA) stenosis, occlusion, and arteriovenous malformations (5). A number of other potential uses are currently under investigation (6, 7). The advent of echogenic contrast agents will no doubt alleviate problems arising from sonographic attenuation by the skull, which is currently the most limiting factor for TCD diagnosis. Although TCD was recommended as an option in the ECASS trial (2), Doppler monitoring was performed in only 0.3% of the randomized patients (8).

We believe the case reports documented here establish the feasibility of hemodynamic monitoring, and we hope they will encourage the use of TCD in the monitoring of thrombolytic therapy.

Case Reports

Case 1

A 62-year-old man was admitted after experiencing a transient right-sided hemiparesis, which lasted approximately 15 minutes. Initial neurologic examination revealed no abnormalities. Three hours later, he suddenly suffered a severe left-sided hemiplegia with gaze deviation to the right and hemineglect with a National Institute of Health Stroke Scale score (9) of 14. Electrocardiography arterial fibrillation, suggesting cardiac embolism as the underlying mechanism for the stroke. The initial CT scan showed no sign of an early stroke; however, angiography, which was performed 90 minutes after stroke onset, revealed a main-stem occlusion of the MCA (Fig 1A).

In accordance with ECASS protocol (2), systemic thrombolysis was started immediately with a bolus of 9 mg of alteplase, after which continuous infusion was administered for a total dose of 1.1 mg/kg body weight (maximum, 90 mg) over 60 minutes. The patient was referred from the radiology department to an intensive care unit in order to monitor the ongoing thrombolysis noninvasively via transcranial color duplex sonography (TCCS) (2 MHz sector transducer; Sonos 2500, Hewlett-

Received December 19, 1996; accepted after revision May 29, 1997.

From the Department of Neurology, University at Luebeck (M.K.) and the Department of Neurology, Aatalklinik Wuenneberg (A.L.), Germany.

Address reprint requests to Prof Dr med M. Kaps, Department of Neurology, University at Luebeck, Ratzberger Allee 160, D-23538 Luebeck, Germany.

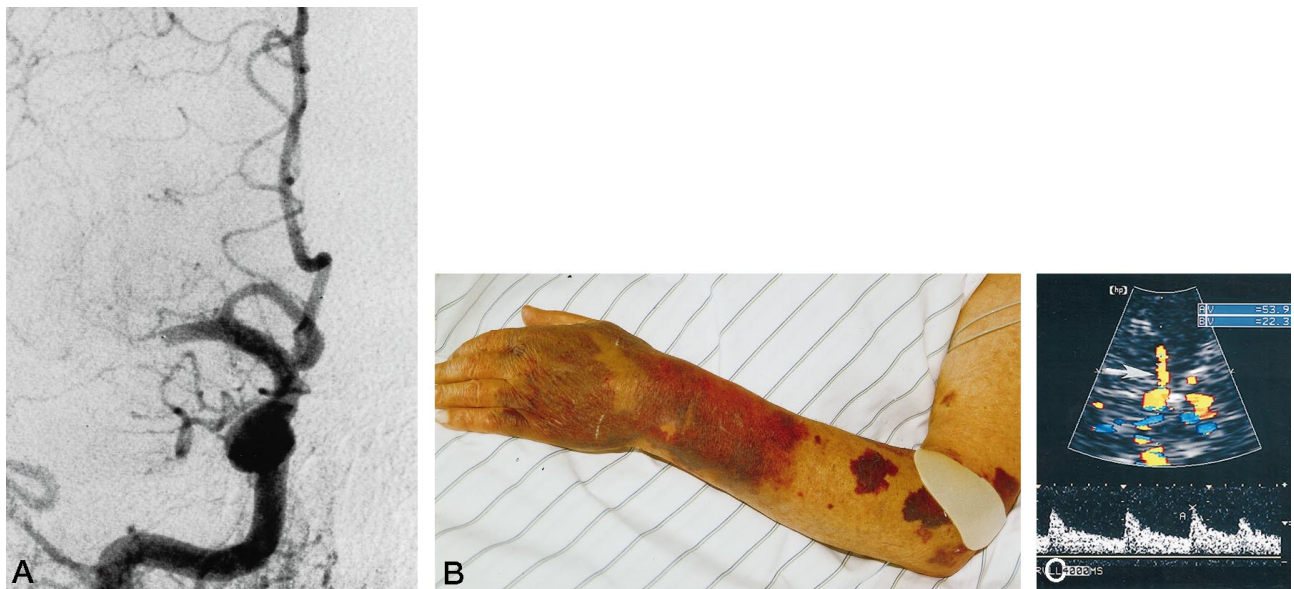

FIG 1. A, Angiogram shows occlusion of the right MCA main stem 90 minutes after stroke onset. B, Photograph shows subcutaneous ecchymosis during thrombolysis at a dose of 40 mg alteplase. C, Axial TCCS view shows the circle of Willis and recanalization of the MCA (arrow). Doppler spectrum obtained from the MCA segment shows no abnormalities (flow velocity: systole 54 m/s, diastole 22 m/s).

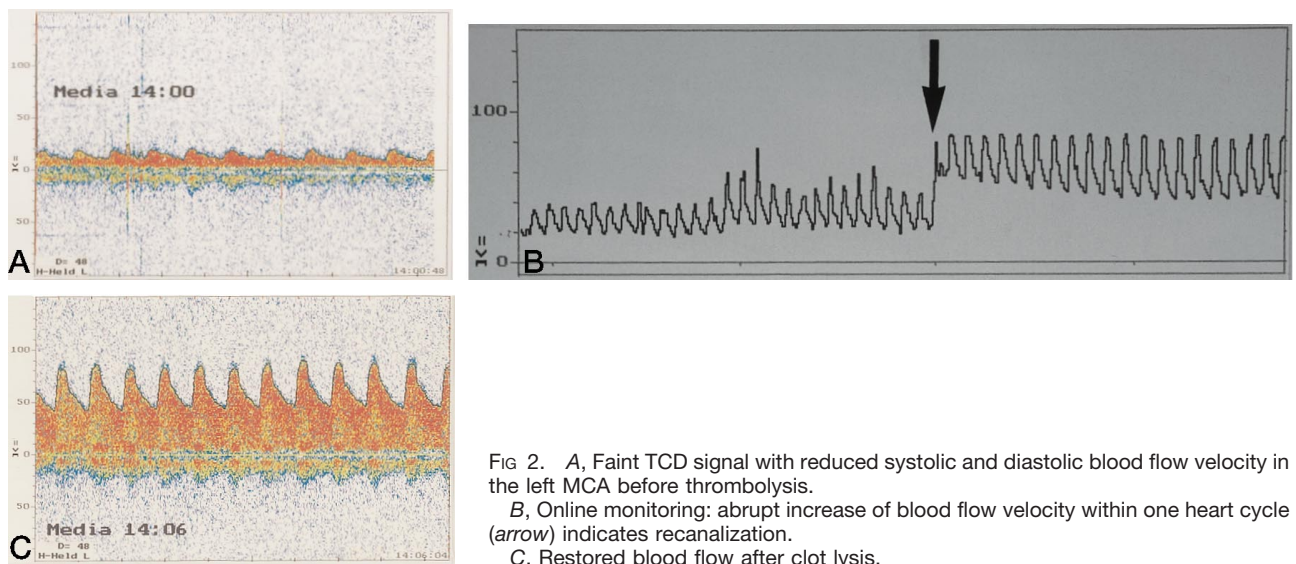


FIG 2. A, Faint TCD signal with reduced systolic and diastolic blood flow velocity in the left MCA before thrombolysis. B, Online monitoring: abrupt increase of blood flow velocity within one heart cycle (arrow) indicates recanalization. C, Restored blood flow after clot lysis.

Packard, Andover, Mass). After a total dose of 40 mg of intravenous alteplase was administered, ecchymosis occurred at the upper extremities (Fig 1B) and blood extravasated out of the urethral catheter and stomach tube. At that time, TCCS showed no sign of hemorrhage in the brain parenchyma.

Recanalization of the MCA was observable by TCCS after a total dose of 50 mg alteplase (Fig 1C). The Doppler velocity spectrum revealed normal hemodynamics in the recanalized MCA; posts ischemic hyperperfusion did not occur. It was therefore possible to finish thrombolysis 30 minutes earlier than had initially been calculated; that is, when an accumulated dose of only 50 mg (instead of 90 mg) alteplase had been given. Recovery from hemiplegia ensued within a few minutes after the cessation of alteplase treatment.

The only persistent neurologic deficit was a mild paresis of the left arm with hyperactive tendon reflexes, which produced a score of 55 on the Scandinavian Stroke Scale (10). A CT scan showed no sign of hemorrhage. As a result of the extracerebral bleeding, low-dose heparin was administered for 2 days, and

appropriate anticoagulation was initiated thereafter to ensure secondary prevention of arterial fibrillation.

Case 2

A 56-year-old man suffered an acute right-sided hemiparesis and sensorimotor aphasia (NIHSS score of 9). Doppler examination 3 hours after stroke onset revealed a severe stenosis (classified as 81% to 90% by Steinke et al [11]) at the origin of the left internal carotid artery. Peak and diastolic blood flow velocity in the left MCA main stem were markedly reduced (Fig 2A), indicating hemodynamic blockage in the MCA vascular territory.

Left anterior cerebral artery flow was in the antegrade direction. The contralateral A1 segment and anterior communicating artery contributed via crossflow to the augmented blood flow velocity in the left anterior cerebral artery. Angiography confirmed almost complete distal occlusion of the MCA, in

which only one insular branch was spared. CT 2 hours after stroke onset showed no significant anomalous findings.

Thrombolytic therapy was established intravenously while TCD monitoring was enacted (2 MHz PW Doppler device TC 2000S; EME Überlingen, Germany) with a bolus of 10 mg alteplase followed by delivery of 90 mg as a constant infusion over a period of 120 minutes. After application of 90 mg alteplase, a sudden increase in MCA blood flow velocity indicated dissolution of the clot (Fig 2B and C). Normalization of left MCA perfusion was paralleled by a decrease in blood flow velocity in the contralateral A1 segment. Clinically, the patient made a good recovery, and a neurologic examination 3 weeks later revealed only slight weakness of the right arm without aphasia (Scandinavian Stroke Scale score of 54). A CT scan showed a small infarction of the basal ganglia in the territory of the lenticulostriate arteries.

Discussion

Whether it is necessary to prove artery occlusion before instituting thrombolytic therapy in the carotid territory remains a subject of discussion. Opinions range from "no need," since even minor strokes benefit from alteplase therapy, to more differentiated approaches, in which the presence and site of artery occlusion are considered. To widen the gap between the risks and benefits of thrombolytic therapy, simple and rapidly available tests have been suggested (12), by which patients with carotid occlusions or no occlusions at all could be excluded from consideration.

Sonography allows a rapid and reliable analysis of hemodynamic status even in drowsy patients who are unable to cooperate. Diagnosis is possible for internal carotid artery occlusion, distal carotid T-occlusion, MCA stenosis, and MCA occlusion (13, 14). It is particularly effective for the immediate identification of stroke patients who have an unobstructed MCA (approximately 41%) (15) and normal hemodynamics.

Because the individual dose of alteplase needed for recanalization cannot be predicted, sonography offers the possibility of tailoring the thrombolytic procedure. Only 56% of the precalculated alteplase dose was needed to recanalize the MCA in our first patient, in whom infusion was maintained for only half the time as that calculated and deemed necessary at the beginning of treatment. The limited dosage had clearly positive safety implications, since extracranial bleeding complications had already developed. Intracranial hemorrhage, which can also be monitored by TCCS (16), was not observed.

Clot dissolution in the second study took place abruptly, within one heart cycle, and hyperperfusion was not observed. Patients with delayed or deferred recanalization and postischemic hyperperfusion have been reported elsewhere (13). Sonographic monitoring offers the unique opportunity to study the interactions among

dissolution, postischemic hyperperfusion, reperfusion injury, and hemorrhagic complications, which are poorly understood to date. Early collateral blood supply has been proposed as a factor that may predict good clinical outcome (17). Collateral activation along the ipsilateral anterior and posterior cerebral artery before thrombolysis together with normalization thereafter was shown in our second patient.

The significance of our findings in terms of prognosis remains to be determined in larger clinical studies. As with all investigative procedures, the true benefit of TCD in thrombolysis will be defined by its clinical context.

References

1. The National Institute of Neurological Disorders and the Stroke r-TPA Stroke Study Group. **Tissue plasminogen activator for acute ischemic stroke.** *N Engl J Med* 1995;333:1581-1587
2. The ECASS Study Group. **Intravenous thrombolysis with recombinant tissue plasminogen activator for acute hemispheric stroke: the European Acute Stroke Study.** *JAMA* 1995;274:1017-1025
3. Del Zoppo GJ. **Thrombolysis in acute stroke.** *Neurologia* 1995; 10(Suppl 2):37-47
4. Gass S, Ries F, Urbach H, Solymosi L. **Transcranial Doppler sonography monitoring of intra-arterial thrombolysis in acute occlusions of the middle cerebral artery.** *J Neurol* 1996;243(Suppl 2):5
5. Report of the American Academy of Neurology. **Assessment: transcranial Doppler.** *Neurology* 1990;40:690-681
6. Wechsler LR, Babikian VL. **Transcranial Doppler sonography.** *Arch Neurol* 1994;51:1054-1056
7. Baumgarten RW, Mattle HP, Aaslid R, Kaps M. **Transcranial color-coded duplex sonography in arterial cerebrovascular disease.** *Cerebrovasc Dis* 1996;495:2-11
8. Steinke W. **Utility of TCD in thrombolysis.** Presented at the annual meeting of the Neurosonology Research Group of the World Federation of Neurology, Salzburg, Austria, September 1995
9. Brott T, Adams HP, Olinger CP. **Measurements of acute cerebral infarction: a clinical examination scale.** *Stroke* 1989;20:864-870
10. Scandinavian Stroke Study Group. **Multicenter trial: hemodilution in ischemic stroke.** *Stroke* 1985;16:885-890
11. Steinke W, Kloetsch C, Hennerici M. **Carotid artery disease assessed by color flow imaging: correlation with standard Doppler sonography and angiography.** *AJNR Am J Neuroradiol* 1990;11: 259-266
12. Baron JC, von Kummer R, del Zoppo GJ. **Treatment of acute ischemic stroke: challenging the concept of a rigid and universal time window.** *Stroke* 1995;26:2219-2221
13. Kaps M, Teschendorf U, Dorndorf W. **Hemodynamic studies in early stroke.** *J Neurol* 1992;239:138-142
14. Seidel G, Kaps M, Gerriets T. **Potential and limitations of transcranial color coded sonography in stroke patients.** *Stroke* 1995;26: 2061-2066
15. The EMS Bridging Trial Investigators. **Combined intravenous and intra-arterial thrombolysis versus intra-arterial thrombolysis alone: preliminary safety and clot lysis.** *Cerebrovasc Dis* 1996;6: 175-194
16. Kaps M, Seidel G, Gerriets T, Traupe H. **Transcranial Duplex monitoring discloses hemorrhagic complications following r-TPA thrombolysis.** *Acta Neurol Scand* 1996;93:61-63
17. von Kummer R, Forsting M. **Effects of recanalization and collateral blood supply on infarct extent and brain edema after middle cerebral artery occlusion.** *Cerebrovasc Dis* 1993;3:252-255