

Are your **MRI contrast agents** cost-effective?

Learn more about generic **Gadolinium-Based Contrast Agents**.



**FRESENIUS
KABI**

caring for life

AJNR

MR of spinal cord ganglioglioma.

U Patel, R S Pinto, D C Miller, M S Handler, L B Rorke, F J
Epstein and I I Kricheff

AJNR Am J Neuroradiol 1998, 19 (5) 879-887

<http://www.ajnr.org/content/19/5/879>

This information is current as
of April 17, 2024.

MR of Spinal Cord Ganglioglioma

Uresh Patel, Richard S. Pinto, Douglas C. Miller, Michael S. Handler, Lucy B. Rorke, Fred J. Epstein, and Irvin I. Kricheff

PURPOSE: Our purpose was to describe the MR imaging features in a series of spinal intramedullary gangliogliomas and to compare these findings with the MR features of intramedullary astrocytomas and ependymomas.

METHODS: A retrospective analysis was performed of 76 MR examinations in 27 patients with histologically proved spinal ganglioglioma; these were then compared with imaging findings in a representative sample of histologically proved spinal cord astrocytomas and ependymomas.

RESULTS: Statistically significant observations regarding spinal gangliogliomas included young age of the patients (mean, 12 years), long tumor length, presence of tumoral cyst, presence of bone erosion and scoliosis, absence of edema, presence of mixed signal intensity on T1-weighted images, and presence of patchy enhancement and cord surface enhancement. A trend (not statistically significant) was noted for holocord involvement and lack of magnetic susceptibility.

CONCLUSION: Spinal ganglioglioma can be strongly suspected if MR images reflect the above criteria; however, the ultimate diagnosis still depends on radical resection and appropriate histopathologic investigation.

Gangliogliomas are relatively rare primary tumors of the CNS. They are composed of a mixture of neoplastic mature neuronal elements (ganglion cells) and neoplastic glial elements, primarily astrocytic. Gangliogliomas are said to account for 0.4% to 3.8% of all primary brain tumors (1–3); however, they are more common in children, among whom gangliogliomas may account for as much as 10.7% of primary CNS neoplasms (3). They have probably been underdiagnosed, since until recently, the identification of neoplastic neuronal elements depended on uncertain methods. Recent advances in immunohistochemistry allow for greater confidence in diagnosis (4–9).

While these tumors may occur anywhere in the neuraxis, the most common sites are said to be the temporal lobes and cerebellum (10). Some authors have stated that the spinal cord is the least affected site in the CNS, with only 1.1% of all spinal neoplasms being gangliogliomas (11). To date, only 46

spinal cord gangliogliomas have been reported (1, 3, 12–23), the largest group from NYU Medical Center (3, 22, 23) (these were not been counted more than once, although some were included in more than one publication). MR features have been reported for only four examples (18–20).

Spinal cord gangliogliomas, like those in the cerebrum, have been reported to have a low malignant potential (3) and a relatively good prognosis (3, 22, 23), albeit with a substantial frequency of local recurrence. We have advocated gross total resection without adjunctive therapy as the treatment of choice (3, 22, 23), similar to our practice with other low-grade spinal cord intramedullary neoplasms (24–27). In contrast, high-grade neuroglial tumors of the cord do not appear to benefit from radical resection (27, 28); it is therefore important that preoperative MR studies allow recognition of ganglioglioma. The utility of MR imaging in the evaluation of neoplasms of the spinal cord is well established (29–46). This study presents MR imaging features of 27 pathologically proved intramedullary spinal cord gangliogliomas and compares them with MR features of representative sets of astrocytomas and ependymomas of the cord.

Methods

Case Selection

The case files of the division of neuropathology at our institutions were reviewed for all patients in whom ganglioglioma of the spinal cord was diagnosed during the period from January 1977 to December 1994. We also included all tumors reclassified as ganglioglioma after retrospective review (3, 22, 23). Our search produced a total of 78 patients with histolog-

Received August 19, 1997; accepted after revision December 9. Presented at the annual meeting of the American Society of Neuroradiology, Chicago, April 1995.

From the Department of Radiology (U.P., R.S.P., I.I.K.), the Division of Pediatric Neurosurgery (D.C.M., M.S.H., F.J.E.), the Division of Neuropathology (D.C.M., M.S.H.), and the Kaplan Cancer Center (D.C.M., F.J.E., I.I.K.), New York University Medical Center; and the Department of Pathology, Children's Hospital of Philadelphia (L.B.R.).

Address reprint requests to Uresh Patel, MD, Department of Radiology, P.O. Box 648, University of Rochester Medical Center Strong Memorial Hospital, 601 Elmwood Ave, Rochester, NY 14642.

FIG 1. 21-year-old man with holocord ganglioglioma.

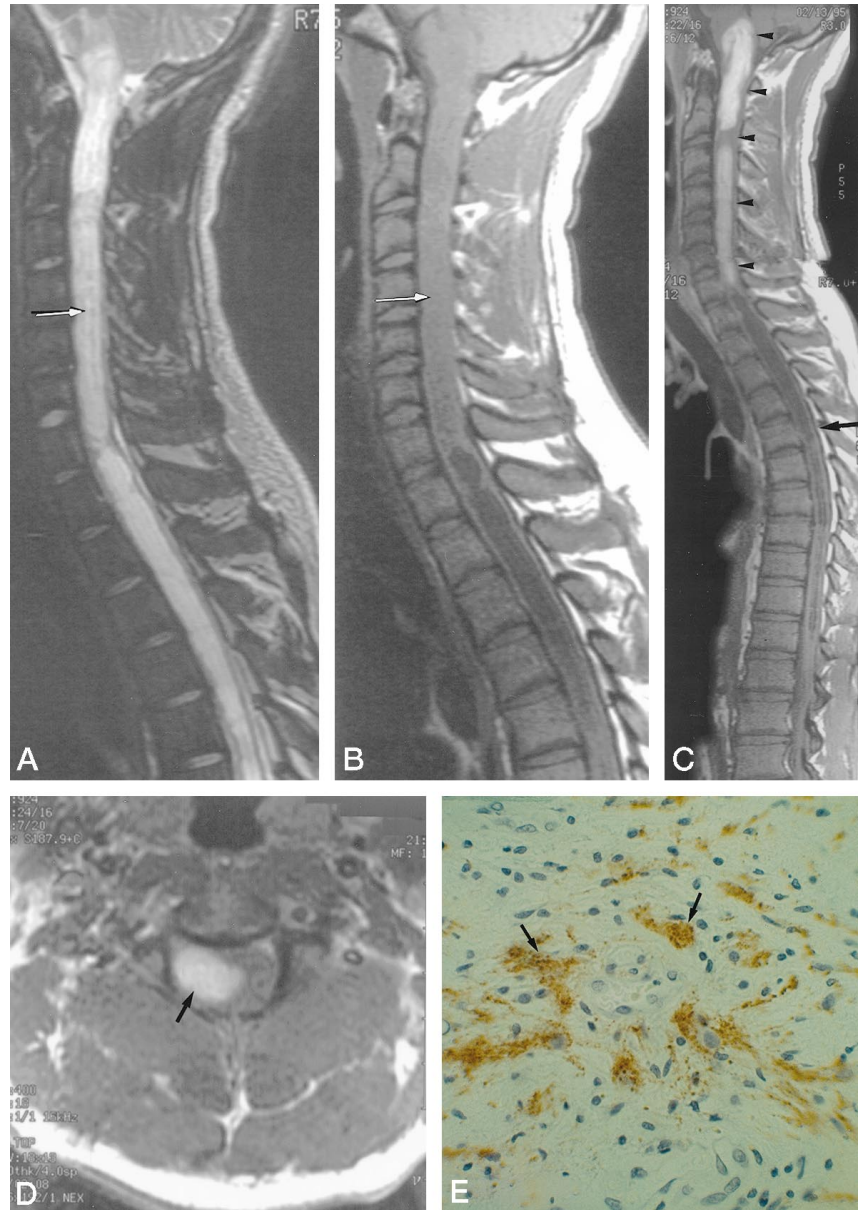
A, Midsagittal fast spin-echo T2-weighted (4000/118/2) image of the cervical and upper thoracic spine shows an intramedullary tumor with a solid rostral and cystic caudal component. The signal intensity is homogeneous (arrow).

B, Corresponding sagittal spin-echo T1-weighted (500/15/2) image shows the solid rostral component of the tumor to be hypointense (arrow) relative to normal neural tissue within the cerebellum.

C, Composite midsagittal contrast-enhanced spin-echo T1-weighted (500/15/2) image of the entire spine shows tumor extending from the medulla to the conus. The solid rostral component enhances in a patchy fashion with enhancing and nonenhancing areas (arrowheads). The caudal cyst does not enhance (arrow), indicating that it is reactive.

D, Axial contrast-enhanced spin-echo T1-weighted (400/18/1) image at the C-4 level shows eccentric enhancement of the tumor, which extends to the cord surface in a tongue-like fashion.

E, Immunohistopathologic micrograph shows decoration of ganglion cells with synaptophysin (arrows).



ically proved spinal cord gangliogliomas (see Pathology section below for diagnostic criteria). These cases were then cross-referenced with the files of the department of radiology, resulting in 76 MR examinations available in 27 patients. Included in this group were 15 patients who were imaged before surgery and 12 patients who underwent a small diagnostic spinal biopsy before imaging. Contrast-enhanced images were available in 59 of the 76 examinations and in 26 of the 27 patients. Thirteen of these patients were included in a previous clinicopathologic analysis of spinal cord ganglioglioma (3, 22).

These examinations were compared with the MR images obtained in a representative set of 15 patients with histologically proved spinal cord astrocytoma. Additionally, the MR data set of 25 intramedullary ependymomas, previously reported (47, 48), were compared with these other tumors.

Pathology: Diagnostic Criteria

Diagnosis of ganglioglioma is contingent on having adequate tissue volume for histopathologic examination. The bias toward radical resection of intramedullary cord tumors at our institution provided generous specimens for pathologic analysis (3).

Ganglioglioma may be suspected when an otherwise astrocytic neoplasm contains a component of large cells potentially representing neurons. These often, but not invariably (3, 49), display atypical or dysplastic features, such as binucleation, calcification, background desmoplasia, intense perivascular lymphoplasmacytic infiltration, and Rosenthal fibers or (more often) eosinophilic granular bodies (3, 5–8, 11, 23, 49). The use of immunohistochemical stains for synaptophysin dramatizes the presence of abnormal neurons, which display coarsely granular surface staining of the neoplastic neuronal perikarya in a pattern not seen in normal neurons, with limited exceptions (3–8, 49–51) (Fig 1E).

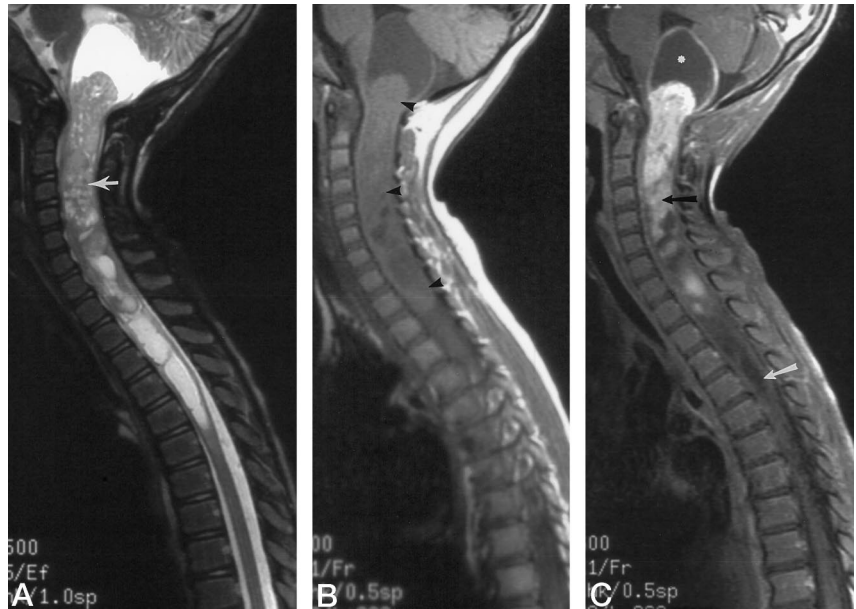For this study, as well as for a larger comprehensive pediatric intramedullary spinal cord tumor study (52), all slides from the spinal cord tumors were reviewed by two neuropathologists, who reviewed the cases independently without knowledge of the other's interpretations. The diagnostic lists were compared, and whenever the diagnoses differed, the slides were reexamined in concert at a double-headed microscope (23). In addition to examination with the usual hematoxylin-eosin stains, all lesions suspected by either pathologist of being ganglioglioma were examined with immunohistochemical

FIG 2. 5-year-old girl with cervical ganglioglioma.

A, Midsagittal fast spin-echo T2-weighted (4500/95/2) image of the cervical and upper thoracic spine shows a solid intramedullary cervical tumor. The signal intensity is heterogeneous (arrow). Rostral, caudal, and intratumoral cysts are present. Note posterior scalloping of vertebral bodies.

B, Corresponding sagittal spin-echo T1-weighted (600/11/2) image shows the solid portion of the tumor to have mixed signal intensity (arrowheads).

C, Corresponding sagittal contrast-enhanced spin-echo T1-weighted (600/11/2) image shows patchy enhancement of the tumor (black arrow). The enhancing walls of the rostral cyst (asterisk) indicate a tumoral cyst. The caudal cyst (white arrow) does not enhance, suggesting that it is reactive.



stains for glial fibrillary acidic protein (GFAP), synaptophysin, and vimentin; these examinations were performed with standard methods as described previously (3, 4). At the completion of these studies, a consensual diagnosis was reached for all tumors included in the study.

MR Analysis

All MR images were analyzed by two neuroradiologists in consensual fashion. Note was made of the patient's age and sex, the size and location of the tumor, its centricity or eccentricity with reference to the axis of the cord, presence of reactive or tumoral cysts, presence of scoliosis or bone erosion, T1- and T2-weighted signal characteristics, contrast enhancement characteristics, presence of edema in the uninvolved portion of the cord, and presence of any magnetic susceptibility.

Tumor size was measured in terms of the number of vertebral body segments it spanned. Tumor location was described as cervical, thoracic, filar, or, if the entire cord was involved, holocord, using bony (vertebral) landmarks. If a tumor crossed two zones, its location was recorded as that where its greatest bulk existed. Centricity/eccentricity was defined by using the criteria of Fine et al (48), so that a lesion was considered central if no more than 60% of its cross-sectional area was located to one side of the midline on axial images.

Tumoral cysts were characterized as those with walls showing contrast enhancement or as those containing an enhancing nodule; reactive cysts had walls that were nonenhancing and not associated with enhancing nodules (32, 48). T1 and T2 signal intensity was characterized relative to normal neural tissue. T1 signal was described as hypointense, isointense, hyperintense, or mixed. As neoplastic tissue invariably shows T2 prolongation, signal intensity on T2-weighted images was described as homogeneous (uniform) or heterogeneous (mixed). All pulse sequences were assessed for the presence of edema. Areas of homogeneously increased signal on T2-weighted images within the cord that did not enhance and did not have the signal characteristics or morphologic appearance of a cyst were presumed to represent edema (47, 48). We accept the possibility that nonenhancing tumor may have a similar appearance. The T2 and T2' gradient-echo images were assessed for tumoral or peritumoral magnetic susceptibility. Both the presence and character of contrast enhancement were characterized. Enhancement was analyzed in terms of four broad descriptors: focal, diffuse, patchy, and cord surface extension.

Focal enhancement refers to well-defined nodular enhancement of a portion of the tumor. Diffuse enhancement refers to enhancement of the entire tumor. Patchy enhancement refers to mixed areas of enhancing and nonenhancing tissue. Cord surface extension refers to extension of the area of enhancement to the surface of the cord (Figs 1–3).

Results

The results are summarized in Tables 1 and 2. The mean age of patients with spinal cord ganglioglioma was 12 years. The mean age for patients with spinal cord astrocytoma and ependymoma was 4 years and 38 years, respectively. This was statistically significant (two-tailed *t*-test, $P < .001$). No statistical difference was found in the sex distribution between tumor types.

Tumor Size

We found a statistically significant difference ($P < .0001$) between length of spinal cord ganglioglioma and that of the other tumor types. Spinal gangliogliomas had an average length of eight vertebral body segments, whereas both spinal cord astrocytomas and spinal cord ependymomas had an average length of four vertebral body segments (Table 1).

Tumor Location

Like spinal astrocytomas and spinal ependymomas, the majority of spinal gangliogliomas (48%) were located within the cervical cord (Table 1). Although holocord involvement was only present in the ganglioglioma subgroup (Fig 1), occurring in 15% of cases, this difference was not statistically significant (Table 1).

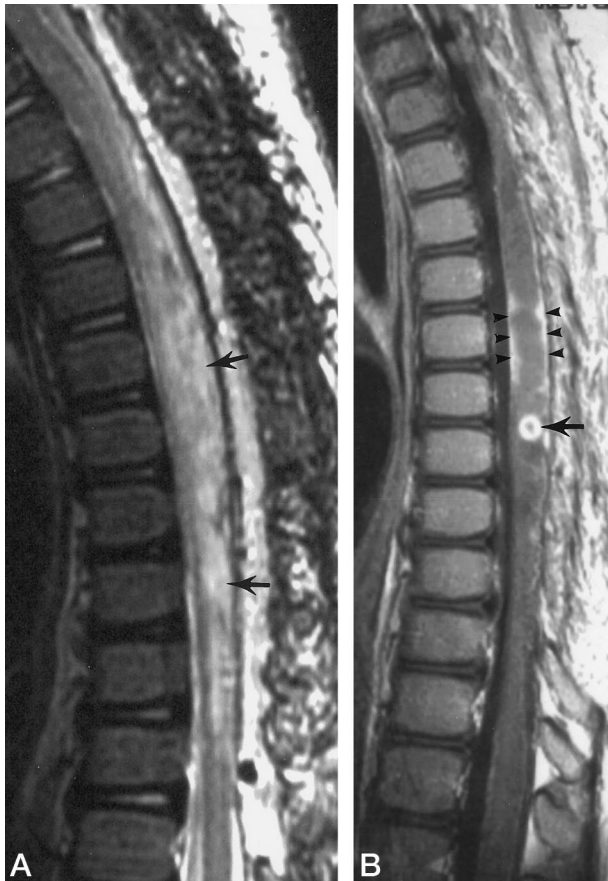


FIG 3. 5-year-old girl with thoracic ganglioglioma, who had partial resection of the spinal cord tumor before imaging. Note the multilevel thoracic laminectomies.

A, Midsagittal fast spin-echo T2-weighted (3000/105/3) image of the thoracic spine shows an expansile tumor of the midthoracic cord. The signal intensity is heterogeneous (arrows).

B, Corresponding sagittal contrast-enhanced spin-echo T1-weighted (500/90/3) image shows focal (arrow) and cord surface (arrowheads) enhancement.

Tumor Centricity

In all cases of spinal ganglioglioma and spinal astrocytoma, the tumor was eccentrically located within the spinal cord.

Cysts

Tumoral cysts were seen with a greater frequency in spinal gangliogliomas than in spinal astrocytomas or ependymomas, occurring in 46% of cases of spinal gangliogliomas as compared with 20% of spinal astrocytomas and 3% of spinal ependymomas (Figs 1 and 2).

A significant difference ($P < .001$) was noted between spinal ganglioglioma and spinal ependymoma in the frequency with which they contained tumoral cysts. However, no statistical difference was found in the frequency with which cysts occurred in spinal ganglioglioma and spinal astrocytoma.

Although reactive cysts were found to have a higher rate of frequency in spinal ependymomas, occurring in 78% of cases, there was no significant difference

TABLE 1: Comparison of tumor size, location, centricity, cyst type, and bony changes

	Ganglioglioma	Astrocytoma	Ependymoma
Tumor size, mean number (range) of vertebral segments	8 (2-18)*	4 (1-13)*	4 (1-8)*
Tumor location	n = 27	n = 15	n = 25
Cervical	48%	53%	56%
Thoracic	22%	40%	28%
Filar	15%	7%	16%
Holocord	15%	0	0
Tumor centricity	n = 27	n = 15	n = 25
0	0	0	76%
Cyst	n = 26	n = 15	n = 23
Tumoral cyst	46%†	20%	3%†
Reactive cyst	61%	40%	78%
Bone Changes	n = 27	n = 15	n = 25
Scoliosis	44%†	7%†	...
Bone erosion	93%†	40%†	...

* P value $< .0001$ by two-tailed t -test.

† P value $< .001$ by χ^2 -test.

between the various tumor subtypes. The length of reactive cysts was analyzed in the subgroup of spinal gangliogliomas and spinal astrocytomas. In those tumors that had reactive cysts, the average cyst length was 4.3 vertebral body segments for spinal gangliogliomas and 4.0 segments for spinal astrocytoma. Thus, again, there was no appreciable difference.

Bone Changes

Scoliosis and bone erosion/scalloping were significantly more common with spinal ganglioglioma than with spinal astrocytoma ($P < .0001$) (Table 1 and Figs 2 and 4). Bone changes were not analyzed in the ependymoma subgroup, as they are unusual in our experience.

Signal Characteristics

Unenhanced T1-weighted images were available in 18 of the 27 patients with spinal gangliogliomas, in 11 of the 15 patients with spinal astrocytomas, and in all 25 of the patients with spinal ependymomas (Table 2). Only one (5%) of 18 spinal gangliogliomas was hypointense relative to normal neural tissue (Fig 1), as opposed to 82% of spinal astrocytomas. None of the spinal gangliogliomas was isointense, as compared with 72% of the spinal ependymomas. The overwhelming majority of gangliogliomas (84%) had mixed signal intensity (Fig 2), a phenomenon not seen in the other tumor types. These findings were statistically significant ($P < .0001$).

T2-weighted images were available in 15 of the 27 cases of spinal ganglioglioma, in 15 of 15 cases of spinal astrocytoma, and in 23 of the 25 cases of spinal ependymomas (Table 2). Sixty percent of the spinal gangliogliomas showed homogeneous signal on T2-weighted images (Fig 1). Forty percent of cases showed heterogeneous signal on T2-weighted images (Figs 2 and 3). As regards T2 signal characteristics, no

TABLE 2: Comparison of MR imaging characteristics

	Ganglioglioma	Astrocytoma	Ependymoma
T1-weighted appearance	n = 18	n = 11	n = 25
Hypointense	5%	82%*	16%
Isointense	0	9%	72%*
Hyperintense	11%	9%	12%
Mixed	84%*	0	0
T2-weighted appearance	n = 15	n = 10	n = 25
Homogeneous	60%	60%	80%
Heterogeneous	40%	40%	20%
Contrast enhancement	n = 26	n = 15	n = 23
Focal	19%	0	65%
Diffuse	4%	79%*	35%
Patchy	65%*	7%	0
Cord surface	58%*	7%	0
None	15%	7%	0
Other	n = 15	n = 10	n = 25
Edema	7%	30%*	92%*
Magnetic susceptibility	7%	20%	20%

* P value < .001 by χ^2 -test.

difference was found between spinal ganglioglioma and spinal astrocytoma, and no significant difference was found with spinal ependymoma. Spinal ganglioglioma was accompanied by edema and magnetic susceptibility in only one case each, whereas both these features were seen with ascending order of frequency in spinal astrocytoma and spinal ependymoma (Table 2). The relative absence of edema within the spinal ganglioglioma subgroup was statistically significant ($P < .0001$).

Contrast Enhancement Characteristics

Contrast-enhanced T1-weighted images were available in 26 of 27 cases of spinal ganglioglioma, in 15 of 15 cases of spinal astrocytoma, and in 23 of 25 cases of spinal ependymoma (Table 2).

Focal enhancement was identified more frequently in the spinal ependymoma group, in which 65% demonstrated focal enhancement as compared with 19% of spinal gangliogliomas (Fig 3). Diffuse enhancement was noted more frequently in the spinal astrocytoma group. Seventy-nine percent of spinal astrocytomas showed diffuse enhancement, while only one spinal ganglioglioma in our series showed diffuse enhancement. Patchy enhancement was seen in 65% of spinal gangliogliomas (Figs 1 and 2). Enhancement reaching the surface of the cord was seen in 58% of cases of spinal ganglioglioma (Figs 1 and 3). Both these types of enhancement were present only in the ganglioglioma subgroup without exception (Table 1). These figures were statistically significant ($P < .001$). Finally, 15% of spinal gangliogliomas showed no type of contrast enhancement (Fig 4); this was not statistically significant.

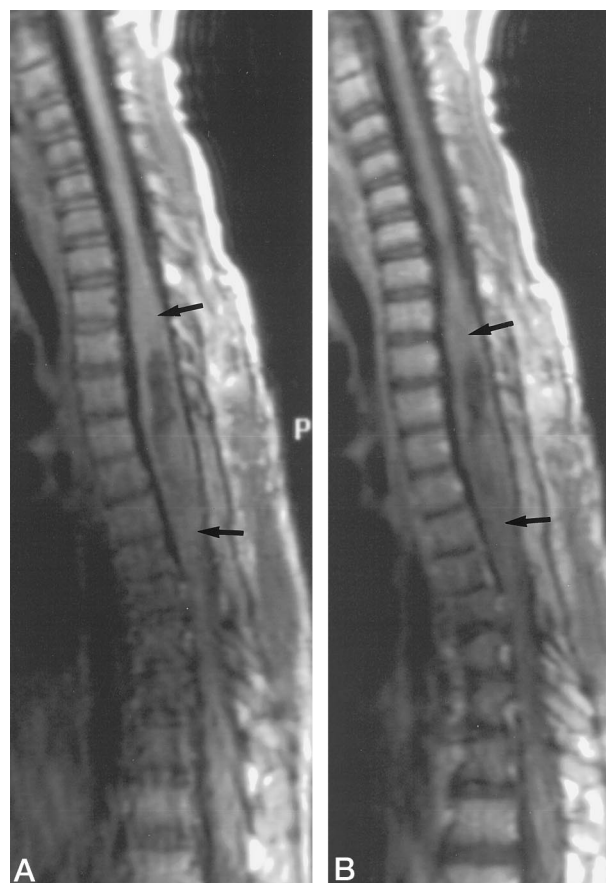

FIG 4. 6-year-old boy with a thoracic ganglioglioma and scoliosis, who had undergone a diagnostic spinal cord biopsy before imaging.

Curved reformatted sagittal spin-echo T1-weighted (500/90/3) images before (A) and after (B) contrast enhancement show an expansile tumor of the upper thoracic cord (arrows), which does not enhance. Note scalloping of posterior vertebral bodies.

Discussion

Pathologic Observations

Gangliogliomas are rare neoplasms of the CNS that consist of a mixture of neoplastic large mature neurons or ganglion cells and neoplastic glial cells. The glial element is usually astrocytic. Tumor grading does not distinguish a prognostically poor group (22, 53, 54, 55). Since Courville and Anderson's first description of neuroglioneuronal tumors of the CNS in 1930 (55), a large and confusing nomenclature has developed. Synonyms have included ganglioglioma, ganglionic neuroma, neuroastrocytoma, neuroganglioma, ganglionic glioma, neuroma gangliocellulare, and neuroglioma (56–58). The current classification is based on the relative differentiation of the neuronal component and the presence of glial elements. If the tumor consists solely of large relatively mature neoplastic neurons or ganglion cells, it is termed gangliocytoma. The additional presence of a neoplastic astrocytic component confers the term ganglioglioma. Additional features, such as a substantial population of small neoplastic mature neurons, bestow the term ganglioglioneurocytoma (3). It is clear from recent

work by others and by us that this tumor has formerly been underdiagnosed (8), particularly in the spinal cord. However, the number of intramedullary cord neoplasms that are gangliogliomas reported here and in our earlier studies is clearly beyond previous expectations. Two main factors underlie this phenomenon: the practice at many centers of examining small biopsy samples from spinal cord neoplasms rather than large resections, and the limited availability, until recently, of reliable and readily available diagnostic immunohistochemical methods to separate gangliogliomas from astrocytomas involving gray matter and thus containing trapped native neurons (3-9). The standard or traditional diagnostic criteria (described briefly in the Methods section) are relatively reliable; tumors diagnosed as gangliogliomas by competent neuropathologists are unlikely to be astrocytomas or other tumors, as shown by the fact that only two of 42 tumors in our 1993 study originally diagnosed as gangliogliomas by standard criteria were reclassified as astrocytomas on the basis of immunohistochemical analysis (3). However, when a diagnosis of astrocytoma (or, often, anaplastic astrocytoma, based on apparent pleomorphism) is made from hematoxylin-eosin stains of limited tissue samples, there is a significant chance that the tumor is actually a ganglioglioma, because it can be difficult to 1) distinguish large tumor astrocytes from neoplastic neurons (3, 11, 49); 2) find neurons in small samples, as the neoplastic neurons in gangliogliomas are more often clustered than evenly distributed (3, 5, 6, 11, 49-59); or 3) separate neoplastic from trapped native neurons (3-9, 49, 50, 59). In a previous study (3), we found 21 tumors originally diagnosed as astrocytomas at our institution that were only recognized as gangliogliomas by using immunohistochemical analysis, and 23 of 25 gangliogliomas originally examined at outside institutions that were called astrocytoma until we performed immunohistochemical studies.

The immunohistochemical studies that help establish a diagnosis of ganglioglioma in tumors that have a potential ganglion cell population that must be separated from large tumor astrocytes and from normal trapped neurons involves examination of slides stained for the glial marker GFAP and for the synaptic vesicle protein synaptophysin. The GFAP marker does not decorate neurons (trapped or neoplastic). The synaptophysin stains will show a distinctive pattern of perikaryal surface immunoreactivity virtually unique to abnormal neurons, as reported previously (4). This technique has been used extensively in our prior published studies (2, 22, 23) and has been verified by others (5-7) (Fig 1E). This pattern is now included in standard descriptions of gangliogliomas included in the CNS Fascicle of the Armed Forces Institute of Pathology (49) and in the revised World Health Organization classification (50). An identical pattern has been observed with other markers of synaptic vesicle distribution, including synapsin I (9) and SV2 (60), ruling out any possibility of the synaptophysin staining representing an

aberrant expression of a neuronal protein by neoplastic astrocytes.

Recently, the diagnostic utility of this pattern has been questioned by Rosenblum and others (51, 53), who, although acknowledging that no normal neurons in the cerebrum display this staining pattern, have pointed out that spinal cord anterior horn cells and neurons of Clarke's column normally display perikaryal surface staining resembling that seen on neurons in gangliogliomas. Thus, it is questioned whether the gangliogliomas reported as such by us (3, 22, 23) are not, in fact, misdiagnosed astrocytomas (51, 53).

This argument can be refuted on several grounds. Most important, an examination of synaptophysin immunostains of normal anterior horn tissue shows a background neuropil that is densely immunopositive in addition to the described perikaryal staining; it is clear that pure glial tumors infiltrating the anterior horn of Clarke's column will lie in such a neuropil, which will abruptly lose its immunoreactivity at the borders with the white matter (52). We are fully cognizant of these patterns, and all of the gangliogliomas described here were tumors in which the neurons with perikaryal surface staining showed atypical cytologic features or were clearly in white matter tracts and not in the anterior horns or dorsal gray matter.

Secondary arguments can also be made to support our diagnoses. All cases were reviewed by two neuropathologists, both with extensive and documented experience with the pathology of CNS neoplasms. One of us was not involved in the earlier synaptophysin studies and has no appointment at or other official relationship with NYU Medical Center. Both neuropathologists agreed upon all the diagnoses of the tumors reported herein. Furthermore, the MR data showed distinct and significant differences between tumors labeled by the pathologists as astrocytomas, those labeled as ependymomas, and those labeled as gangliogliomas (see below), an unlikely event if most of the gangliogliomas were actually misdiagnosed astrocytomas.

If these arguments are accepted, as we clearly believe they should be, two additional pathologic or diagnostic points are raised. One has to do with the frequency with which gangliogliomas occur in the cord. In our large series of 174 patients with radically resected intramedullary cord tumors, the most common single diagnosis was that of low-grade fibrillary astrocytoma (roughly 40% of all tumors), gangliogliomas being second most common (roughly 25%), and high-grade astrocytomas and ependymomas occurring in roughly equal frequency (11% to 12% each) (52). It is noteworthy that, with large excision specimens to study, no tumors were identified as pilocytic astrocytomas.

The second point concerning cord gangliogliomas has to do with recurrence rates after radical surgery. Tumors that we have diagnosed as gangliogliomas of the spinal cord recurred in roughly 40% of patients after radical resection, whereas those we called low-grade fibrillary astrocytoma recurred in only about 25% of patients (52). Again, if there were a significant

level of misdiagnosis with alleged gangliogliomas representing astrocytomas, these differences should be less striking. How, then, can this be accounted for? We believe that the significantly larger size of the gangliogliomas would more likely lead to a failure to resect or fatally damage tumor cells even during gross total excisions as compared with the smaller astrocytomas. At present, we have no proof of this hypothesis, but we find it plausible. Of related practical importance is that gangliogliomas, from our follow-up data, carry a higher risk of recurrence, which, at our center, would usually result in a second radical surgical procedure; this prognostic difference is an important reason to attempt to help establish the diagnosis preoperatively by the MR features we have just described.

Radiologic Observations

Spinal cord gangliogliomas are relatively benign tumors with slow growth and late clinical presentation, which probably account for the holocord involvement present in four (15%) of the 27 spinal gangliogliomas in our series (Table 1). Holocord involvement was not observed in the group of spinal cord astrocytomas or ependymomas. In keeping with this fact, spinal gangliogliomas average twice the length of astrocytomas and ependymomas. Despite the paucity of cases described in the literature, holocord involvement has been described in three other cases of spinal cord ganglioglioma (16, 20). From our review of the literature, holocord involvement has been reported to occur with a greater frequency in astrocytomas (61) than in ependymomas. The diagnoses for most such reports were not based on histopathologic analysis with routine use of synaptophysin immunostains, so it seems likely that many reported holocord astrocytomas were actually gangliogliomas. However, their occurrence is unusual (39); we found one report of a holocord ependymoma (62).

Reactive cysts are a common feature of all intramedullary spinal cord tumors (32, 36). Histopathologically, these cysts are not lined by neoplastic cells. With contrast-enhanced MR imaging, these cysts do not show mural enhancement. Clinically, they commonly account for pain in the neuraxis but do not appear to cause neurologic deficit. This has therapeutic implications in that these cysts are treated by simple drainage, resection being reserved for tumoral cysts (24). The frequency of reactive cyst formation in our series of spinal cord gangliogliomas is similar to that reported for other intramedullary neoplasms.

Tumoral cysts are lined by neoplastic cells. With contrast-enhanced MR imaging, these may show mural enhancement, which may be circumferential or nodular. Spinal cord gangliogliomas had the greatest tendency for tumoral cyst formation in our series, accounting for 46% of cases (Table 1). Although there is no comparable radiologic literature, there is evidence that cerebral gangliogliomas have a propensity for cyst formation (63), with a rate of occurrence ranging from 38% to 44% (10, 64). Although tumoral

cysts appear to have a strong association with spinal cord gangliogliomas, we are uncertain as to their pathogenesis. We speculate that biologically these tumors have a greater ability to secrete fluid.

In our series, 76% of the spinal cord ependymomas were located centrally within the spinal cord. In contrast, this was not observed in any of the cases of spinal cord gangliogliomas or spinal cord astrocytomas (Table 1), which is in keeping with the presumed centrifugal growth of ependymomas arising from the ependymal cells lining the central canal (40, 47).

Eight-four percent of the spinal cord gangliogliomas in our series showed mixed signal intensity on T1-weighted images. Of the four cases with MR features of spinal cord gangliogliomas reported in the literature, two had similar mixed signal intensity on T1-weighted images (18, 19). Mixed signal on T1-weighted images was not observed in any of the spinal cord astrocytomas or spinal cord ependymomas in our series. The majority of spinal cord astrocytomas were hypointense relative to normal neural tissue (Table 2).

After contrast administration, patchy enhancement was observed in 65% of cases of spinal cord ganglioglioma (Figs 1 and 2 and Table 2). It was seen in only one case of spinal cord astrocytoma and in none of the cases of spinal cord ependymoma. Abnormal contrast enhancement, which reached the surface of the cord (Fig 3), was observed in 58% of spinal cord gangliogliomas in our series but in only one case of spinal cord astrocytoma and in none of the cases of spinal cord ependymoma. Focal intense enhancement was observed in 19% of cases of spinal cord gangliogliomas in our series (Fig 3). There is only one case of a contrast-enhanced MR study of a spinal cord ganglioglioma in the literature (19), so an adequate comparison is not possible; however, in that case, focal enhancement was observed. Focal enhancement was present in 65% of the spinal cord ependymomas and diffuse enhancement was noted in 79% of the spinal cord astrocytomas in our series. These findings are consistent with those reported by Parizel et al (40).

We believe that the combination of two different cell populations within gangliogliomas—namely, ganglion cells and glial cells—probably accounts for the mixed signal on T1-weighted images as well as the patchy and cord surface enhancement after contrast administration. At histopathology, it is well recognized that portions of the tumor may be purely glial while other areas are purely neuronal, and yet others a combination of the two. Kitano et al (12) described a pathologic correlate to the extension of contrast enhancement to the cord surface. These authors found clusters of neoplastic ganglion cells extending to the surface of the cord in a case of a ganglioglioma involving the thoracic cord.

Edema, found in 7% of the spinal cord gangliogliomas in our series, was noted more commonly in spinal cord astrocytomas and ependymomas (Table 2). The ability to accurately distinguish edema at MR imaging is controversial. Epstein et al (47) noted that in spinal cord ependymomas, the area of contrast enhance-

ment on MR images corresponded exactly to the tumor at surgery. Therefore, on T2-weighted images, areas that showed prolonged T2 signal and that were not cystic and did not enhance on T1-weighted images were presumed to represent edema. This was confirmed at histopathologic examinations, in which neoplastic cells were not identified in nonenhancing areas of high T2 signal. Parizel et al (40) commented that in spinal cord astrocytomas, owing to their infiltrative nature, areas that may appear to be edema are in fact nonenhancing tumor.

A focus of magnetic susceptibility was seen in only one case in our series of spinal cord gangliogliomas. As none of the tumors in our series had anaplastic features, making hemorrhage unlikely, it is presumed that this represented a focus of calcification. Calcification is a recognized feature in cerebral gangliogliomas, seen in 28% of cases (10). The low prevalence of magnetic susceptibility changes in our series may partly be due to the low-field-strength (0.3- to 0.5-T) magnets that were used in some of our cases as well as to the absence of T2* gradient-echo images in many of the cases. Susceptibility caps were seen most frequently in spinal cord ependymomas (48). These were observed in 20% of cases, which is slightly lower than that reported in the literature (65).

Conclusion

Although spinal cord gangliogliomas are uncommon tumors, they may have a higher rate of occurrence than previously thought. We believe that some tumors that have been diagnosed as spinal astrocytomas may in fact be gangliogliomas. The ability to suggest the diagnosis before surgery has both therapeutic and prognostic significance. Features that should alert the neuroradiologist to this entity, in descending order of importance, include long tumor segment or holocord involvement, scoliosis and bony remodeling, mixed signal on T1-weighted MR images, prominent tumoral cyst, patchy enhancement extending to the cord surface after contrast administration, spinal cord neoplasm that fails to enhance, lack of edema, lack of MR-demonstrated hemosiderin or calcification, absence of centricity of tumoral enhancement, and young age of the patient.

References

- Garrido E, Becker L, Hoffman H, Hendrick E. **Gangliogliomas in children: a clinicopathologic study.** *Childs Brain* 1978;4:339-346
- Zulch K. *Atlas of Gross Neurosurgical Pathology.* New York: Springer; 1975:49
- Miller DC, Lang FF, Epstein FJ. **Central nervous system gangliogliomas, 1: pathology.** *J Neurosurg* 1993;79:859-866
- Miller DC, Koslow M, Budzilovich GN, Burstein DE. **Synaptophysin: a sensitive and specific marker for ganglion cells in central nervous system neoplasms.** *Hum Pathol* 1990;21:271-276
- Diepholder HM, Schwechheimer K, Mohadjer M, Knoth R, Vlk B. **A clinicopathologic and immunomorphologic study of 13 cases of ganglioglioma.** *Cancer* 1991;68:2192-2201
- Isimbaldi G, Sironi M, Tonnarelli GP, Roncoroni M, Declich P, Galli C. **Ganglioglioma: a clinical and pathological study of 12 cases.** *Clin Neuropathol* 1996;15:192-199
- Jaffrey PB, Mundt AJ, Baunoch DA, et al. **The clinical significance of extracellular matrix in gangliogliomas.** *J Neuropathol Exp Neurol* 1996;55:1246-1252
- Miller DC. **The pathology of gliomas, including tumors of neuronal origin.** In: Tindall GT, Cooper PR, Barrow DL, eds. *The Practice of Neurosurgery.* Baltimore: Williams & Wilkins; 1996:601-635
- Smith TW, Nikulasson S, De Girolami U, DeGennero LJ. **Immunohistochemistry of synopsin I and synaptophysin in human nervous system and neuroendocrine tumors. Applications in diagnostic neurooncology.** *Neuropathology* 1993;12:335-342
- Castillo M, Davis PC, Takei YD, et al. **Intracranial gangliogliomas: MR, CT and clinical findings in 18 patients.** *AJR Am J Roentgenol* 1990;154:607-612
- Kalyan-Raman U, Olivero M. **Ganglioglioma: a correlative clinicopathological and radiological study of ten surgically treated cases with follow-up.** *Neurosurgery* 1987;20:428-433
- Kitano M, Takayama S, Nagao T, Yoshimura O. **Malignant ganglioglioma of the spinal cord.** *Acta Pathol Jpn* 1987;37:1009-1018
- Foerster A. **Ein Ganglioglioneurom des Ruckenmarks.** *Virchows Arch* 1924;253:116-124
- Lichtenstein B, Zeitlin H. **Ganglioglioma of the spinal cord associated with pseudosyringomyelia: a histologic study.** *Arch Neurol Psychiatry* 1937;37:1356-1370
- Bevilaqua G, Sarnelli R. **Ganglioglioma of the spinal cord: a case with a long survival.** *Acta Neuropathol (Berl)* 1979;48:239-242
- Albright L, Byrd R. **Ganglioglioma of the entire spinal cord.** *Childs Brain* 1980;6:274-280
- Wald U, Levy P, Rappaport Z, Michowitz S, Schisger L, Shalit M. **Conus ganglioglioma in a 2 1/2 year-old boy.** *J Neurosurg* 1985;62:142-144
- Kamikaseda K, Takaki T, Hikita T. **Intramedullary ganglioglioma of the spinal cord: case report.** *Neurol Med Chir (Tokyo)* 1989;29:838-841
- Miller G, Towfighi J, Page R. **Spinal cord ganglioglioma presenting as hydrocephalus.** *J Neurol Oncol* 1990;9:147-152
- Cheung Y-K, Fung C-F, Chan F-L, Leong L. **MRI features of spinal ganglioglioma.** *Clin Imaging* 1991;15:109-112
- Rodewold L, Miller D, Sciorra L, Barabas G, Lee M. **Central nervous system neoplasm in a young man with Martin-Bell syndrome—fra(x)—XLMR.** *Am J Med Genet* 1987;26:7-12
- Lang F, Epstein F, Ransohoff J, et al. **Central nervous system gangliogliomas, 2: clinical Outcome.** *J Neurosurg* 1993;79:867-873
- Constantini S, Houten J, Miller DC, et al. **Intramedullary spinal cord tumors in children: a series of 19 patients.** *J Neurosurg* 1996;85:1036-1043
- Epstein F, Epstein N. **Surgical treatment of spinal cord astrocytomas of childhood: a series of 19 patients.** *J Neurosurg* 1982;57:685-689
- Cooper P, Epstein F. **Radical resection of intramedullary spinal cord tumors in adults: recent experience in 29 patients.** *J Neurosurg* 1985;63:492-499
- Epstein FJ, Farmer J-P, Freed D. **Adult intramedullary astrocytomas of the spinal cord.** *J Neurosurg* 1992;77:335-339
- Cohen AR, Wisoff JH, Allen JC, et al. **Malignant astrocytomas of the spinal cord.** *J Neurosurg* 1989;70:50-54
- Cooper PR. **Management of intramedullary spinal cord tumors.** In: Tindall GT, Cooper PR, Barrow DL, eds. *The Practice of Neurosurgery.* Baltimore: Williams & Wilkins; 1996:1335-1346
- Bydder G, Brown J, Niendorf H, Young I. **Enhancement of cervical intraspinal tumors in MR imaging with intravenous gadolinium-DTPA.** *J Comput Assist Tomogr* 1985;9:847-851
- DiChiro G, Doppman J, Dwyer A, et al. **Tumors and arteriovenous malformations of the spinal cord: assessment using MR.** *Radiology* 1985;156:689-697
- Rubin J, Aisen A, DiPietro M. **Ambiguities in MR imaging of tubular cysts in the spinal cord.** *J Comput Assist Tomogr* 1986;10:395-398
- Goy A, Pinto R, Raghavendra B, Epstein F, Kricheff I. **Intramedullary spinal cord tumors: MR imaging with emphasis on associated cysts.** *Radiology* 1986;161:381-386
- Entzmann D, O'Donohue J, Rubin J, Shuer L, Cogen P, Silverberg G. **CSF pulsations within non-neoplastic spinal cord cysts.** *AJR Am J Roentgenol* 1987;149:149-157
- Williams A, Haughton V, Pojunas K, Daniels D, Kilgore D. **Differentiation of intramedullary neoplasms and cysts by MR.** *AJR Am J Roentgenol* 1987;149:159-164
- Scotti G, Scialfa G, Colombo N, Landoni L. **Magnetic resonance diagnosis of intramedullary tumors of the spinal cord.** *Neuroradiology* 1987;29:130-135
- Slasky B, Bydder G, Niendorf H, Young I. **MR imaging with**

- gadolinium-DTPA in the differentiation of tumor, syrinx and cyst of the spinal cord. *J Comput Assist Tomogr* 1987;11:845-850
37. Sze G, Krol G, Zimmerman R, Deck M. **Intramedullary disease of the spine: diagnosis using gadolinium-DTPA-enhanced MR imaging.** *AJR Am J Roentgenol* 1988;151:1193-1204
 38. Stimac G, Porter B, Olson D, Gerlach R, Genton M. **Gadolinium-DTPA enhanced MR imaging of spinal neoplasms: preliminary investigations and comparisons with enhanced spin echo and STIR sequences.** *AJR Am J Roentgenol* 1988;151:1185-1192
 39. Zimmerman R, Bilanuik L. **Imaging of tumors of the spinal cord.** *Radiol Clin North Am* 1988;26:965-1007
 40. Parizel D, Baleriaux D, Rodesch G, et al. **Gd-DTPA enhanced MR imaging.** *AJNR Am J Neuroradiol* 1989;10:249-258
 41. Dillon W, Norman D, Newton T, Bolla K, Mark A. **Intradural spinal cord lesions: Gd-DTPA enhanced MR imaging.** *Radiology* 1989;170:229-237
 42. Sze G, Bravo S, Krol G. **Spinal lesions: quantitative and qualitative temporal evolution of gadopentate dimeglumine enhancement in MR imaging.** *Radiology* 1989;170:846-849
 43. Clarke C, Hawnaur J, Prvulovich E, Yuill G, Bannister C. **Case report: magnetic resonance imaging with gadolinium-DTPA enhancement in the differentiation of benign from neoplastic cord cavitation.** *Clin Radiol* 1990;41:214-216
 44. Chamberlain M, Sandy A, Press C. **Spinal cord tumors: gadolinium-DTPA enhanced MR imaging.** *Neuroradiology* 1991;33:469-474
 45. Sze G, Stimac G, Bartlett C, et al. **Multicenter study of gadopentate dimeglumine as an MR contrast agent: evaluation in patients with spinal cord tumors.** *AJNR Am J Neuroradiol* 1990;11:967-974
 46. Brunerg J, DiPietro M, Venes J, et al. **Intramedullary lesions of the pediatric spinal cord: correlation of findings from MR imaging, intraoperative sonography, surgery and histologic study.** *Radiology* 1991;181:573-579
 47. Epstein F, Farmer J, Freed D. **Adult intramedullary spinal cord ependymomas: the result of surgery in 38 patients.** *J Neurosurg* 1993;79:204-209
 48. Fine MJ, Kricheff II, Freed D, Epstein FJ. **Spinal cord ependymomas: magnetic resonance imaging features.** *Radiology* 1995;197:655-658
 49. Burger PC, Scheithauer BW. *Tumors of the Central Nervous System: Atlas of Tumor Pathology.* Third Series, Fascicle 10. Washington, DC: Armed Forces Institute of Pathology; 1994;163-172
 50. Kleihues P, Burger PC, Scheithauer BW. *Histologic Typing of Tumors of the Central Nervous System.* Berlin: Springer; 1993:76
 51. Rosenblum MK. **Central nervous system.** In: Rosai J, ed. *Ackerman's Surgical Pathology.* St Louis: Mosby; 1966:2303-2306
 52. Miller DC, Rorke LB, Weinberg J, Allen JC, Epstein FJ. **Histopathological diagnoses of intramedullary spinal cord tumors in children (Abstract).** *J Neuropathol Exp Neurol* 1997;56:607
 53. Johannson J, Rekatte H, Roessman U. **Gangliogliomas: pathological and clinical correlation.** *J Neurosurg* 1981;54:58-63
 54. Wolf H, Muller M, Spinale M, Zentner J, Schramm J, Wiestler O. **Ganglioglioma: a detailed histopathological and immunohistochemical analysis of 61 cases.** *Acta Neuropathol* 1994;88:166-173
 55. Courville CB, Anderson FM. **Neuroglioneuritic tumors of the central nervous system: review of the literature and report of two cases.** *Arch Neurol Psychiatry* 1930;24:439-491
 56. Pick L, Bielschowsky M. **Über das System der Neurome und Beobachtungen an Einem Ganglioglioneurum des Gehirns (Nebst Untersuchungen über die Genese der Nervenfasern in "Neurinomen."** *Z Gesamte Neurol Psychiatry* 1912;4:972-974
 57. Foerster O, Gagel O. **Ein fall von Gangliocytoma der Oblongata.** *Z Gesamte Neurol Psychiatry* 1932;141:797-823
 58. Zhang PJ, Rosenblum MK. **Synaptophysin expression in the human spinal cord: diagnostic implications of an immunohistochemical study.** *Am J Surg Pathol* 1996;20:273-276
 59. Burger PC, Scheithauer B, Vogel FS. *Surgical Pathology of the Nervous System and Its Coverings.* 3rd ed. New York: Churchill Livingstone; 1991:325-336
 60. Sharma S, Quinn B, Chen V, Carlson S, Miller DC. **New immunodiagnostic modalities in neuronal tumors (abstract).** *J Neuropathol Exp Neurol* 1996;55:626
 61. Reimer R, Onofrio B. **Astrocytomas of the spinal cord in children and adolescents.** *J Neurosurg* 1985;63:669-675
 62. Horrax G, Henderson D. **Encapsulated intramedullary tumor involving the spinal cord from medulla to conus.** *Surg Gynecol Obstet* 1939;68:814-819
 63. Tampieri D, Moudjian R, Melanson D, Ethier R. **Intracranial gangliogliomas in patients with partial complex seizures: CT and MR imaging findings.** *AJNR Am J Neuroradiol* 1991;12:749-755
 64. Dorne H, O'Gorman A, Melanson D. **Computed tomography of intracranial gangliogliomas.** *AJNR Am J Neuroradiol* 1986;7:281-285
 65. Nemoto Y, Inoue Y, Tashiro T, et al. **Intramedullary spinal cord tumors: significance of associated hemorrhage at MR imaging.** *Radiology* 1992;182:793-796

See article on cerebral gangliogliomas on page 801 and commentaries on cerebral and spinal gangliogliomas on pages 807-811 of this issue.