AJNR

MR sialography using half-Fourier acquisition single-shot turbo spin-echo (HASTE) sequences.

R Murakami, Y Baba, R Nishimura, T Baba, N Matsumoto, Y Yamashita, T Ishikawa and M Takahashi

AJNR Am J Neuroradiol 1998, 19 (5) 959-961
http://www.ajnr.org/content/19/5/959

AJNR Am J Neuroradiol 19:959–961, May 1998

MR Sialography Using Half-Fourier Acquisition Single-Shot Turbo Spin-Echo (HASTE) Sequences

Ryuji Murakami, Yuji Baba, Ryuichi Nishimura, Takashi Baba, Nobutake Matsumoto, Yasuyuki Yamashita, Takeru Ishikawa, and Mutsumasa Takahashi

Summary: We describe our preliminary experience with the half-Fourier acquisition single-shot turbo spin-echo (HASTE) sequences for MR imaging of the salivary gland ducts. In the majority of patients, the main parotid and/or submandibular gland ducts and large branches within the glands were detectable on MR images obtained in 2 seconds per section and within 3 minutes for the entire examination. MR sialography using HASTE sequences can be combined with conventional MR studies for the salivary glands.

MR imaging is widely used in examinations of the salivary glands (1–4), but reports concerning its use in the ductal system have been limited (5). Instead, X-ray sialography is usually performed to determine the presence of ductal abnormalities in the salivary glands (3, 6). However, X-ray sialography requires cannulation of the ducts and injection of contrast medium; and in the presence of a calculus at the duct orifice, cannulation may be impossible owing to edema of the surrounding buccal mucosa. Furthermore, X-ray sialography is contraindicated in patients with acute infection (3). As a complete noninvasive technique, Lomas et al (7) reported the first approach toward MR sialography using heavily T2-weighted rapid acquisition with relaxation enhancement (RARE) sequences.

The half-Fourier acquisition single-shot turbo spin-echo (HASTE) technique is a high-speed, heavily T2-weighted sequence with 128 echo train lengths that are obtained in approximately 1 to 2 seconds and that show static fluid as bright signal (8, 9). We describe our preliminary experience in using this HASTE sequence for imaging the salivary gland ducts.

Methods

Twelve consecutive patients with possible or definite abnormalities of the salivary glands were studied with a 1.5-T superconductive unit with a 25-mT/m maximum gradient capability (Magnetom Vision; Siemens, Erlangen, Germany) and a standard head coil. At the same time that conventional MR studies of the salivary glands were obtained, MR sialography was performed using a HASTE sequence with an effective TE of 87 milliseconds, one excitation, and a 256 × 240 matrix. For HASTE imaging, after a single excitation, 128 echo train lengths were acquired with a specific encoding for each echo (8, 9). Fat saturation suppressed the signals from the subcutaneous fat. A multisection acquisition technique was used with a section thickness of 5 mm followed by maximum-intensity-projection reconstruction. Five to nine sequential sections were acquired in 10 to 18 seconds (2 seconds per section). The salivary gland ducts were identified on an initial set of axial HASTE images through the salivary glands (parotid and/or submandibular glands), and oblique sagittal acquisition was used to image the salivary gland ducts. The additional imaging time required for all MR sialography examinations was less than 3 minutes.

Results

The main parotid and/or submandibular gland ducts and large branches within the glands were visible on the axial and sagittal oblique images in eight of 12 cases (Figs 1 and 2). Some ducts in some patients were not clearly shown because of metallic artifacts by dental amalgams (one case) or insufficiently suppressed fat (three cases) (Fig 3). In seven cases, the course or obstruction of the main duct on MR sialography was confirmed by plain film X-ray sialography. Visualization of small branches by MR sialography was poor.

Discussion

Noninvasive bright-fluid imaging of duct secretions using MR techniques was applied initially in examinations of the biliary tree and pancreatic ducts (10, 11). The first applications of MR cholangiopancreatography (MRCP) were done with a heavily T2-weighted gradient-echo sequence (11). Recently, several reports have proposed modifications of the RARE technique to obtain MRCP images without artifacts from respiration during a single breath-hold (8, 10). HASTE is a modified sequence of the RARE technique in which 128 echo train lengths are used to obtain heavily T2-weighted images in a short time (8, 9). Because of the T2 decay during data acquisition, tissues with a short T2 produce practically no signals in the echoes at the end of the pulse train, making HASTE suitable for imaging fluid-containing areas.

Received March 27, 1997; accepted after revision July 14.

From the Departments of Radiology (R.M., Y.B., R.N., T.B., N.M., Y.Y., M.T.) and Otorhinolaryngology (T.I.), Kumamoto University School of Medicine, Kumamoto, Japan.

Address reprint requests to Ryuji Murakami, MD, Department of Radiology, Kumamoto University School of Medicine, 1–1–1 Honjo, Kumamoto 860, Japan.

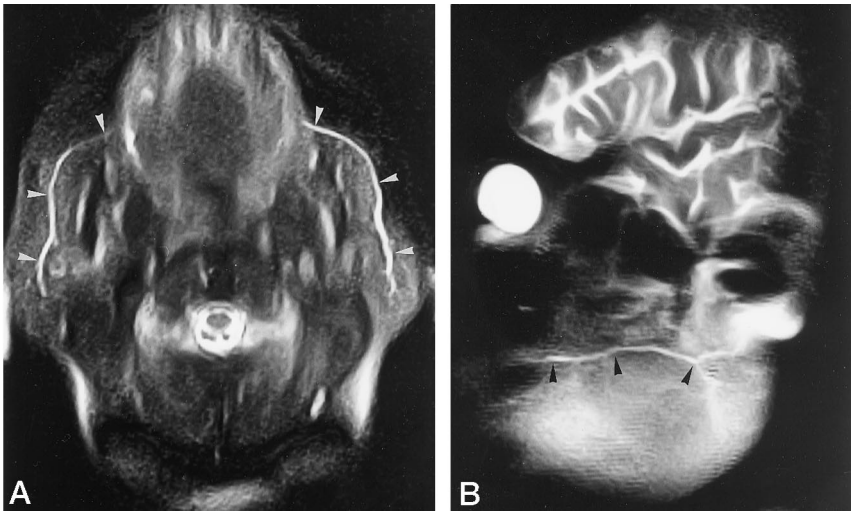

FIG 1. Axial (*A*) and oblique sagittal (*B*) MR sialograms of normal parotid gland ducts (*arrowheads*).

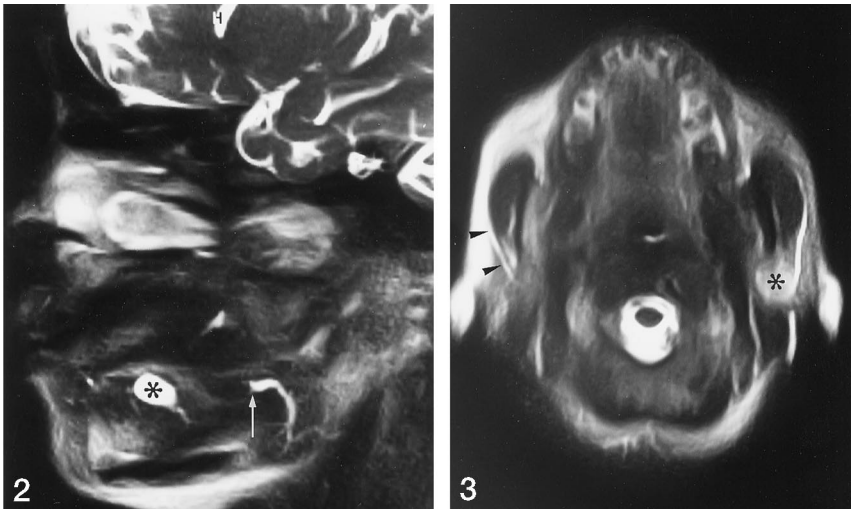

FIG 2. 58-year-old woman with inflammatory stenosis of the right submandibular gland duct who had been treated previously for a right submandibular calculus. An oblique sagittal image of the right submandibular gland duct shows obstruction (*arrow*) and dilatation in the posterior part of the duct. The point of obstruction corresponded to the findings of X-ray sialography. Ranula in the right sublingual gland (*asterisk*) is also seen.

FIG 3. 21-year-old woman with a pleomorphic adenoma in the deep lobe of left parotid gland. Axial image shows not only the bilateral main parotid gland ducts but also a mass lesion (*asterisk*) in the deep lobe of the left parotid gland. The right parotid gland duct (*arrowheads*) is visible only faintly owing to insufficiently suppressed signal of subcutaneous fat.

Because later echoes determine image contrast, the resolution has been degraded in the phase-encoding direction. However, this degradation was apparent only in tissues with a short T2. This sequence has been widely used for demonstrating static fluid in the ducts, such as the biliary tree, pancreatic duct, and urinary tract (8–10).

We have applied HASTE sequences to sialography, and found that this technique can be used to rapidly examine salivary gland ducts within 3 minutes. Furthermore, HASTE images may be used not only to evaluate the duct but also to determine the presence of parenchymal lesions (Fig 3).

As pointed out by Lomas et al (7), MR sialography has several advantages over conventional X-ray sialography. The technique is noninvasive without requiring cannulation of the duct, injection of contrast medium, or use of ionizing radiation. Furthermore, it is possible to accurately assess the diameter of a duct and to determine obstruction in its posterior part (Fig 2). Potential limitations of the technique include the usual contraindications for MR imaging, such as pacemakers and need to immobilize patients during the examination. Adjacent dental amalgam may cause image distortion, as seen in our patients with metallic artifacts. Another limitation of MR sialography is its inability to show minor abnormalities, such as mild narrowing of the main duct and changes of the small branches.

Conclusion

The advantage of the HASTE sequence is that it enables the examiner to obtain heavily T2-weighted images in a short time, in 2 seconds per section and within 3 minutes for the entire study. The examination can be combined with conventional MR studies for parenchymal lesions in the salivary glands. However, further studies are required to establish the utility of this technique.

References

1. Teresi LM, Lufkin RB, Wortham DG, Abemayor E, Hanafee WN. **Parotid masses: MR imaging.** *Radiology* 1987;163:405–409
2. Mandelblatt SM, Braun IF, Davis PC, Fry SM, Jacobs LH, Hoffman JC. **Parotid masses: MR imaging.** *Radiology* 1987;163:411–414

3. Hébert G, Ouimet-Oliva D, Nicolet V, Bourdon F. **Imaging of the salivary gland.** *Can Assoc Radiol J* 1993;44:342–349
4. Teresi LM, Kolin E, Lufkin RB, Hanafee WN. **MR imaging of the intraparotid facial nerve: normal anatomy and pathology.** *AJR Am J Roentgenol* 1987;148:995–1000
5. Thibault F, Halimi P, Bely N, et al. **Internal architecture of the parotid gland at MR imaging: facial nerve or ductal system?** *Radiology* 1993;188:701–704
6. Buckenham TM, George CD, McVicar D, Moody AR, Coles GS. **Digital sialography: imaging and intervation.** *Br J Radiol* 1994;67: 524–529
7. Lomas DJ, Carroll NR, Antoun GJNM, Freer CE. **MR sialography: work in progress.** *Radiology* 1996;200:129–133
8. Miyazaki T, Yamashita Y, Tsuchigame T, Yamamoto H, Urata J, Takahashi M. **MR cholangiopancreatography uing HASTE (half-Fourier acquisition single-shot turbo spin-echo) sequences.** *AJR Am J Roengtenol* 1996;166:1297–1303
9. Tang Y, Yamashita Y, Namimoto T, et al. **The value of MR urography that uses HASTE sequences to reveal urinary tract disorders.** *AJR Am J Roentgenol* 1996;167:1497–1502
10. Reinhold C, Bret PM. **Current status of MR cholangiopancreatography.** *AJR Am J Roentgenol* 1996;166:1285–1295
11. Wallner BK, Schumacher KA, Weidenmaier W, Friedrich JM. **Dilated biliary tract: evaluation with MR cholangiography with a T2-weighted contrast-enhanced fast sequence.** *Radiology* 1991;181: 805–808