

Are your **MRI contrast agents** cost-effective?

Learn more about generic **Gadolinium-Based Contrast Agents**.



**FRESENIUS
KABI**

caring for life

AJNR

**Imaging of cochlear and auditory brain stem
implantation.**

W W Lo

AJNR Am J Neuroradiol 1998, 19 (6) 1147-1154

<http://www.ajnr.org/content/19/6/1147.citation>

This information is current as
of April 19, 2024.

Imaging of Cochlear and Auditory Brain Stem Implantation

William W. M. Lo

The cochlear implant is an electronic auditory prosthesis with a component that is surgically inserted in the ear and coupled with a detachable component that is worn externally like a hearing aid. It is designed to stimulate the spiral ganglion cells in patients whose hair cells have been lost (1). An auditory brain stem implant is a similar device implanted in or on the brain stem, to stimulate the cochlear nuclei in patients whose cochlear nerves have been lost (2). Both devices give the sensation of sound to otherwise deaf patients. Imaging plays key roles in the preoperative and postoperative evaluation of both devices.

Development of the cochlear implant began in the 1960s (3). After slow initial acceptance, cochlear implantation is now firmly established as an effective option in the habilitation and rehabilitation of persons with profound to severe hearing impairment (4). Recent advances in speech processing strategy and continued progress in technology have markedly improved auditory results and patient acceptance. To date, nearly 23,000 implantations have been performed worldwide, approximately 14,000 in adults and 9000 in children, including an estimated 4000 in 1997, of which about half were done in the United States. Initially confined to tertiary referral centers, implantations are now often performed in community practices. Radiologists are thus increasingly likely to be called upon to provide imaging examinations of candidates for cochlear implantation.

Auditory brain stem implantation, first attempted in 1979, is now undergoing multicenter clinical trials in the United States under Food and Drug Administration monitoring. Multicenter trials are also being conducted in Europe. Currently, the subjects are limited to patients with bilateral acoustic tumors. To date, somewhat over 100 patients have received implants.

This review will highlight the fundamental principles, technology, and anatomy of cochlear implantation as well as the important aspects of imaging in cochlear implantation. The role of imaging in auditory brain stem implantation will be briefly discussed.

The Cochlear Implant

Johnson et al have illustrated the cochlear implant device in an earlier issue of this Journal (5). At

present, two models of cochlear implants are approved by the Food and Drug Administration for adults and children and are marketed in the United States. Both are multichannel intracochlear devices; the Nucleus 22 (Cochlear Corp, Englewood, CO) and the Clarion (Advanced Bionics Corp, Sylmar, CA). Two other systems are undergoing clinical trials, the Combi-40 (Med-E1 Corp, Innsbruck, Austria) and the Nucleus 24 (Cochlear Corp).

The general principle for all models of cochlear implants is the same. The externally worn components consist of an ear-level microphone, a speech processor carried in a pocket, and a transmitter placed behind the ear. All external components are connected to one another by electrical wires. The implanted components consist of a subcutaneous receiver/stimulator that is placed in a shallow well created by excavating the squama of the temporal bone, and a lead wire that is linked to an electrode array inserted in the cochlea. The transmitter and the receiver are usually connected across the intact skin by a pair of magnetic disks, but occasionally are attached by adhesives applied to the skin (6).

Sound waves received by the microphone are transduced into electrical signals, which are filtered to extract the elements necessary for speech recognition and encoded digitally by the processor. The encoded signals are then sent by the transmitter as radio signals across the skin to the receiver. The receive/stimulator reconverts the radio signals to electrical signals and, according to preprogrammed coding, activate the appropriate pairs of implanted electrodes to stimulate the spiral ganglion cells or axons in the cochlea.

In the standard technique of implantation, the electrode array is introduced through the transmastoid facial recess, inserted through a cochleotomy antero-inferior to the round window, and advanced within the scala tympani of the basal turn from its inferior segment to its ascending, superior and descending segments (7) (Fig 1A). Hence, the anatomy of the mastoid process, the tympanic cavity, the cochlea, and the internal auditory canal must be carefully scrutinized by preoperative imaging. Currently, the standard imaging technique for preoperative evaluation is high-resolution CT. Some practitioners have developed forms or checklists to facilitate the reviewing

Address reprint requests to William W. M. Lo, M.D., St. Vincent Medical Center, 2131 W 3rd St, Los Angeles, CA 90057

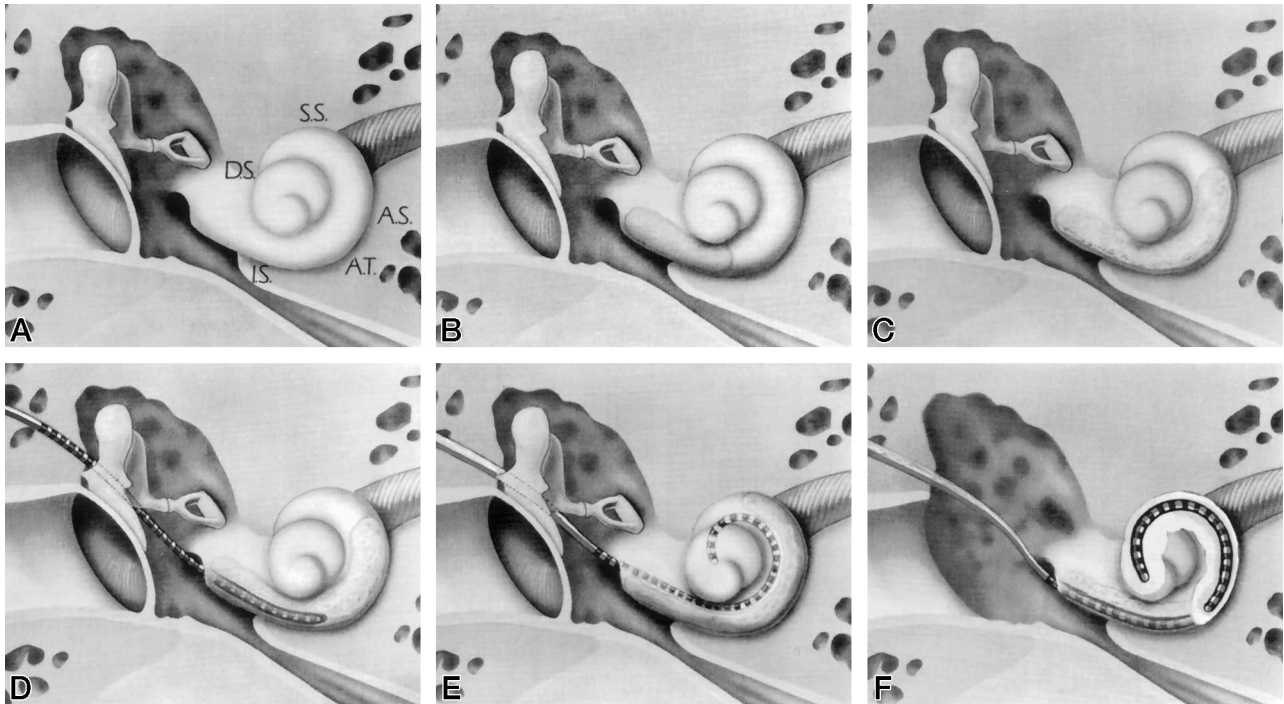


FIG 1. Segmental anatomy of basal turn of cochlea and technical options of implant insertion in obstruction (frontal view of right cochlea).

A, The long, relatively straight inferior segment (IS) comprises approximately half the basal turn. The inferior segment leads through the ascending turn (AT) to the curved upper segments, the ascending segment (AS), the superior segment (SS) and descending segment (DS).

B, The obstruction in the inferior segment may be bypassed by line-of-sight drilling until the open lumen is reached.

C, The upper segment obstruction, involving ascending turn and beyond, cannot be bypassed by intraluminal drilling.

D, Partial insertion of electrode array into 7- to 8-mm tunnel in ossified basal turn.

E, Insertion of electrode array into a patent scala vestibuli is possible when *only* the scala tympani is obstructed.

F, Insertion of electrode array by radical cochleotomy is performed through a radical mastoidectomy. The electrode array lies in an open trough that extends beyond the inferior segment around the modiolus. Reproduced from (6) with permission from the American Academy of Otolaryngology, Head and Neck Surgery Foundation, Inc.

and reporting of such studies (8). An example is offered in the Table.

In general, candidates for cochlear implants must be over two years of age, have bilateral severe to profound sensorineural hearing loss, receive little or no benefit from conventional hearing aids, be in good physical and mental health, and have the motivation and patience for rehabilitation. Candidates must therefore undergo medical, audiological, communicational, psychological, social, and, in the case of children, educational evaluation before implantation (9). Thus, imaging is only a part of the total screening process, but it is indispensable in that it may reveal findings that affect the choice of side, technique, and device, as well as contraindications to implantation.

Postlingually deafened adults and children (individuals deafened after five years of age) receive the greatest benefits from cochlear implantation. Most persons show significantly enhanced speech reading capabilities, attaining scores of 90% to 100% on tests measuring the comprehension of everyday sentence materials (4). Performance on single-word testing is less successful, and a noisy environment significantly detracts from speech perception. Prelingually deafened adults or adolescents generally show little improvement in speech perception, but benefit from

hearing environment sounds (4). For prelingually deafened young children, the results vary widely. Acquisition of communication skills in these children is a prolonged and difficult process for which access to optimal education and rehabilitation services is critical to maximize the benefits available from cochlear implantation (4).

Major complications (ie, those requiring revision surgery) are reported in approximately 5% cases, and include flap problems, device migration or extrusion, and device failure (4). With some exceptions (6, 10), cochlear implants contraindicate MR imaging (11).

CT Technique

Excellent CT scans are requisite for the accurate examination of the cochlea. Fortunately, this is possible for nearly all modern CT units, provided they are optimally used. For routine examination, CT scans may be obtained at either the 0° or the +30° plane (12). Inclinations between these two planes markedly increase radiation to the ocular lenses and should be avoided (12). Modified coronal scans at the +105° plane may be added in cases of complex inner ear anomalies. To minimize volume averaging, section thickness should not exceed 1.5mm. Because the

Sample checklist for preoperative CT examination for cochlear implantation

Mastoid process
Size:
Normal
Hypoplastic
Deep sigmoid
Pneumatization: limited
Throughout
Beyond
Effusion:
No
Yes
Middle ear
Normal
Exposed jugular bulb
Aberrant carotid artery
Persistent stapedial artery
Aberrant facial nerve
Other: specify
Cochlear morphology
Normal
Incomplete partition
Hypoplasia
Common cavity
Aplasia
Cochlear ossification
None
Round window
Length in basal turn, mm
Middle turn
Apical turn
Vestibular aqueduct
Normal
Large
Internal auditory canal diameter, mm
Other
Otosclerosis
Fracture

cochlea measures only about 5mm in diameter, sections should be obtained every 1mm. Incremental edge-enhancement algorithm is slightly superior to an incremental or helical bone algorithm. Small scanning and display fields of view should be used to obtain the smallest possible pixel size for the equipment. Window width should be 4000 HU.

Cochlear Anatomy

The cochlear anatomy has been illustrated in color recently in this Journal (13). The snail-shaped cochlea contains a 32-mm spiral canal that winds $2\frac{1}{2}$ turns around the modiolus (14), which is a conical bony axis perforated by a central canal and numerous canaliculi that transmit fibers from the spiral ganglion to the cochlear nerve (13) (Fig 2). Within the spiral canal are three parallel compartments: the perilymph-filled scala vestibuli, the scala tympani, and sandwiched between the two, the endolymph-filled scala media. The turns of the spiral canal are separated by the interscalar septa. The lumen of the canal is partitioned into anterior and posterior halves by the osseous spiral lamina and the fibrous spiral ligament. The scala vestibuli and the scala media occupy the anterior half; the scala tympani the posterior half. The scala vestibuli and scala tympani communicate through the helicotrema at the cochlear apex. The scala media houses the organ of Corti which contains the hair cells. The spiral ganglion lies within the osseous spiral lamina of the lower $1\frac{1}{2}$ turns of the cochlea.

Fluid waves, set in motion by the vibrating stapes, increase as they propagate up the scala vestibuli and down the scala tympani. As these waves are transmitted across Reissner's membrane, hair cells are stimulated, resulting in electrical potentials, which are converted into action potentials in the auditory nerve fibers (13).

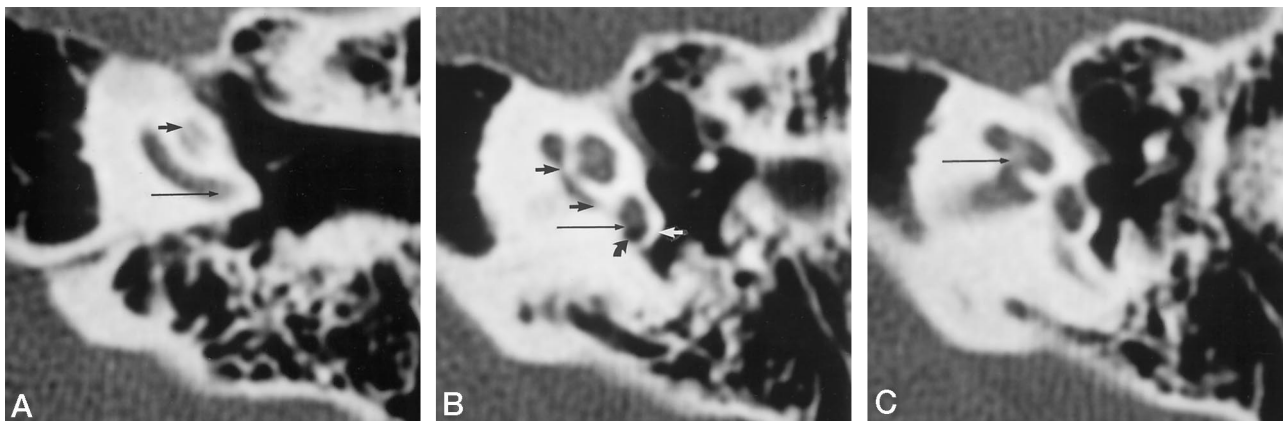


FIG 2. Normal left cochlea shown on first, third, and fourth of five consecutive high-resolution CT sections (1.5-mm thick every 1 mm), from inferior to superior, obtained with an edge-enhancement algorithm at a $+30^\circ$ plane.

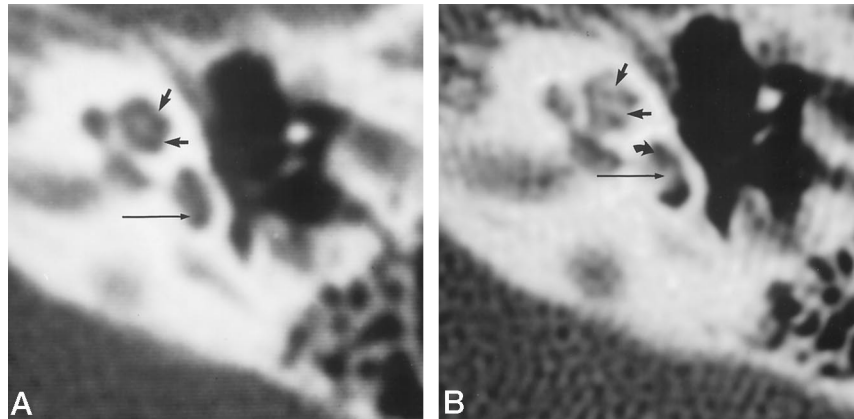
A, The side wall (*long arrow*) of the basal turn curving into the plane of the section should not be mistaken for neossification. The normal osseous spiral lamina (*short arrow*) is often seen.

B, Note the plane of the round window (*long black arrow*), the round window niche (*curved arrow*), and the subiculum (*white arrow*). The medial walls of the basal turn (*short black arrows*) should not be mistaken for neossification. Note also the delicate interscalar septum between the middle and apical turns, as compared with the thicker septum between the basal and middle turns.

C, The modiolus (*arrow*), perforated by many canaliculi, is less dense than the surrounding bone.

FIG 3. A, Normal-appearing left cochlea immediately after total hearing loss from meningitis. Note the complete absence of bone in the scala tympani and scala vestibuli anterior to the plane of the round window (*long arrow*) and the delicate interscalar septum (*short arrows*) between the middle and apical turns extending to notches in the cochlear side walls.

B, Same cochlea 1 year later shows a dense wedge-shaped ossification filling the proximal several millimeters (*long arrow*) of the scala tympani but sparing the scala vestibuli (*curved arrow*) and partial ossification (*short straight arrows*) of the apical and middle turns.



Labyrinthine Neoossification

New bone formation in the cochlea, so called labyrinthine ossification, may occur after illnesses such as meningitis, otosclerosis, otitis media, trauma, and labyrinthectomy (15, 16). Meningitis generally caused by *Haemophilus influenzae* and *Diplococcus pneumoniae* is a common source of ossification and is most often found in children (15, 17) (Fig 3).

Because the infected CSF in meningitis enters the scala tympani through the cochlear aqueduct near the round window, the proximal scala tympani is nearly always the first and the most severely ossified (18). Only occasionally are the middle and the apical turns similarly affected. The scala vestibuli is frequently spared; total cochlear ossification is rare in adults but common in children (19). Ossification may be preceded by fibrosis by several millimeters, but extensive fibrosis without ossification seldom occurs. For unknown reasons, tympanogenic and otosclerotic ossifications also tend to be limited to the proximal several millimeters of the scala tympani (18). Otosclerotic foci may selectively obliterate the round window niche, but the pattern of posttraumatic cochlear ossification is more variable.

The reported accuracy of preimplantation detection of cochlear ossification with CT varies from 53% to more than 90% (17, 20–23), however, better than 85% accuracy is consistently found with high-resolution sections of ≤ 1.5 -mm (19). Ossification may become visible on CT studies as early as 2 months after the onset of meningitis (24).

Cochlear ossification as such does not contraindicate cochlear implantation (19, 25–26), but it does complicate insertion of the electrode array (5, 7). Therefore, advance knowledge of its presence and extent is of great importance to the surgeon even though the decision regarding which implantation technique to use still depends on the actual pattern of ossification found during surgery (7).

If the ossification occludes only the round window or only the straight proximal 8 mm–10 mm of the inferior segment of the basal turn short of its ascending turn, the ossification can be drilled through until an open lumen is reached and the electrode array can be fully inserted (Fig 1B). If the ossification extends to or beyond the ascending turn (Fig 1C), three tech-

nical options are available to the surgeon. The electrode array can be partially inserted into an 8-mm–10-mm tunnel in the inferior segment (Fig 1D); or, if the scala vestibuli is open, it can be fully inserted into the scala vestibuli (Fig 1E). If the scala vestibuli is also obstructed, the simple mastoidectomy can be converted to a radical one. A circummodiolar open trough can be created by drilling beyond the initial tunnel, and the electrode array can then be placed in the trough and secured with temporalis fascia (7) (Fig 1F). Obviously, the last option is a much more complicated procedure.

Cochlear Malformations

Patients with all but the most severe cochlear malformations can benefit from cochlear implantation, but malformations of various degrees carry different surgical implications (27–28). In incomplete partition of the cochlea (29–30), an enlarged vestibular aqueduct (31) or an enlarged vestibule and enlarged vestibular aqueduct, as in the true Mondini malformation (32), may be found. In these instances the apical and middle turns of the cochlea are unpartitioned, but the basal turn is well formed, and the modiolus is short, but its base is normal (29, 30, 32) (Fig 4). In such mild deformities, oozing of perilymph may be encountered at cochleotomy (33), but gushing of CSF is not expected and insertion of the electrode array is usually uneventful.

By contrast, in cochlear dysplasia of a more severe degree known as hypoplasia or dysplasia, and commonly misclassified as the Mondini malformation, the basal turn is wide and the modiolus is absent (32) (Fig 5). In such cases, since the CSF and perilymphatic spaces communicate readily, gushing will occur at cochleotomy, although complete insertion is usually feasible (27). The same holds for the even more dysplastic, amorphous cochleas called single cavity (30), common cavity (29) or primitive sac (32). These are also often misclassified as Mondini malformations (34). In these cases the surgeon must also guard against overinsertion of the electrode array into the internal auditory canal in the absence of a modiolus (28). Cochlear aplasia, otocyst, and labyrinthine aplasia are conditions that preclude implantation (27).

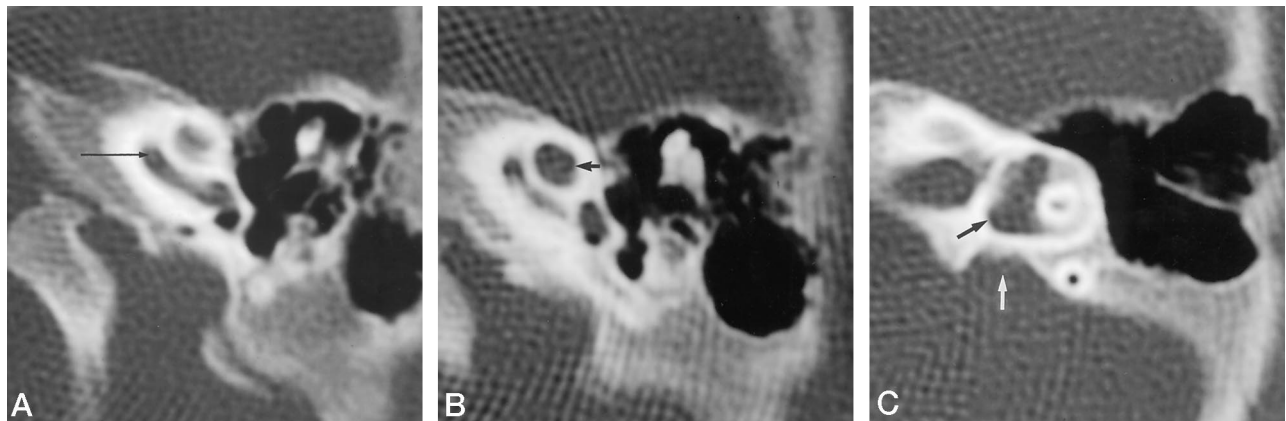


FIG 4. Classic Mondini malformation with the triad of cystic cochlear apex, dilated vestibule, and dilated vestibular aqueduct.

A, Normal basal turn (*arrow*) with its spiral lamina.

B, Unpartitioned, rounded, cystic cochlear apex (*short arrow*).

C, Dilated vestibule (*black arrow*) and vestibular aqueduct (*white arrow*). An intact cochlear base prevents gushing of CSF.

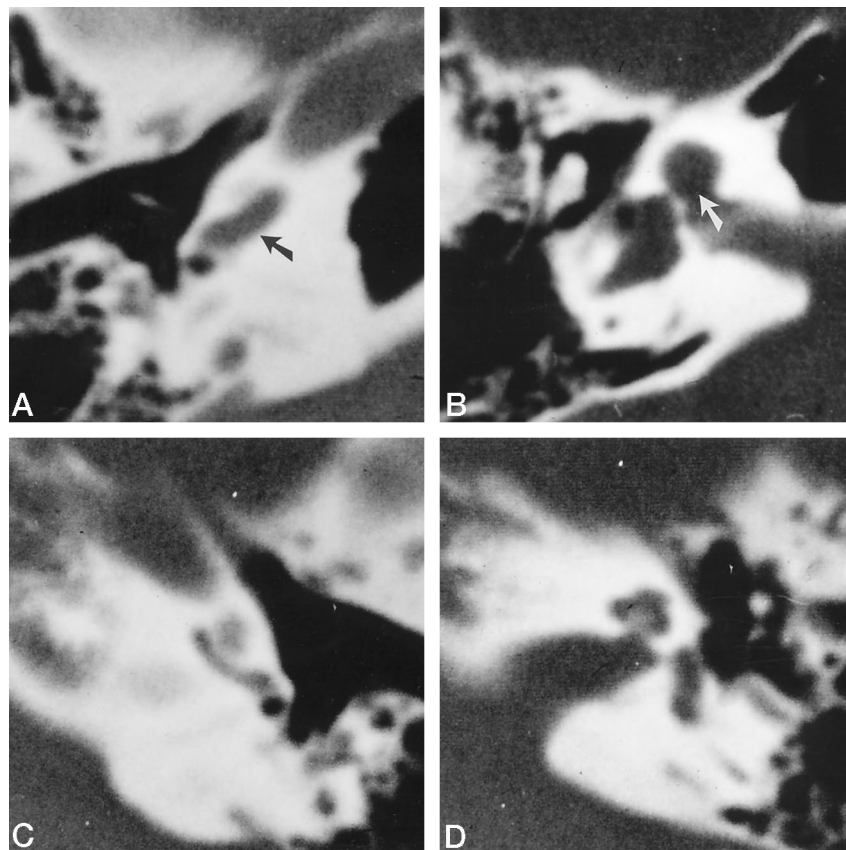


FIG 5. A–D, Right cochlea dysplasia (hypoplasia) (A and B) and normal left cochlea (C and D) in a child with spontaneous otorrhea. The right proximal basal turn (A) is nearly normal but almost twice as wide as the left (C). The distal basal turn and the middle and apical turns (B) are unpartitioned and the modiolus is absent (*arrow* in A and B) in contrast to the normal left cochlea (D). The direct communication of the subarachnoid space of the internal auditory canal and the cochlea predisposes to the development of CSF gushing.

Severe malformations are more likely to be accompanied by aberrant facial nerve canals, which may lead to inadvertent injury of the facial nerve (35).

Cochlear Nerve Agenesis

The otic labyrinth and its neural elements arise independently in embryogenesis. Thus, formation of one does not guarantee the formation of the other. Agenesis of the cochlear nerve may occur despite the presence of a well-formed cochlea.

A narrow internal auditory canal of less than

2.5mm in diameter implies the absence of the vestibulocochlear nerve, and absolutely contraindicates cochlear implantation (36). In such cases, the internal auditory canal may lead exclusively to the facial nerve canal, and, lacking neural perforations, the base of the modiolus appears as a thick, dense plate (Fig 6).

Incidental Abnormalities

Occasionally, incidental abnormalities may compromise the surgical approach to the round window. For example, a hypoplastic mastoid process, a large

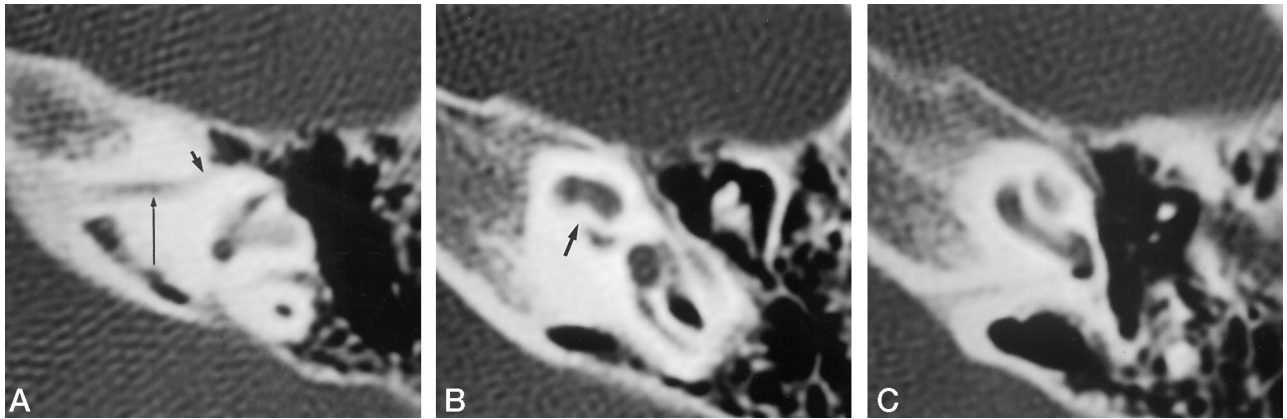


FIG 6. A–C, Agenesis of cochlear nerve with (A) a 1.5-mm internal auditory canal (*long arrow*), leading exclusively to the facial nerve canal (*short arrow*), and with (B) a thick, dense, unperforated base of the modiolus (*arrow*) seen despite the presence of an otherwise well-formed cochlea (C). A narrow internal auditory canal contraindicates cochlear implantation.

protruding jugular bulb, an aberrant carotid artery, a persistent stapedia artery, or an aberrant facial nerve may impede implantation. Middle ear effusion is not in itself a contraindication unless it is infected. An acoustic tumor contraindicates cochlear implantation unless the tumor can be resected and continuity of the cochlear nerve preserved (37, 38).

MR Imaging in Preimplantation Evaluation

The experience in routine preoperative MR imaging is still limited (39–41). High-resolution heavily T2-weighted MR images, obtained either by a fast spin-echo (41) or a constructive interference steady state technique (40), enable detection of cochlear fibrosis not visible on CT scans. Furthermore, MR images obtained with either technique or with conventional sequences may, on rare occasions, disclose absence of the cochlear nerve or unsuspected acoustic tumors. Few surgeons are willing, however, to entirely replace CT with MR imaging; routinely adding MR imaging to CT studies would increase the cost of an already expensive procedure. In addition, MR imaging complicates sedation and monitoring of children. Therefore, in most practices, MR imaging is not included as a routine part of the preimplantation examination but may be used in selected cases.

Positron emission tomography and functional MR imaging of cortical auditory responses have revealed interesting information, but they are not yet used as clinical tools.

Postimplantation Imaging

Routine intraoperative imaging is performed in some practices to confirm radiographically the integrity and positioning of the implant (42, 43). For such purposes, a plain radiograph in posteroanterior, Stenver's, or modified Stenver's projection suffices. The properly inserted electrode array follows a gentle curve within the basal turn of the cochlea with regular spacing between the electrodes. Postoperative radiographs may be obtained when misplacement or extru-




FIG 7. Implanted components of auditory brain stem implant. The receiver/stimulator (*wide arrow*) leads by an electrical wire to the electrode array (*insert*), which consists of eight 1-mm platinum disks on a 2.5 × 8.5-mm Silastic plate with a Dacron backing, in the current American version (the European version consists of 21 0.7-mm platinum disks on a 3 × 8.5-mm Silastic plate). The magnetic disk present in most cochlear implants and earlier versions of auditory brain stem implants has been removed from the Silastic casing (*thin arrow*).

sion of an electrode assembly is suspected from psychophysical testing, or when nonauditory responses are experienced. If the electrode is found to have been misplaced, its position may then be more precisely located with CT. On rare occasions, facial twitching occurs from stimulation of the labyrinthine portion of the facial nerve, which lies close to the superior segment of the basal turn (44). Such stimulations occur most often in the presence of cochlear otospongiosis (45).

Auditory Brain Stem Implant

Unlike the cochlear implant, which requires an intact cochlear nerve, the auditory brain stem implant is intended for patients who have lost their cochlear nerves. The components of the auditory brain stem implant, a modification of the Nucleus 22, are similar to those of the cochlear implant (2) (Fig 7). The electrode array is mounted on a silicone base, 8-chan-

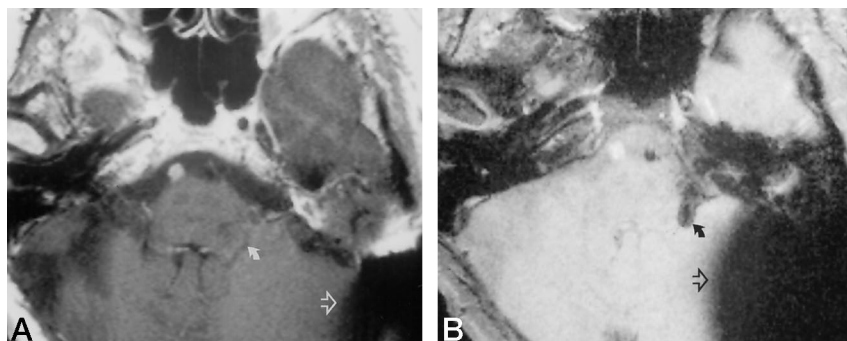


FIG 8. Auditory brain stem implant properly positioned in left lateral recess of fourth ventricle.

A and B, T1-weighted spin-echo MR image (580/15 [TR/TE]) and gradient-echo (fast low-angle shot MR image (210/10) with a 30° angle, respectively). The electrode array (curved arrow) is invisible on (A) but is clearly visible on (B), along with markedly increased artifacts (open arrow) from the subcutaneous receiver/stimulator.

nels in the American version and 21-channels in the European version (46, 47). The implant is not inserted into the cochlea, however, but is introduced via a translabyrinthine craniotomy and implanted under direct vision through the foramen of Luschka deep into the lateral recess of the fourth ventricle. This area immediately borders the lateral surface of the cochlear nuclei (48) and provides long-term positional stability to the electrodes. Electrically evoked brain stem auditory responses are used intraoperatively to identify optimal positioning of the electrodes (2, 46–47).

The results of auditory brain stem implantation have exceeded those of single-channel cochlear implantation. Most patients substantially improve their ability to lip read, and some can recognize open-set speech without lip reading (46, 49). Side effects, which include vibration sensation in the eye thought to be caused by stimulation of the flocculus, twitching in the face (cranial nerve VII), and tightness in the throat (cranial nerve IX), can be minimized or eliminated by altering pulse duration, changing the pairing of electrodes, or deactivating the offending electrodes (46). Complications have been few but include potentially all of those found with cochlear implantation or craniotomy.

During preimplant imaging, certain contraindications to implantation can be identified; infarction involving the cochlear nuclei (50), stereotactic radiation injury to the brain stem (51), and a grossly widened lateral recess. The last condition may allow migration or rotation of the electrode array.

After implantation, the location of the electrode array may need to be clarified. The original ABIs were magnetic and incompatible with MR imaging. The current models manufactured by the Cochlear Corporation since early in 1993 are nonmagnetic and MR-compatible (6) (Fig 7). While the lateral recess can be reliably identified by imaging (48), the electrodes themselves are relatively inconspicuous on spin-echo images (Fig 8A), and require gradient-echo imaging to be more clearly seen (Fig 8B).

Patients who received older models of auditory brain stem implants must be studied with CT rather than MR imaging. Artifacts caused by electrodes hinder assessment of CT scans by blurring the relationship between electrodes and soft-tissue anatomy. To avoid this problem, a thin section of the electrode array may be processed with an edge-enhancement

algorithm and is then black-white reversed and superimposed on the soft-tissue image of the same section (52).

Conclusion

Imaging is indispensable to the preoperative and postoperative evaluation of patients with cochlear and brain stem implants. While auditory brain stem implants are still investigational, cochlear implants are now well accepted and widely used. When imaging candidates for cochlear implants, radiologists must be able to produce excellent CT scans that show cochlear ossification and nerve agenesis as well as depict cochlear malformations and various degrees of incidental abnormalities that may complicate surgery.

References

1. Balkany T. A brief perspective on cochlear implants. *N Engl J Med* 1993;328:281–282
2. Brackmann DE, Hitselberger WE, Nelson RA, et al. Auditory brainstem implant: I. Issues in surgical implantation. *Otolaryngol Head Neck Surg* 1993;108:624–633
3. Luxford WM, Brackmann DE. The history of cochlear implants. In: Gray RF, ed. *Cochlear Implants* London, England: Croom Helm; 1985:1–26
4. NIH Consensus Development Panel. Cochlear implants in adults and children. *JAMA* 1995;274:1955–1961
5. Johnson MH, Hasenstab MS, Seicshnaydre, William GH. CT of postmeningitic deafness: observations and predictive value for cochlear implants in children. *AJNR Am J Neuroradiol* 1995;16:103–109
6. Heller JW, Brackmann DE, Tucci DL, Nyenhuis JA, Chou C-K. Evaluation of MRI compatibility of the modified Nucleus multichannel auditory brain stem and cochlear implants. *Am J Otol* 1996;17:724–729
7. Balkany T, Gantz BJ, Steenerson RL, Cohen NL. Systematic approach to electrode insertion in the ossified cochlea. *Otolaryngol Head Neck Surg* 1991;114:4–11
8. Woolley AL, Oser AB, Lusk RP, Baohadori RS. Preoperative temporal bone computed tomography scan and its use in evaluating the pediatric cochlear implant candidate. *Laryngoscope* 1997;107:1100–1106
9. Young NM. Cochlear implants in children. *Curr Probl Pediatr* 1994;24:131–138
10. Youssefzadeh S, Baumgartner W, Gstöttner W, Imhof H. Cochlear implants: contraindication to MRI? American Roentgen Ray Society Program of the Ninety-Sixth Annual Meeting, San Diego, CA, May 5–10, 1996. Reston, VA: American Roentgen Ray Society; 1996:72
11. Portnoy WM, Mattucci K. Cochlear implants as a contraindication to magnetic resonance imaging. *Ann Otol Rhinol Laryngol* 1991;100:195–197
12. Chakeres DW, Spiegel PK. A systematic technique for comprehensive evaluation of the temporal bone by computed tomography. *Radiology* 1983;146:97–106
13. Daniels DL, Swartz JD, Harnsberger HR, Ulmer JL, Shaffer KA, Leighton M. Hearing, I: the cochlea. *AJNR Am J Neuroradiol* 1996;17:1237–1241

14. Schuknecht HF, Gulya AJ. *Anatomy of the Temporal Bone with Surgical Implications*. Philadelphia, PA: Lea & Febiger; 1986:3-34, 129-160
15. Becker TS, Eisenberg LS, Luxford WM, House WF. **Labyrinthine ossification secondary to childhood bacterial meningitis: implications for cochlear implant surgery.** *AJNR Am J Neuroradiol* 1984; 5:739-741
16. Swartz JD, Mandel DW, Faerber EN, et al. **Labyrinthine ossification: etiologies and CT findings.** *Radiology* 1985;157:395-398
17. Frau GN, Luxford WM, Lo WWM, Berliner KI, Telischi FF. **High-resolution computed tomography in evaluation of cochlear patency in implant candidates: a comparison with surgical findings.** *J Laryngol Otol* 1994;108:743-748
18. Green JD Jr, Marion MS, Hinojosa R. **Labyrinthitis ossificans: histopathologic consideration for cochlear implantation.** *Otolaryngol Head Neck Surg* 1991;104:320-326
19. Ketten D. **The role of temporal bone imaging in cochlear implants.** *Current Opinion in Otolaryngol Head Neck Surg* 1994;2:401-408
20. Balkany TJ, Dreisbach JN, Seibert CE. **Radiographic imaging of the cochlear implant candidate: preliminary results.** *Otolaryngol Head Neck Surg* 1986;95:592-597
21. Seeshnaydre MA, Johnson MH, Hazenstab MS, Williams GH. **Cochlear implants in children: reliability of computed tomography.** *Otolaryngol Head Neck Surg* 1992;107:410-417
22. Seidman DA, Chute PM, Parisier S. **Temporal bone imaging for cochlear implantation.** *Laryngoscope* 1994;104:562-565
23. Langman AW, Quigley SM. **Accuracy of high-resolution computed tomography in cochlear implantation.** *Otolaryngol Head Neck Surg* 1996;114:38-43
24. Novak MA, Fifer RC, Barkmeier JC, Firszt JB. **Labyrinthine ossification after meningitis: its implication for cochlear implantation.** *Otolaryngol Head Neck Surg* 1990;103:351-356
25. Linthicum FH Jr, Fayad J, Otto S, et al. **Inner ear morphologic changes resulting from cochlear implantation.** *Am J Otol* 1991; 12(Suppl):8-10
26. Hinojosa R, Green JD Jr, Marion MS. **Ganglion cell population in labyrinthitis ossificans.** *Am J Otol* 1991;12(Suppl):3-7
27. Slattery WH III, Luxford WM. **Cochlear implantation in the congenital malformed cochlea.** *Laryngoscope* 1995;105:1184-1187
28. Tucci DL, Telian SA, Zimmerman-Phillips S, Zwolan TA, Kileny RR. **Cochlear implantation in patients with cochlear malformations.** *Arch Otolaryngol Head Neck Surg* 1995;121:833-838
29. Jackler RK, Luxford WM, House WF. **Congenital malformation of the inner ear: a classification based on embryogenesis.** *Laryngoscope* 1987;97(Suppl 40):2-14
30. Urman SM, Talbot JM. **Otic capsule dysplasia: clinical and CT findings.** *Radiographics* 1990;10:823-838
31. Lemmerling MM, Mancuso AA, Antonelli PJ, Kubills PS. **Normal Modiolus: CT appearance in patients with a large vestibular aqueduct.** *Radiology* 1997;204:213-219
32. Phelps PD, King A, Michaels L. **Cochlear dysplasia and meningitis.** *Am J Otol* 1994;15:551-557
33. Silverstein H, Smouha E, Morgan N. **Multichannel cochlear implant in a patient with bilateral Mondini deformities.** *Am J Otol* 1988;9:451-455
34. Miyamoto RT, McConkey Robbins AJ, Myres WA, Pope ML. **Cochlear implantation in the Mondini inner ear malformation.** *Am J Otol* 1986;7:258-261
35. House Jr III, Luxford WM. **Facial nerve injury in cochlear implantation.** *Otolaryngol Head Neck Surg* 1993;109:1078-1082
36. Shelton C, Luxford WM, Tonokawa LL, Lo WWM, House WF. **The narrow internal auditory canal in children: a contraindication to cochlear implants.** *Otolaryngol Head Neck Surg* 1989;100:227-231
37. Arriaga MA, Marks S. **Simultaneous cochlear implantation and acoustic neuroma resection: imaging considerations, technique, and functional outcome.** *Otolaryngol Head Neck Surg* 1995;112:325-328
38. Hulka GF, Bernard EJ, Pillsbury HC. **Cochlear implantation in a patient after removal of an acoustic neuroma.** *Arch Otolaryngol Head Neck Surg* 1995;122:465-468
39. Laszig R, Terwey B, Battmer, RD, Hesse G. **Magnetic Resonance imaging (MRI) and high-resolution computer tomography (HRCT) in cochlear implant candidates.** *Scand Audiol* 1988;30:197-200
40. Marsot-Dupuch K, Chouard C, Falisse B, Meyer B, Tubiana JM. **Place of 3DFT-MR imaging study on cochlear implant candidates.** *Adv Otorhinolaryngol* 1993;48:23-28
41. Phelps PD. **Fast spin echo MRI in otology.** *J Laryngol Otol* 1994; 108:383-394
42. Marsh MA, Xu J, Blamey PJ, et al. **Radiologic evaluation of multichannel intracochlear implant insertion depth.** *Am J Otol* 1993; 14:386-391
43. Shpizner BA, Holliday RA, Roland JT, Cohen NL, Waltzman SB, Shapiro WH. **Postoperative imaging of the multichannel cochlear implant.** *AJNR Am J Neuroradiol* 1996;16:1517-1524
44. Niparko JK, Oviatt DL, Coker NJ, et al. **Facial nerve stimulation with cochlear implantation.** *Otolaryngol Head Neck Surg* 1991;104: 826-830
45. Muckle RP, Levine SC. **Facial nerve stimulation produced by cochlear implants in patients with cochlear otosclerosis.** *Am J Otol* 1994;15:394-398
46. Otto SR, Brackmann DE, Staller S, Menapace CM. **The multichannel auditory brainstem implant: 6-month coinvestigator results.** *Advances in Oto-Rhino-Laryngology* 1997;52:1-7
47. Laszig R, Sollmann WP, Marangos N, Charachon R, Ramsden R. **Nucleus 20-channel and 21-channel auditory brainstem implants: first European experience.** *Ann Otol Rhinol Laryngol* 1995; 104(Suppl 166):28-30
48. Gebarski SS, Tucci DL, Telian SA. **Cochlear nuclear complex: MR location and abnormalities.** *AJNR Am J Neuroradiol* 1993;14:1311-1318
49. Shannon RV, Fayad J, Moore J, et al. **Auditory brainstem implant: II. Postsurgical issues and performance.** *Otolaryngol Head Neck Surg* 1993;108:634-642
50. Oas JG, Baloh RW. **Vertigo and the anterior inferior cerebellar artery syndrome.** *Neurology* 1992;42:2274-2279
51. Linsky ME, Lunsford LD, Flickinger JC. **Neuroimaging of acoustic nerve sheath tumors after stereotactic radiosurgery.** *AJNR Am J Neuroradiol* 1991;12:1165-1175
52. Lo WWM, Tasaka A, Zink B, Harris O. **A simple CT method for location of auditory brain stem implant electrodes.** *AJNR Am J Neuroradiol* 1995;16:599-601