

Double Microcatheter Technique for Detachable Coil Treatment of Large, Wide-Necked Intracranial Aneurysms

Blaise W. Baxter, Dominic Rosso, and Stephen P. Lownie

Summary: We describe a technique used to treat two patients with large, wide-necked aneurysms during the past 2 years. In the initial attempts at embolization, evidence of coil instability within the aneurysm or significant impingement of coil loops on the parent artery was observed. Advancement of a second microcatheter into the aneurysm allowed two coils to be braced across the aneurysmal neck before the detachment of either coil. This technique permitted successful coil treatment in both patients.

Saccular occlusion of intracranial aneurysms with coils is a useful endovascular alternative to direct surgical clipping. The development of Guglielmi electrolytically detachable platinum coils (GDC, Target Therapeutics, Fremont, CA) represents a significant advance in preventing coil migration during embolization (1). To date, the aneurysms selected for treatment have largely been those in which surgery was unsuccessful or that were judged to be of high surgical risk (2–4).

As with aneurysms treated surgically, the most difficult to treat with coil embolization are those with a wide neck, defined as greater than 4 mm in diameter (5). The frequency of attaining complete aneurysmal occlusion has been shown to be much higher in small-necked aneurysms (3–5). In wide-necked aneurysms, complete coil filling is often technically difficult owing to the risks of distal coil migration or coil impingement on the parent vessel (2, 3). We describe two cases of wide-necked aneurysms in which two microcatheters were used for coil delivery. In both cases, the decision to attempt to advance a second microcatheter into the aneurysmal sac was made after observing coil instability within the aneurysm (coil helix too small) or significant impingement of coil loops on the parent artery (coil helix too large). This technique allowed us to brace two coils within the aneurysm and across its neck before detaching either coil.

Case Reports

Case 1

A 64-year-old woman experienced two syncopal episodes. CT and angiography showed a large, wide-necked aneurysm of the posterior communicating artery with atherosclerosis and ectasia of the underlying right internal carotid artery (ICA) (Fig 1A). At craniotomy, the width of the aneurysmal neck coupled with marked atherosclerosis of the ICA precluded safe clip placement. The patient subsequently underwent endovascular treatment on June 14, 1996. After placement of a 6F femoral artery sheath, a bolus of 3000 U of heparin was administered. A 6F guiding catheter was placed in the ICA with continuous infusion of 3000 U of heparin per 500 mL of saline. A Tracker 18 two-tip microcatheter (Target Therapeutics) was placed within the aneurysmal lumen. Two large coils (GDC-18 12-mm helix \times 30-cm length and a GDC-18 10-mm helix \times 30-cm length) were initially tried but removed because of impingement on the parent vessel (Fig 1B). A GDC-18 8-mm helix \times 30-cm length coil was satisfactorily positioned, but was observed to spin about within the aneurysmal sac (Fig 1C). At this point, a second femoral artery sheath was inserted on the opposite side, and a second microcatheter (Tracker 10, Target Therapeutics) was introduced via a second 6F guiding catheter and positioned within the aneurysm. A GDC-10 5-mm helix \times 15-cm length coil was deposited, which stabilized and braced the first coil within the aneurysm and across the neck (Fig 1D). Ultimately, eight coils with a total length of 108 cm were deposited, yielding satisfactory occlusion of the aneurysmal sac (Fig 1E). Heparin was not reversed. After the procedure, the patient experienced profound weakness in the left arm. Immediate angiography showed no evidence of branch vessel occlusion. Subsequent CT scans showed two small areas of infarction involving the right caudate and right frontal convexity regions. Clinically, the patient improved significantly and was able to return to her work as a bookkeeper; however, impairment of fine finger movement prevents her from typing. Angiographic follow-up 4 months after the procedure revealed coil compaction in the distal part of the neck (Fig 1F).

Case 2

A 59-year-old woman presented with grade III subarachnoid hemorrhage. Angiography showed a large, wide-necked basilar bifurcation aneurysm with incorporation of both posterior cerebral artery origins in the aneurysmal neck (Fig 2A). A small secondary lobule thought to be the site of bleeding was noted along the anterosuperior border of the aneurysm. Using sys-

Received June 6, 1997; accepted after revision September 18.

From the Departments of Diagnostic Radiology (B.W.B., D.R., S.P.L.) and Clinical Neurological Sciences (S.P.L.), University Campus, London Health Sciences Centre, The University of Western Ontario, London, Ontario, Canada.

Address reprint requests to Stephen P. Lownie, MD, FRCSC, Clinical Neurological Sciences, University Campus, London Health Sciences Centre, 339 Windermere Rd, London, Ontario, Canada N6A 5A5.

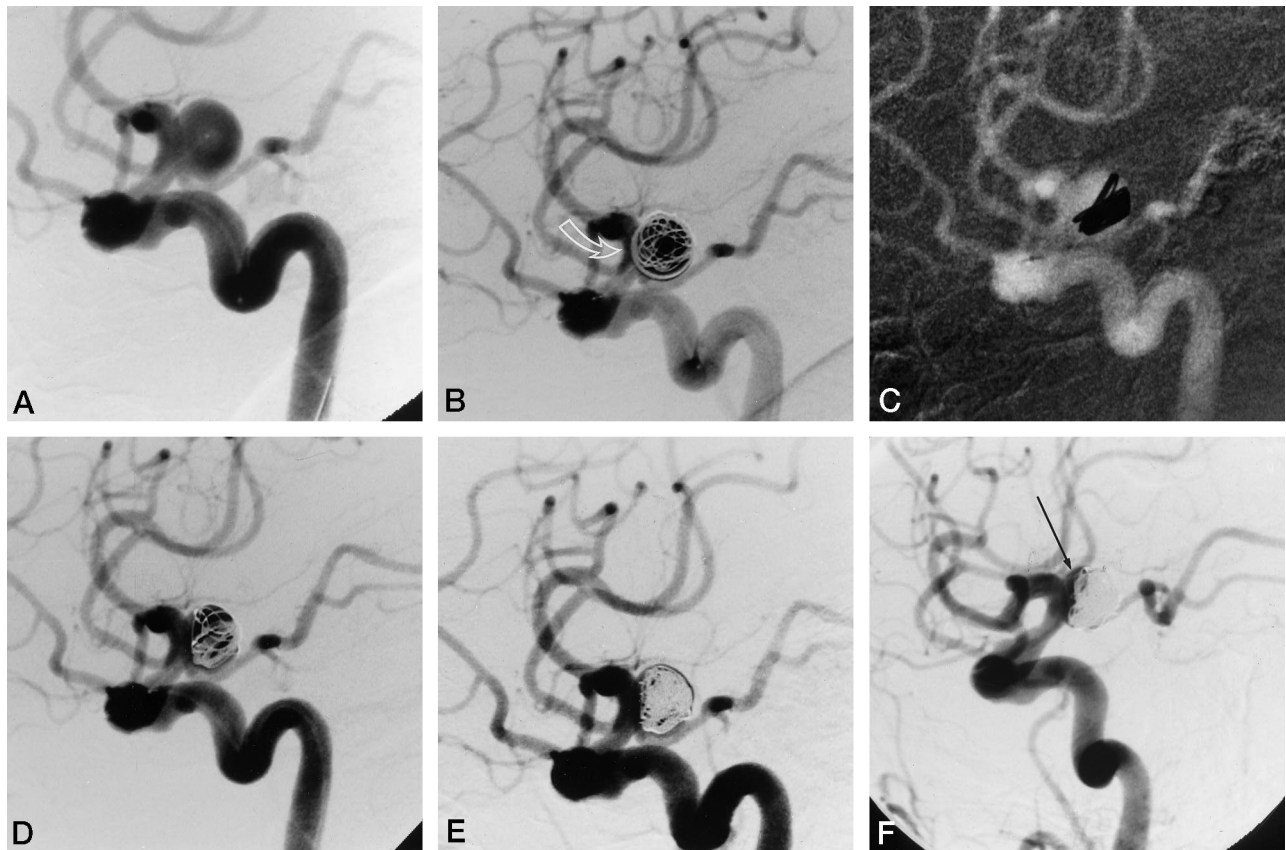


FIG 1. 64-year-old woman who had two syncopal episodes.

A, Right internal carotid angiogram, off-lateral view, shows a large, wide-necked aneurysm of the posterior communicating artery. The tip of a Tracker 18 microcatheter is seen in the aneurysmal sac.

B, GDC-18 10-mm helix \times 30-cm length coil is positioned but not detached. Note impingement on parent vessel (arrow). This coil was removed.

C, GDC-18 8-mm helix \times 30-cm length coil positioned. This coil was observed to spin about within the aneurysmal sac. Because of the potential for migration, the coil was left in place but not immediately detached.

D, A second microcatheter, Tracker 10, was inserted into the aneurysm. The addition of a GDC-10 5-mm helix \times 15-cm length coil through the second microcatheter braced the first coil within the aneurysm and across the neck.

E, Right internal carotid angiogram, off-lateral view, with the two microcatheters removed and eight coils deposited (total length, 108 cm), shows satisfactory aneurysmal occlusion.

F, Angiogram obtained 4 months after embolization shows minimal coil compaction at the distal neck (arrow).

temic heparinization with an initial bolus of 3000 U and intermittent boluses of 1000 U/h, we entered the aneurysmal sac with a Tracker-18 two-tip microcatheter advanced via a 6F guiding catheter placed in the left vertebral artery and inserted a GDC-18 12-mm helix \times 30-cm length coil. Despite multiple attempts, the coil could not be positioned without compromise of the parent vessel and branch origins by coil loops (Fig 2B). The coil was removed, and a GDC-18 8-mm helix \times 30-cm length coil was inserted. After a few attempts, this coil was positioned without compromising the parent vessel or posterior cerebral arteries (Fig 2C). Concerns regarding the stability of this coil led to the decision to delay detachment. A second arterial sheath was inserted into the opposite femoral artery and a second 6F guiding catheter was placed in the left vertebral artery. A more stable coil mesh was formed with a second coil inserted through a second microcatheter (Fig 2D). Nine coils with a total length of 130 cm were deposited before the original coil was detached. In all, 13 coils with a total length of 180 cm were placed in the aneurysm, resulting in satisfactory occlusion (Fig 2E). Further coils could not be positioned without herniation of loops across the posterior cerebral artery origins. With the bleeding site well protected, the procedure was terminated. Heparin was stopped but not reversed. The patient tolerated the procedure well and was discharged home, neurologically intact, 10 days after treatment.

Discussion

Large, wide-necked aneurysms are technically difficult to treat with endovascular coil therapy. Complete aneurysmal occlusion is often not achieved owing to the potential for parent vessel compromise or coil migration (2, 4, 5). The same concerns arise during the initial placement of a coil within such aneurysms. If the coil helix is too small relative to the size of the aneurysmal neck, there is a risk of coil migration. If the helix is too large, there is a risk of parent artery or branch artery occlusion.

The technique we have described is based on the concept of securely bracing coils beside one another to achieve a stable configuration. Placing two microcatheters within the aneurysm allowed two coils to be positioned and their stability assessed before either coil was detached. A side-by-side configuration of coils was fashioned across the orifice of the aneurysm. With coil loops bridging but not herniating through the aneurysmal neck, a lattice was formed for the safe deposition of subsequent coils.

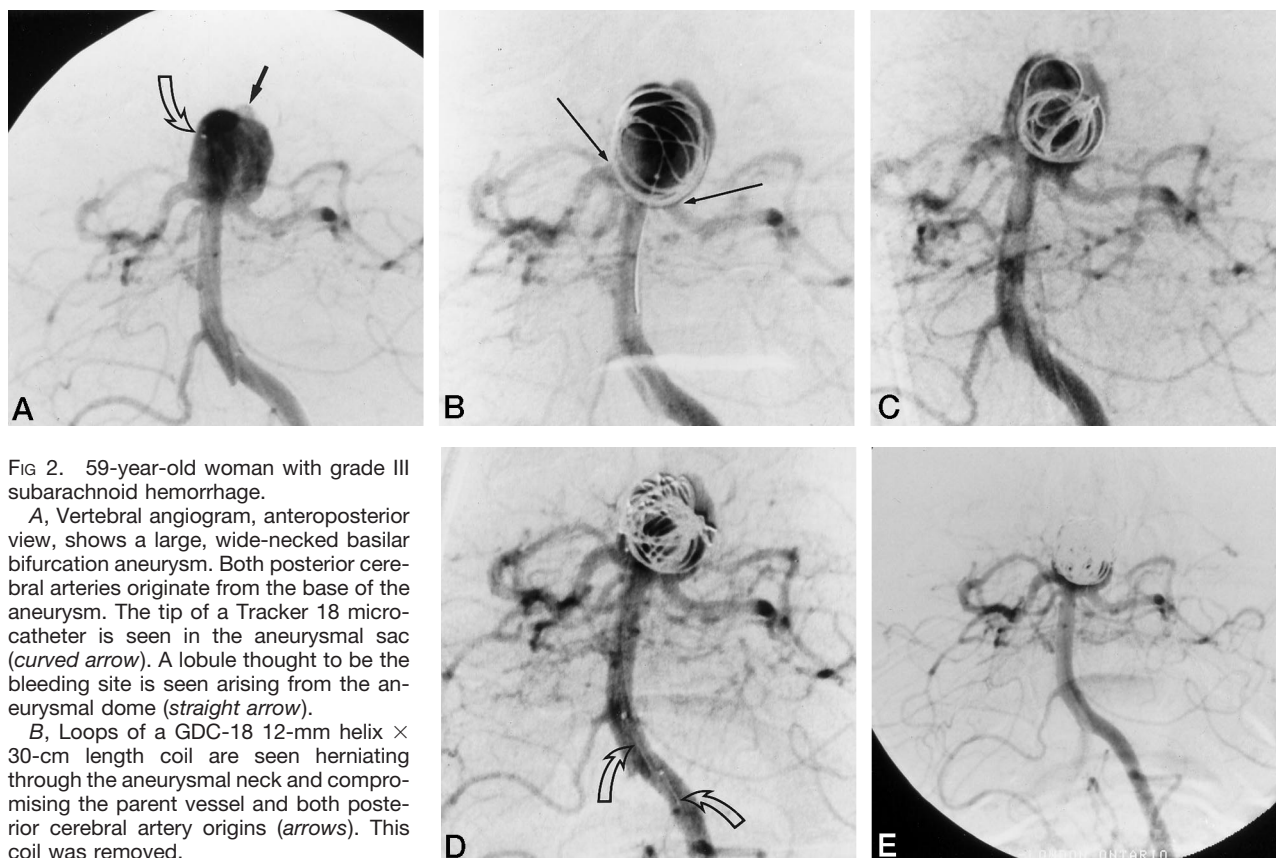


FIG 2. 59-year-old woman with grade III subarachnoid hemorrhage.

A, Vertebral angiogram, anteroposterior view, shows a large, wide-necked basilar bifurcation aneurysm. Both posterior cerebral arteries originate from the base of the aneurysm. The tip of a Tracker 18 microcatheter is seen in the aneurysmal sac (*curved arrow*). A lobule thought to be the bleeding site is seen arising from the aneurysmal dome (*straight arrow*).

B, Loops of a GDC-18 12-mm helix \times 30-cm length coil are seen herniating through the aneurysmal neck and compromising the parent vessel and both posterior cerebral artery origins (*arrows*). This coil was removed.

C, GDC-18 8-mm helix \times 30-cm length coil is positioned but not detached (owing to stability concerns) without compromising the parent or branch vessel.

D, Two microcatheters are seen (*arrows*) and a more stable coil configuration has been achieved with the addition of a second coil inserted through the second Tracker 18 microcatheter.

E, Vertebral angiogram, anteroposterior view, shows 13 detached coils (total length, 180 cm), yielding satisfactory aneurysmal occlusion without parent or branch vessel impingement. The likely rupture site is well protected.

Other methods have been described for securing coil placement in wide-necked aneurysms (6, 7). Primarily, these include the use of a nondetachable balloon placed across the orifice of the aneurysm to prevent coil migration. The risks of this method have been outlined by others and include dissection and thromboembolic phenomena (6, 7). Temporary vessel occlusion may also increase the risk of distal ischemic events, and there is an increased risk of aneurysmal rupture due to the compressive forces generated by balloon inflation (6).

Wide-necked aneurysms alone may present an increased risk of thromboembolism during detachable coil treatment (7). The introduction of a second microcatheter for coil delivery is not only more technically demanding but probably increases the risk of thromboembolic complications. Safeguards, including systemic heparinization and the use of continuous catheter infusions, should be considered.

Conclusion

The double microcatheter technique may be helpful when there is evidence of coil instability or parent vessel compromise during embolization of large, wide-necked aneurysms. The increased technical demands and potential for complications necessitate

that clear indications be present before this adjunctive technique is considered.

Acknowledgment

We thank Cathy Lockhart for her dedicated transcription of the manuscript.

References

- Guglielmi G, Vinuela F, Sepetka I, Macellari V. **Electrothrombosis of saccular aneurysms via endovascular approach, 1: electrochemical basis, technique, and experimental results.** *J Neurosurg* 1991;75:1-7
- Guglielmi G, Vinuela F, Duckwiler G, et al. **Endovascular treatment of posterior circulation aneurysms by electrothrombosis using electrically detachable coils.** *J Neurosurg* 1992;77:515-524
- McDougall CG, Halbach VV, Dowd CF, Higashida RT, Larsen DW, Hieshima GB. **Endovascular treatment of basilar tip aneurysms using electrolytically detachable coils.** *J Neurosurg* 1996;84:393-399
- Vinuela F, Duckwiler G, Mawad M. **Guglielmi detachable coil embolization of acute intracranial aneurysm: perioperative anatomical and clinical outcome in 403 patients.** *J Neurosurg* 1997;86:475-482
- Zubillaga AF, Guglielmi G, Vinuela F, Duckwiler GR. **Endovascular occlusion of intracranial aneurysms with electrically detachable coils: correlation of aneurysm neck size and treatment results.** *AJNR Am J Neuroradiol* 1994;15:815-820
- Moret J, Cognard C, Weill A, Castaing L, Rey A. **The "remodeling technique" in the treatment of wide neck intracranial aneurysms.** *Intervent Neuroradiol* 1997;3:21-35
- Levy DI, Ku A. **Balloon-assisted coil placement in wide-necked aneurysms (technical note).** *J Neurosurg* 1997;86:724-727