

Are your **MRI contrast agents** cost-effective?

Learn more about generic **Gadolinium-Based Contrast Agents**.



**FRESENIUS
KABI**

caring for life

AJNR

MR sialography in patients with Sjögren syndrome.

H Tonami, Y Ogawa, M Matoba, Y Kuginuki, H Yokota, K Higashi, T Okimura, I Yamamoto and S Sugai

AJNR Am J Neuroradiol 1998, 19 (7) 1199-1203

<http://www.ajnr.org/content/19/7/1199>

This information is current as of April 17, 2024.

MR Sialography in Patients with Sjögren Syndrome

Hisao Tonami, Yoshimi Ogawa, Munetaka Matoba, Yasuaki Kuginuki, Hajime Yokota, Kotaro Higashi, Tetsuro Okimura, Itaru Yamamoto, and Susumu Sugai

PURPOSE: The purpose of this study was to evaluate the effectiveness of MR sialography of the parotid gland ducts in the diagnosis and staging of Sjögren syndrome.

METHODS: MR imaging was performed on a 1.5-T unit with a neck phased-array coil. MR sialographic source images were obtained using a heavily T2-weighted fast spin-echo sequence with spectral fat suppression. All images were analyzed on the basis of maximum intensity projection reconstruction. Five healthy control subjects and 51 patients with definite Sjögren syndrome (43 with primary disease and eight with secondary disease) were examined with MR sialography. A labial gland biopsy was performed in all patients and histopathologic grading was done by means of focal scores. The findings of MR sialography were compared with the results of labial gland biopsy to determine the effectiveness of the technique in the diagnosis and staging of Sjögren syndrome.

RESULTS: In all five control subjects, the main duct and the primary branching ducts of the parotid glands were clearly visible on MR sialographic images. In patients with Sjögren syndrome, a punctate, globular, cavitary, or destructive appearance was well seen within the parotid glands. Findings obtained at MR sialography correlated well with the results of labial gland biopsy.

CONCLUSION: MR sialography has the potential to produce diagnostic findings in the parotid gland ducts of patients with Sjögren syndrome. Our results suggest that this method will augment and possibly replace X-ray sialography.

Sjögren syndrome is a chronic inflammatory disorder of the exocrine glands. It is characterized by keratoconjunctivitis sicca and xerostomia, which result from dysfunction of the lacrimal and salivary glands (1). Sjögren syndrome is frequently associated with other autoimmune diseases, such as rheumatoid arthritis and systemic lupus erythematosus (2). Whereas keratoconjunctivitis can be diagnosed by the application of rose bengal or fluorescein dye into each eye, the assessment of xerostomia is more difficult. And although the Saxon test provides a reliable oral screening counterpart to the Schirmer test, no satisfactory results can be obtained to detect characteristic salivary gland abnormalities (3).

Imaging studies that have been used for the diagnosis of Sjögren syndrome include X-ray sialography, radionuclide scintigraphy, sonography, and CT (4–7). Among these, X-ray sialography is considered the standard of reference in the imaging diagnosis and staging of this disease, because abnormal sialographic findings imply definite underlying pathologic changes (4). However, this procedure requires cannulation of the ducts, which cannot always be achieved. Furthermore, retrograde injection of contrast material may exacerbate the underlying inflammatory process and cause the patient discomfort or pain (5, 8).

MR imaging has been widely used for demonstrating parenchymal lesions in the salivary glands (9, 10), but only a few studies have focused on the internal structure of the salivary glands (11). Recently, Lomas et al (12) described a method of MR sialography using a heavily T2-weighted rapid acquisition with relaxation enhancement (RARE) projection technique for imaging the major salivary gland ducts. Although this technique can be performed in a short time, the substantial projection thickness may limit its ability to show the subtle duct abnormalities that accompany Sjögren syndrome. Different techniques that use heavily T2-weighted two- or three-dimen-

Received October 14, 1997; accepted after revision January 22, 1998.

Supported in part by a Research Project Program P95–2 from Kanazawa Medical University.

From the Departments of Radiology (H.T., M.M., Y.K., H.Y., K.H., T.O., I.Y.) and Hematology and Immunology (Y.O., S.S.), Kanazawa Medical University, Ishikawa, Japan.

Address reprint requests to Hisao Tonami, MD, Department of Radiology, Kanazawa Medical University, Daigaku1–1, Uchinada, Kahoku, Ishikawa, 920–02, Japan.

sional fast spin-echo (SE) sequences have been described for imaging the biliary or pancreatic ducts (13–15).

We used a 2-D fast SE MR sialographic technique with a phased-array coil and a 512 matrix to examine the abnormal parotid gland ducts in patients with Sjögren syndrome. We then compared the findings at MR sialography with the results of labial gland biopsy to determine the effectiveness of the technique for diagnosis and staging of Sjögren syndrome.

Methods

Study Population

The study population was composed of five healthy control subjects (15 to 32 years old; mean age, 21 years) and 51 patients with definite Sjögren syndrome (42 women, 22 to 78 years old; mean age, 56 years). We ascertained by inquiry that the volunteers had no history of disease or of medical treatment that would affect the salivary glands. Of the 51 patients, 43 had primary Sjögren syndrome and the other eight had secondary disease associated with rheumatoid arthritis ($n = 3$), systemic lupus erythematosus ($n = 3$), dermatomyositis ($n = 1$), and mixed connective tissue disease ($n = 1$). All patients had signs and symptoms that met the criteria for diagnosis of Sjögren syndrome, as defined by the Sjögren Disease Research Committee of the Japanese Ministry of Health and Welfare (16); that is, the patient must have overt sicca of unknown origin, plus one or more of the following three signs: 1) keratoconjunctivitis sicca with a positive Schirmer test (<10 mm of wetting in 5 minutes) and increased staining with rose bengal dye; 2) characteristic histologic findings at biopsy of the lacrimal or salivary gland, including at least one periductal focal aggregate of 50 or more mononuclear cells per lobe; and 3) positive sialographic features with the presence of sialectasia.

MR Sialography

MR sialography was performed on a 1.5-T imager with a neck phased-array coil. Initially, a single-shot RARE image was obtained in the axial plane. Imaging parameters for the single-shot RARE sequence were as follows: echo space = 11.5 milliseconds, $TR_{\text{eff}} = 1200$, section thickness = 30 to 40 mm, field of view (FOV) = 200 mm, matrix = 256×256 , number of acquisitions = 1, and acquisition time = 6 seconds. Using this axial RARE image as a localizer, we determined the oblique sagittal image plane necessary to cover the whole course of the parotid gland duct, since the duct has a small C-shaped curve anteriorly as it bends around the masseter muscle (Fig 1). MR sialographic source images were then obtained with a 2-D fast SE sequence using the following parameters: 9500/259/4 ($TR/TE_{\text{eff}}/\text{excitations}$), number of echoes for each excitation = 27, section thickness = 2 mm with no intersection gap, number of sections acquired = 18, FOV = 170 mm, matrix = 290×512 , and acquisition time = 6 minutes 45 seconds. A fat-saturation pulse was used in this sequence. All images generated were analyzed on the basis of maximum intensity projection (MIP) reconstruction.

MR Sialographic Staging

The MR sialographic stages of Sjögren syndrome were determined according to the criteria of X-ray sialography proposed by Rubin and Holt (4), in which stage 0 = normal. Stage 1 = punctate: this is the earliest stage, in which diffuse, spherical areas of high signal intensity, 1 mm or less in diameter and uniform in size, are distributed evenly throughout the gland. Stage 2 = globular: in this stage of the disease, the spherical areas of high signal intensity increase to 1 to 2 mm in diameter.

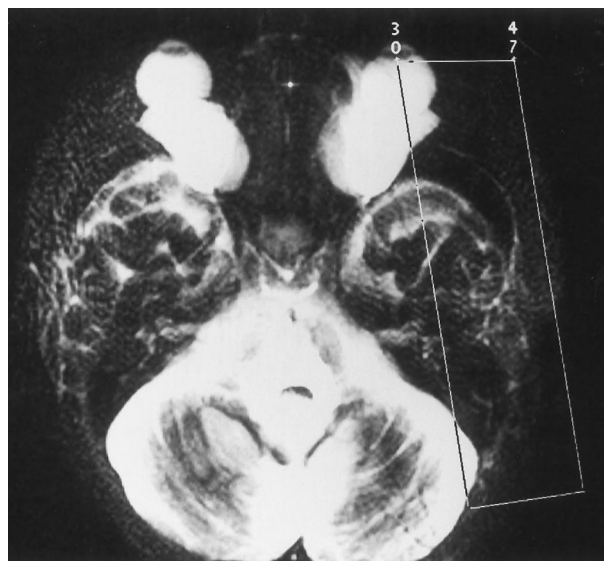


FIG 1. Axial single-shot RARE image shows the imaging slab for MR sialography. The whole course of the parotid gland duct on left is included in this imaging slab.

Stage 3 = cavitary: with further disease progression, the areas of high signal intensity coalesce and enlarge further, up to 1 cm in diameter, becoming irregular in size and distribution and decreasing in number. Stage 4 = destructive: this represents the end stage of the disease, in which there is a marked dilatation of the main duct with an irregular diameter. MR sialographic staging of the cases was performed independently by two reviewers who were blinded to the clinical parameters, to the results of the imaging tests, and to the final diagnosis. The staging assessments made by each reviewer were tested for interobserver agreement, and any discrepancies were resolved by consensus.

Labial Gland Biopsy

In all 51 patients with Sjögren syndrome, minor salivary glands were excised through mucosa of the lower lip within a week after MR examination. Focal scores were determined on the basis of a focal aggregate of 50 lymphocytes per 4 mm^2 of salivary gland tissue without signs of atrophy or fibrosis, with a focal score of 1 or more considered abnormal (17–19).

Statistical Analysis

To compare the MR sialographic staging and the focal score obtained from the labial gland biopsy sample, we used one-way analysis of variance. Differences in the average focal score among the MR sialographic stages were then compared by use of Fisher's protect least significant difference test. A difference in results with a P value of less than .05 was considered statistically significant. Finally, agreement between the reviewers in the staging of Sjögren syndrome was evaluated by using the κ statistic (20). Strength of agreement was classified as slight ($\kappa \leq 0$ to 0.2), fair ($\kappa \leq 0.21$ to 0.4), moderate ($\kappa \leq 0.41$ to 0.6), substantial ($\kappa \leq 0.61$ to 0.8), and excellent ($\kappa \leq 0.81$ to 1.00).

Results

In the healthy volunteers, the main duct and primary branching ducts within the parotid gland were clearly seen in all cases (Fig 2). Twenty-three of the patients with Sjögren syndrome had normal findings (stage 0) and the remaining 28 had abnormal findings

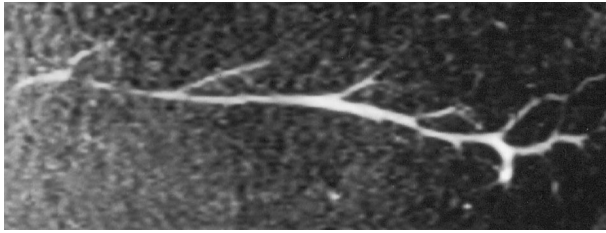


FIG 2. MR sialogram of the normal parotid gland duct in a healthy volunteer. Main duct and intraglandular ducts are well seen.

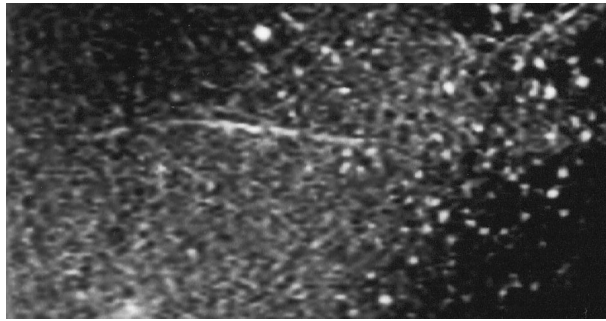


FIG 3. MR sialogram in a 11-year-old girl with primary Sjögren syndrome. Diffuse areas of punctate high signal intensity 1 mm or less in diameter are distributed throughout the duct (stage 1, punctate appearance). Focal score of this patient was 2.1.

at MR sialography: in 10 patients, the glands had a punctate appearance (stage 1) (Fig 3), in nine a globular appearance (stage 2) (Fig 4), in six a cavitary appearance (stage 3) (Fig 5), and in three a destructive appearance (stage 4) (Fig 6). Of the 23 patients who had normal findings at MR sialography (stage 0), 16 proved to have a focal score of 1 or less and the other seven had abnormal histopathologic findings with a focal score of more than 1. The average focal score in stage 0 was 0.79 ± 1.23 (mean \pm SD). All 28 patients who had abnormal findings on MR sialograms had a focal score of more than 1. The average focal score was 3.24 ± 2.71 in patients with stage 1 disease, 6.82 ± 3.60 in those with stage 2, 7.92 ± 2.73

in those with stage 3, and 11.00 ± 2.96 in those with stage 4. There was a high correlation between MR sialographic stage and focal score ($P < .0001$) (Fig 7). A statistically significant difference in the average focal score was found between stage 0 and stage 1 ($P = .0091$), stage 0 and stage 2 ($P < .0001$), stage 0 and stage 3 ($P < .0001$), stage 0 and stage 4 ($P < .0001$), stage 1 and stage 2 ($P = .0019$), stage 1 and stage 3 ($P = .0004$), stage 1 and stage 4 ($P < .0001$), and stage 2 and stage 4 ($P = .0112$) (Table). On the other hand, there was no significant difference in the average focal score between stage 2 and stage 3 ($P = .3860$) and between stage 3 and stage 4 ($P = .0726$). Interobserver agreement in staging of disease was 0.804 and the κ value was 0.727 (substantial).

Discussion

Criteria for diagnosis of Sjögren syndrome have evolved over the years from initial descriptions based on clinical findings (1) to more recent criteria sets based on a combination of clinical, serologic, and histopathologic findings (17). Salivary gland involvement in Sjögren syndrome is usually confirmed by X-ray sialography or labial gland biopsy (4, 18, 19). Although these two procedures offer accurate diagnosis, their usefulness as screening tests is hampered because both require invasive techniques. Imaging studies, including radionuclide scintigraphy, sonography, CT, and MR imaging, are noninvasive and are now widely used to evaluate various diseases of the salivary glands. These imaging studies, however, provide insufficient data for accurately diagnosing and staging Sjögren syndrome, because while they address the detection and diagnosis of parenchymal diseases of salivary glands they do not assess salivary gland duct abnormalities (5–7, 21–23). The MR sialographic technique presented here relies on a heavily T2-weighted pulse sequence with spectral fat suppression. Two-dimensional multisectional data were acquired and postprocessed by MIP reconstruction. As

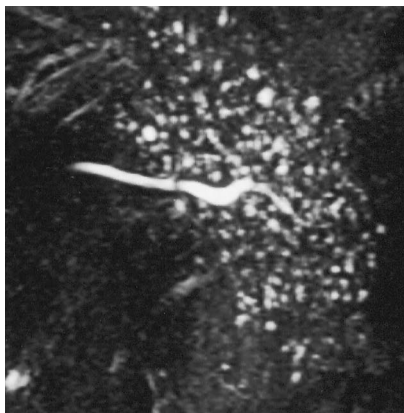


FIG 4. MR sialogram in a 43-year-old woman with primary Sjögren syndrome. Areas of spherical high signal intensity 1 to 2 mm in diameter are evident (stage 2, globular appearance). Focal score of this patient was 5.1.

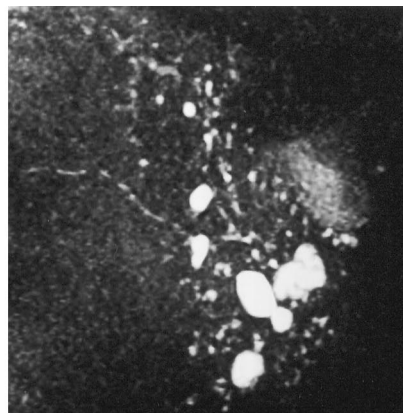


FIG 5. MR sialogram in a 65-year-old man with primary Sjögren syndrome. Large and irregular areas of high signal intensity up to 1 cm in diameter are noted (stage 3, cavitary appearance). Focal score of this patient was 4.5.

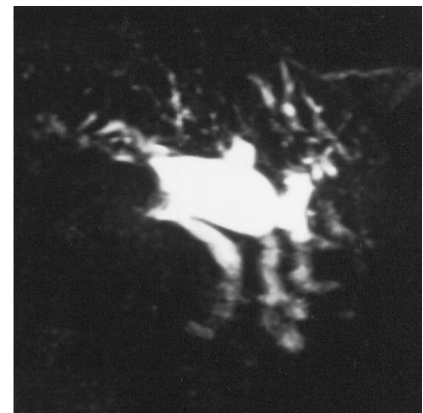


FIG 6. MR sialogram in a 67-year-old woman with primary Sjögren syndrome. The main duct shows marked dilatation and irregular branching (stage 4, destructive appearance). Focal score of this patient was 7.6.

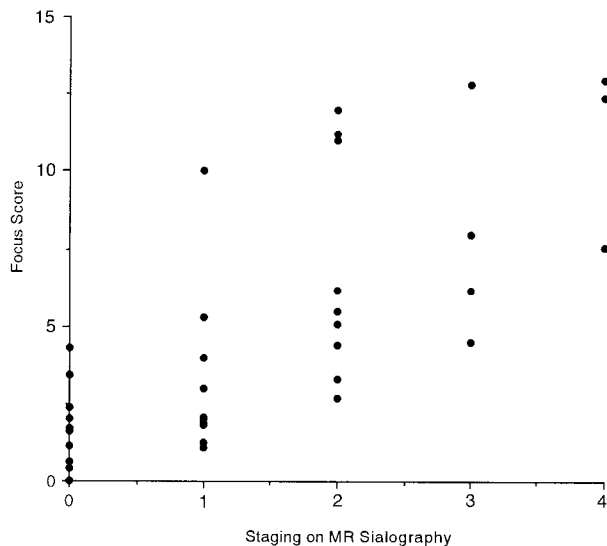


Fig 7. Comparison of MR sialographic stage and focal score.

Statistical significance of stage comparisons

Comparison	P Value
Stage 0 and stage 1	.0091
Stage 0 and stage 2	<.0001
Stage 0 and stage 3	<.0001
Stage 0 and stage 4	<.0001
Stage 1 and stage 2	.0019
Stage 1 and stage 3	.0004
Stage 1 and stage 4	<.0001
Stage 2 and stage 3	.3860
Stage 2 and stage 4	.0112
Stage 3 and stage 4	.0726

a result, stationary fluids within the parotid gland duct could be seen to have a high signal intensity while solid organs had a low signal intensity. In addition, flowing blood had little or no measurable signal. This combination of imaging characteristics provides optimal contrast between the hyperintense signal of the fluid-filled parotid gland duct and the hypointense signal of background tissue (14).

Recently, Lomas et al (12) reported a method of MR sialography that uses a projection technique. This projection technique can be performed in a short time and requires no postprocessing apart from imaging reconstruction; however, it has several potential disadvantages. On images acquired with a substantial section thickness, veins with slow-flowing blood are seen more frequently and superimposed on MR sialographic images. In addition, the image contrast produced by the projection technique is theoretically inferior to that on MIP images, which are acquired with a multisection technique (14). Variable degrees of blurring artifacts are always seen, especially at great projection thicknesses. Furthermore, the projection technique achieves relatively low spatial resolution, and the thick sections limit the ability to detect subtle duct abnormalities. On the other hand, our imaging technique achieved high spatial resolution

(0.58×0.33 -mm pixel size) with the use of a 512 matrix, enough to depict the subtle duct abnormalities of Sjögren syndrome. This high spatial resolution was obtained through the use of a phased-array coil, which improved signal-to-noise ratio. Our imaging technique, however, has several disadvantages. With MIP reconstruction, much of the information on individual source images may be lost when a whole volume is displayed (14). Pitfalls and potential errors can result when only reconstructed images are used for interpretation. Therefore, in situations in which it is difficult to determine the MR sialographic stage, it is critical to rely on individual source images for interpretation. The use of 2-D multisection data acquisition causes anisotropic spatial resolution with increased section thickness (2 mm) as compared with in-plane resolution, resulting in marked degradation of MIP-reconstructed images in planes oblique to the acquisition plane (15). This problem may be alleviated considerably with the use of a 3-D fast SE sequence, now commercially available, which provides thin, contiguous sections of less than 1 mm, further improving spatial resolution in the section-select direction without the loss in signal-to-noise ratio (13).

Although X-ray sialography is still the standard of reference in the evaluation of Sjögren syndrome, MR sialography has several advantages over this technique (12), including the absence of any requirement to cannulate the duct and the lack of ionizing radiation. The technique can be used to examine a patient rapidly, and multiple MIP images can be reconstructed in any desired plane, allowing one to find the optimal imaging plane for the most accurate assessment. The examination is not contraindicated by the presence of infection and may be combined with conventional MR imaging to exclude any parenchymal mass lesion. Finally, the technique does not rely on any manual skill related to cannulation and it has been implemented on a widely available conventional MR system.

This study has shown that MR sialography is capable of depicting the subtle changes that take place in the parotid gland ducts of patients with Sjögren syndrome. Specific findings of numerous cystic changes within the glands were easily identified on MR sialograms. Although we did not directly compare the histologic findings in the parotid gland with the findings at MR sialography, we believe that the cystic changes seen on MR sialograms represented dilated intraglandular ducts. Histopathologic changes seen in the parotid glands of patients with Sjögren syndrome are composed of aggregates of lymphocytes, collagenous fibrous tissues, and dilated intraglandular ducts (21). Among these, the dilated ductal systems should be hyperintense on T2-weighted images; on the other hand, collagenous tissues and lymphocytes will appear hypointense on T2-weighted images. A statistically significant difference in the average focal score was found between each of the MR sialographic stages except between stages 2 and 3 and between stages 3 and 4. These results suggest that the changes seen on MR sialograms in patients with Sjögren syn-

drome precisely reflect progression of the disease from its early stages.

We usually perform MR sialography in patients with clinical symptoms suggestive of Sjögren syndrome and in those with known Sjögren syndrome for the evaluation of disease progression. We believe that the use of MR sialography to document and stage parotid gland duct abnormalities in these cases is worthwhile for the purpose of constructing an adequate therapeutic plan. This is particularly important for long-term follow-up, since most of these patients face a long future of disease progression.

Conclusion

We used a 2-D fast SE MR sialographic technique with high-resolution parameters for the diagnosis and staging of Sjögren syndrome. Our results suggest that this method represents a sensitive diagnostic indicator of Sjögren syndrome and may replace X-ray sialography in the evaluation of this disorder.

Acknowledgments

We thank Shuguang Hu for advice on statistical analysis, and Mikiko Hiromatsu for secretarial assistance.

References

- Bloch KJ, Buchanan WW, Wohl MJ, Bunim JJ. **Sjögren's syndrome: a clinical, pathological and serological study of sixty-two cases.** *Medicine* 1965;44:187-231
- Fox RI, Howell FV, Bone RC, et al. **Primary Sjögren syndrome: clinical and immunopathologic features.** *Semin Arthritis Rheum* 1984;2:77-105
- Kohler P, Winter M. **A quantitative test for xerostomia.** *Arthritis Rheum* 1985;28:1128-1132
- Rubin P, Holt JF. **Secretory sialography in diseases of the major salivary glands.** *AJR Am J Roentgenol* 1957;77:575-598
- de Clerck LS, Corthouts R, Franx L, et al. **Ultrasonography and computer tomography of the salivary glands in the evaluation with Sjögren's syndrome: comparison with parotid sialography.** *J Rheumatol* 1988;15:1777-1781
- Kawamura H, Taniguchi N, Itoh K, Kano S. **Salivary gland echography in patients with Sjögren's syndrome.** *Arthritis Rheum* 1990;33:505-510
- Nakamura T, Oshiumi Y, Yonetsu T, Muranaka K, Sakai K, Kanda S. **Salivary SPECT and factor analysis in Sjögren's syndrome.** *Acta Radiol* 1991;32:406-410
- Cockrell DJ, Rout PGJ. **An adverse reaction following sialography.** *Dentomaxillofac Radiol* 1993;22:41-42
- Teresi LM, Lufkin RB, Wortham DG, et al. **Parotid gland: plain and gadolinium enhanced MR imaging.** *Radiology* 1990;177:674-677
- Freling NS, Molenaar WM, Vermey A. **Malignant parotid tumors: clinical use of MR imaging and histological correlation.** *Radiology* 1992;185:691-695
- Thibault F, Halimi P, Bely N, et al. **Internal architecture of the parotid gland at MR imaging: facial nerve or ductal system?** *Radiology* 1993;188:701-704
- Lomas DJ, Carroll NR, Johnson G, Antoun NM, Freer CEL. **MR sialography.** *Radiology* 1996;200:129-133
- Reinhold C, Bret PM. **Current status of MR cholangiopancreatography.** *AJR Am J Roentgenol* 1996;166:1285-1295
- Yamashita Y, Abe Y, Tang Y, Urata J, Sumi S, Takahashi M. **In vitro and clinical studies of image acquisition in breath-hold MR cholangiopancreatography: single-shot projection technique versus multislice technique.** *AJR Am J Roentgenol* 1997;168:1449-1454
- Bret PM, Reinhold C, Taourel P, Guibaud L, Atri M, Barkun AN. **Pancreas divisum: evaluation with MR cholangiopancreatography.** *Radiology* 1996;199:99-103
- Ohfuji T. **Summary of the studies on Sjögren's disease in 1977.** In: *Annual report of the Ministry of Health and Welfare: Sjögren's Disease Research Committee.* Tokyo: Ministry of Health and Welfare, Japan; 1977:3-6
- Fox RI, Robinson CA, Curd JG, Kozin F, Howell FV. **Sjögren's syndrome: proposed criteria for classification.** *Arthritis Rheum* 1986;29:577-585
- Daniels TE. **Labial gland biopsy in Sjögren's syndrome: assessment as a diagnostic criterion in 362 suspected cases.** *Arthritis Rheum* 1984;27:147-156
- Wise CM, Woodruff RD. **Minor salivary gland biopsies in patients investigated for primary Sjögren's syndrome: a review of 187 patients.** *J Rheumatol* 1993;120:1515-1518
- Landis JR, Koch GG. **The measurement of observer agreement for categorical data.** *Biometrics* 1977;33:159-174
- Spath M, Kruger K, Dresel S, Grevers G, Vogl T, Schattenkirchner M. **Magnetic resonance imaging of the parotid gland in patients with Sjögren's syndrome.** *J Rheumatol* 1991;18:1372-1378
- Takashima S, Takeuchi N, Morimoto S, et al. **MR imaging of Sjögren syndrome: correlation with sialography and pathology.** *J Comput Assist Tomogr* 1991;15:393-400
- Izumi M, Eguchi K, Ohki M, et al. **MR imaging of the parotid gland in Sjögren's syndrome: a proposal for new diagnostic criteria.** *AJR Am J Roentgenol* 1996;166:1483-1487

Please see the Editorial on page 1183 in this issue.