

## Frequency and Significance of a Small Distal ICA in Carotid Artery Stenosis

James E. Dix, Brian J. McNulty, and David F. Kallmes

**PURPOSE:** Accurate calculation of the percentage of stenosis is crucial for identifying candidates for endarterectomy. Our goal was to quantify the reduction in diameter of the distal internal carotid artery (ICA) as a function of proximal ICA stenosis and to discuss the implications of distal ICA narrowing on the calculation of percentage of stenosis using the criteria of the North American Symptomatic Carotid Endarterectomy Trial (NASCET).

**METHODS:** We retrospectively reviewed the carotid angiograms of 81 patients referred for evaluation of carotid stenosis. The caliber of the ICA stenosis and the diameters of the normal distal ICA, the common carotid artery, and the internal maxillary artery were remeasured with precision calipers. The percentage of stenosis derived from the NASCET criteria were compared with vessel diameter and with the difference in size of the ipsilateral and contralateral distal ICAs. We then recalculated the percentage of stenosis by substituting the presumed normal contralateral distal ICA diameter for the ipsilateral distal ICA diameter.

**RESULTS:** In carotid arteries without significant stenosis (<70%), the distal ICA diameter measured  $5.94 \pm 1.10$  mm, but in vessels with severe stenosis (>70%), the distal ICA diameter measured  $4.69 \pm 1.23$  mm. After recalculation, four of 26 vessels were upgraded in classification from moderate (40% to 69%) to severe (>70%) stenosis.

**CONCLUSION:** The diameter of the distal ICA begins to decrease when the proximal stenosis is 60% or greater. If the ICA distal to a stenosis is smaller than the contralateral ICA, recalculating the percentage of stenosis by substituting measurements of the contralateral distal ICA diameter may be warranted.

Stroke remains the third leading cause of death and a major cause of disability in the United States, with atherosclerotic stenosis of the carotid bifurcation accounting for a large percentage of cerebral infarcts. The benefits of carotid endarterectomy have been shown for symptomatic patients with a stenosis of 70% or greater who were enrolled in the North American Symptomatic Carotid Endarterectomy Trial (NASCET) and, more controversially, for asymptomatic patients with a stenosis of 60% or greater who were enrolled in the Asymptomatic Carotid Atherosclerosis Study (ACAS) (1, 2). A percentage of stenosis greater than 70% by catheter angiography was the sole criterion for entry into the NASCET trial. In the ACAS trial, the criterion used

was a percentage of stenosis greater than 60% by catheter angiography or, when carotid Doppler sonography was used, a more than 95% positive predictive value of greater than 60% stenosis as compared with angiographic findings. Carotid Doppler sonography must be referenced to an anatomic study, such as catheter angiography, since Doppler velocity measurements alone do not indicate percentage of stenosis. Because carotid endarterectomy is performed on the basis of the anatomic measurement of the percentage of stenosis, the reliability of this measurement should be high.

Although the optimum preoperative imaging strategy remains controversial, preoperative evaluation of carotid stenosis typically consists of screening duplex sonography and confirmatory MR angiography or catheter angiography. Catheter angiography has been the traditional method for evaluating carotid artery disease, and it remains the standard of reference for quantifying the severity of stenosis.

Calculation of the percentage of stenosis in the NASCET and ACAS trials was based on the ratio between the diameter of the vessel at the point of maximum stenosis and the diameter of the presumed normal cervical carotid artery beyond the stenosis (3).

---

Received July 16, 1997; accepted after revision December 19.

Presented at the annual meeting of the American Society of Neuroradiology, Chicago, May 1995.

From the Department of Radiology, Davis Grant Medical Center, Travis AFB, CA (J.E.D.); and the University of Virginia Health Sciences Center, Charlottesville (B.J.M., D.F.K.).

Address reprint requests to James E. Dix, MD, David Grant Medical Center, Department of Radiology SGSX, 101 Modin Circle, Travis AFB, CA.

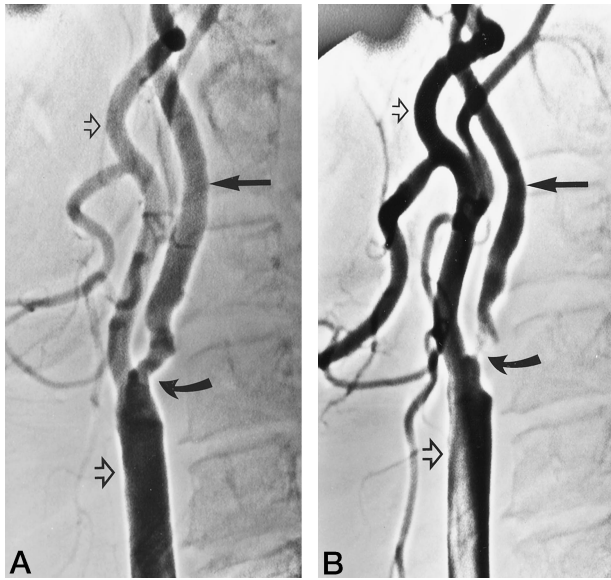


FIG 1. Digital subtraction angiograms of the cervical carotid artery in a patient with left amaurosis fugax illustrate the significance of the small distal ICA. *Curved arrow* indicates maximal maximum stenosis; *straight solid arrow*, the presumed normal distal ICA; *large open arrow*, the CCA; *small open arrow*, the IMA.

A, On the right side, the distal ICA diameter measured 5.1 mm and the proximal stenosis measured 3.1 mm, yielding a calculated percentage of stenosis by NASCET criteria of 38%.

B, On the left side, the distal ICA diameter measured only 3.6 mm and the stenosis measured 1.4 mm, yielding a calculated percentage of stenosis by NASCET criteria of 61%. The difference in distal ICA diameters was 1.5 mm, a percentage difference of 34%. Recalculating the percentage of stenosis by substituting the contralateral distal ICA diameter upgrades the right-sided stenosis to 73%.

This formula assumes that stenosis depends not only on the size of the narrowed vessel but also on the size of the distal internal carotid artery (ICA).

The NASCET investigators recognized that the distal ICA may be reduced in caliber when proximal stenosis is present (1), thereby decreasing the measurement of stenosis. Consequently, these researchers identified features of near occlusion to highlight the possible ambiguity in calculations of the severity of stenosis in the presence of a small distal ICA (Fox AS, et al. "The art of carotid stenosis measurement: recognition of 'approaching near occlusion.'" Presented at the annual meeting of American Society of Neuroradiology, Chicago, 1995). These features included a small distal ICA, delayed filling of the ICA branches relative to those of the external carotid artery (ECA), and cross-filling of intracranial collaterals. In the NASCET trial, patients with these features were identified as having a stenosis of greater than 70% (Fox et al, ARRS meeting, 1995). In another paper, the NASCET investigators reported assigning a grade of 95% stenosis when they noted a small distal ICA, but did not clarify at what point the distal ICA was considered "small" (4).

Figure 1 is a representative example of a 38% stenosis on the right side and a 61% stenosis on the left side according to strictly applied NASCET crite-

ria. Although many radiologists would recognize the small distal ICA and correctly describe this finding as indicative of severe stenosis, the criteria for defining a small distal ICA are unclear. We attempted to quantify and further characterize the reduction in diameter of the distal ICA in the presence of proximal stenosis and to discuss the implications for calculating carotid stenosis.

## Methods

We retrospectively reviewed the carotid angiograms of 81 patients with suspected carotid stenosis who had been referred from the noninvasive vascular lab at our institution between 1992 and 1995. The digital subtraction angiograms obtained to define the maximum point of stenosis included anteroposterior, lateral, and, if necessary, oblique projections. Patients with contralateral ICA occlusion were excluded from our sample. The angiograms were reviewed retrospectively and measurements were made by two neuroradiologists on film using precision calipers with a submillimeter scale (0.01 mm). The diameter of the cervical ICA was measured at the point of maximum stenosis and at the presumed normal area beyond the stenosis on the anteroposterior, lateral, and, when obtained, oblique projections. The diameters of the common carotid artery (CCA) and the internal maxillary artery (IMA) were also measured. The IMA was used as an indicator of the size of the ECA, since the IMA measurements obtained were more consistent than the values derived from the main and collateral ECA branches. Because angiographic images can be magnified digitally with an image intensifier, we made corrections for image intensifier magnification by dividing vessel size by the magnification factor. No correction was made for geometric magnification; that is, the distance between the vessel and the image intensifier.

The single projection with the highest percentage of stenosis ( $1 - \text{stenosis diameter}/\text{distal ICA diameter}$ ) was defined as the NASCET stenosis. The average difference in diameter and the percentage of difference in diameter between the ipsilateral and contralateral distal ICAs were calculated, and the results were analyzed by the NASCET percentage of stenosis. The correlation coefficient of the NASCET percentage of stenosis was compared with the size of the distal ICA, CCA, and IMA, and the percentage of stenosis was recalculated by substituting the contralateral distal ICA diameter for the ipsilateral distal ICA diameter in the NASCET formula. Statistical comparison was made of vessel categories by using a two-tailed Student's *t*-test.

## Results

Among the 81 patients in our study, 20 had severe (>70%) proximal ICA stenosis, 45 had mild to moderate (1% to 69%) stenosis, and 16 had no proximal stenosis in either carotid artery. In carotid arteries with no proximal stenosis (carotid bulb larger than distal ICA), the distal ICA diameter measured  $5.7 \pm 0.84$  mm ( $\pm$  one standard deviation), but in a vessel with severe stenosis (>70%), the distal ICA diameter measured  $4.69 \pm 1.23$  mm ( $P = .0002$ ). In carotid arteries with no proximal stenosis, the CCA measured  $9.28 \pm 2.11$  mm, and in a vessel with severe stenosis, the CCA measured  $8.56 \pm 2.10$  mm ( $P = .27$ ). In carotid arteries with no proximal stenosis, the IMA measured  $2.70 \pm 0.66$  mm, and in a vessel with severe stenosis, the IMA measured  $2.82 \pm 0.77$  mm ( $P = .56$ ).

Table 1 further subdivides vessel size by percentage of stenosis. The increase in size of the diameter of the distal ICA in vessels with moderate stenosis compared with the diameter of the distal ICA in vessels with mild or severe stenosis can be explained if the degree of stenosis in the contralateral vessel is considered. In carotid arteries with no stenosis in the ipsilateral or contralateral vessel, the distal ICA diameter measured  $5.77 \pm 0.84$  mm. In a vessel with an ipsilateral moderate stenosis and a contralateral severe stenosis, the distal ICA diameter measured  $6.20 \pm 1.06$  mm ( $P < .03$ ), indicating a small but significant increase in size of the distal ICA if the

contralateral artery was severely stenosed. This increase in size of the contralateral ICA was not apparent in vessels with 90% or greater stenosis, but the sample size was too small to draw any conclusions from this observation.

A more useful measurement than the actual vessel diameter is the relative size of the bilateral distal ICAs. Table 2 shows the average difference between the ipsilateral distal ICA and the contralateral distal ICA. The measurement of the carotid artery with a higher-grade stenosis was subtracted from the measurement of the contralateral, less diseased vessel. In vessels without a significant proximal stenosis (<70%), the mean distal ICA difference was  $0.03 \pm 0.10$  mm compared with vessels with a 70% or greater stenosis, in which the mean distal ICA difference was  $-1.63 \pm 1.34$  mm ( $P < .00004$ ). (Negative numbers indicate that the ipsilateral distal ICA was smaller than the contralateral distal ICA.)

Figure 2 shows graphically the percentage of difference in size of the ipsilateral and contralateral distal ICA (calculated as the difference in the size of the distal ICA divided by the average size of the distal ICA). On average, the distal ICA began to decrease in size relative to the contralateral carotid artery when stenosis was 60% or greater.

The correlation coefficient of the NASCET percentage of stenosis and the size of the distal ICA for vessels with a 60% or greater stenosis was  $-0.52$ , indicating a moderate correlation between severe proximal stenosis and a decrease in size of the distal ICA. If the distal ICA is correlated with the percentage of stenosis calculated by substituting the contralateral for the ipsilateral ICA measurements, the correlation coefficient increases to  $-0.74$ . The correlation coefficient of the NASCET percentage of stenosis and the CCA and IMA was  $-0.26$  and  $+0.13$ , respectively.

Recalculating the percentage of stenosis by substituting the presumed normal diameter of the contralateral distal ICA for the ipsilateral, small distal ICA resulted in the upgrading in classification of four

TABLE 1: NASCET percentage of stenosis and average vessel diameter

NASCET Stenosis (%)	Vessel Size (mm)			
	DICA	CCA	IMA	Contralateral DICA
0 (Bilateral)	5.77	9.44	2.72	
0-50	5.93	8.89	2.69	5.65
50-60	6.40	9.38	2.73	5.92
60-70	6.07	10.4	3.34	6.13
70-80	5.15	8.88	3.13	6.51
80-90	4.49	8.26	2.66	5.92
90-99	3.33	6.84	2.47	5.67

Note.—DICA indicates distal internal carotid arteries; CCA, common carotid artery; IMA, internal maxillary artery.

TABLE 2: NASCET Percentage of stenosis and difference in distal ICA diameter

NASCET Stenosis (%)	Difference (mm)
0 (Bilateral)	0.25
0-50	0.02
50-60	0.35
60-70	-0.35
70-80	-1.43
80-90	-1.68
90-99	-2.35

Note.—The difference is the ipsilateral DICA of the more severe vessel stenosis minus the contralateral DICA.

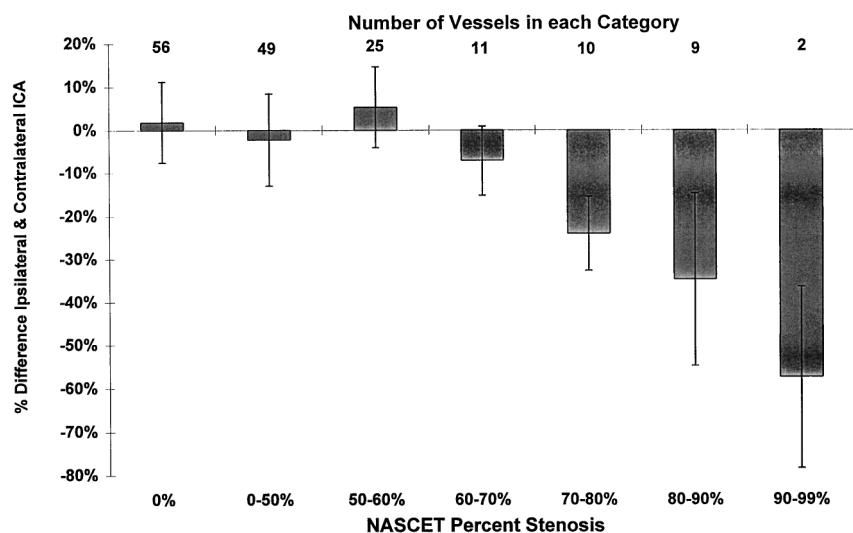


FIG 2. Graph shows the percentage of difference in the relative size of the distal ICA with increasing stenosis by NASCET criteria. Comparison of the carotids with no stenosis (0%) with carotids with 60% to 70% stenosis gave a  $P$  value of 0.3; a comparison with carotids with a stenosis of 70% or greater gave a  $P$  value of  $<.03$ .

of 26 small distal ICAs from moderate (40% to 69%) to severe (>70%) stenosis.

### Discussion

Carotid stenosis is generally classified by angiographic subgroups on the basis of degree of stenosis, most commonly as mild (<30%), moderate (30% to 69%), and severe (70% to 99%). The NASCET trial team demonstrated significant stroke reduction in patients with symptomatic carotid stenosis of 70% or greater by using the single projection with maximum stenosis as the point of reference for stenosis measurement. These investigators also defined a small distal ICA beyond a stenosis as a severe stenosis (4). The reduction in size is believed to stem from decreased intravascular pressure due to a reduction in flow, with the decrease in pressure causing the partial collapse of the distal vessel (4). As the investigators noted, the reduced caliber of the distal ICA causes an underestimation of the severity of stenosis when the formula for stenosis calculation is applied. However, it has not been clarified at what point the distal ICA becomes "small."

Our results indicate that the carotid artery distal to a proximal stenosis of 60% or greater, as derived by the NASCET criteria, begins to decrease in caliber. This effect is best demonstrated by comparing the size of the ipsilateral and contralateral distal ICAs. We found an increasing disparity between the two sides as the severity of stenosis increased beyond 60%. Conversely, the size of the CCA and IMA correlated less strongly with the size of the ICA. A small, variable increase in the size of the IMA occurred with a severe stenosis, which was possibly related to development of ECA to ICA collaterals to supply the brain. The CCA decreased slightly in size, although not to the same degree as the distal ICA. The relative preservation of CCA diameter as compared with ICA diameter may reflect the balance between decreased flow in the distal ICA and increased flow in the IMA related to the development of external to internal carotid collaterals.

If the ipsilateral distal ICA is smaller than the contralateral distal ICA, a recalculation of the percentage of stenosis performed by substituting the contralateral distal ICA diameter for the ipsilateral diameter may be warranted. This method may provide a more accurate indicator of the hemodynamic significance of the stenosis, especially in symptomatic patients with 60% to 69% stenosis. The overall impact on the calculation of the percentage of stenosis for carotid endarterectomy may be small, but for the individual patient, the change in management may be significant if surgery depends on the stenosis being 70% or greater.

### Conclusion

Our study was limited by the small sample size and the lack of correction for geometric magnification. The presence of bilateral moderate or severe stenosis would have changed the size of the contralateral ICA that we presumed normal for the purposes of the study. These limitations would increase variability in the measured size of the distal ICA and make the argument for the small distal ICA more difficult. The statistically significant results obtained should actually be more convincing given these limitations of our study.

### References

1. North American Symptomatic Carotid Endarterectomy Trial Collaborators. **Beneficial effect of carotid endarterectomy in symptomatic patients with high-grade stenoses.** *N Engl J Med* 1991;325:445-453
2. Executive Committee for the Asymptomatic Carotid Atherosclerosis Study. **Endarterectomy for asymptomatic carotid artery stenosis.** *JAMA* 1995;273:1421-1428
3. Fox AJ. **How to measure carotid stenosis.** *Radiology* 1993;186:316-318
4. North American Symptomatic Carotid Endarterectomy Trial (NASCET) Steering Committee. **North American symptomatic carotid endarterectomy trial: methods, patient characteristics, and progress.** *Stroke* 1991;22:711-720