

## Traumatic Subluxation of the Globe into the Maxillary Sinus

Ron W. Pelton, A. Melinda Rainey, and Andrew G. Lee

**Summary:** We report a case of complete traumatic subluxation of the globe into the maxillary sinus as documented by CT. The cornea sustained a mild epithelial abrasion but the globe was otherwise intact without signs of trauma.

A review of the literature reveals that complete traumatic subluxation of the globe into the maxillary sinus is a rare occurrence but that good visual function can be maintained. We describe the CT findings in a patient who sustained this type of injury, which resulted in mild epithelial abrasion of the cornea but an intact globe, and then discuss a mechanistic theory to explain the lack of major injury to the globe.

### Case Report

A 19-year-old man involved in a high-speed motor vehicle accident was brought to the emergency center with extensive left-sided head trauma. CT scans of the head showed massive soft-tissue injuries to the face with multiple fractures and complex trauma to the brain. The patient had an open, depressed skull fracture with bone fragments and hemorrhage within the left frontal lobe, and diffuse subarachnoid hemorrhage. Axial CT scans through the left orbit revealed severe disruption of the orbital anatomy with large fractures of the medial and

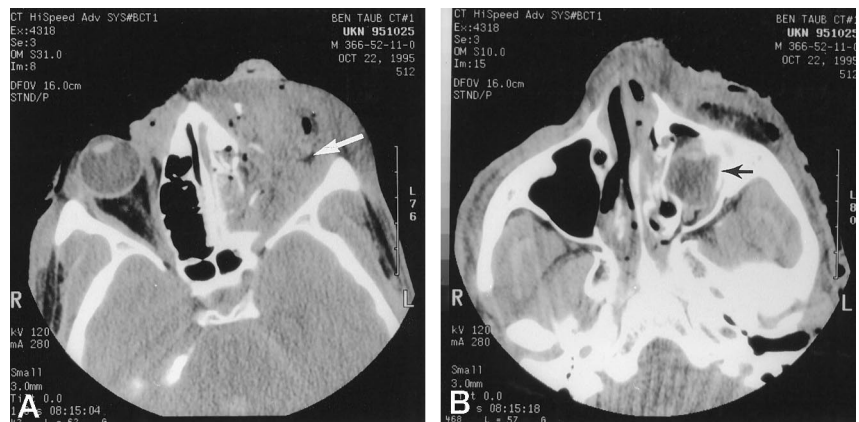
inferior orbital walls, obliteration of the normal orbital fat, and diffuse hemorrhage mixed with air and bony fragments. The orbital rims were intact, however (Fig 1A). The patient was unconscious on arrival to our hospital and visual acuity was not recordable. No globe was visible in the left orbit and, therefore, no assessment could be made of its integrity. Axial CT scans through the lower part of the face showed the left globe to be intact within the antrum of the left maxillary sinus (Fig 1B).

The patient underwent emergent surgical repair of his facial and ophthalmic injuries. At the time of surgery, he was noted to have a laceration of the upper eyelid and disruption of the left medial canthal tendon and canalicular system. The orbital rim was intact, but there were fractures of the medial and inferior walls of the left orbit. The right eye was normal. The left globe was found encased in orbital fat and soft tissue within the antrum of the left maxillary sinus. The globe was elevated from the sinus cavity and was found to be well formed and completely intact except for a small central epithelial abrasion of the cornea. The anterior chamber of the eye was well formed and there was no hyphema present. The lens was clear. The pupil was somewhat dilated and nonreactive to light and remained nonreactive. Indirect ophthalmoscopy showed a normal retina, normal retinal vessels, and an intact optic nerve. The patient never regained consciousness and died 7 days after surgery. Visual acuity could not be assessed after surgery, but the left globe was intact postoperatively.

FIG 1. 19-year-old man with extensive left-sided head trauma sustained during a high-speed motor vehicle accident.

A, Axial CT scan through the orbits shows the right globe and orbit are intact. The left orbit has extensive fractures of the medial wall with air and bone fragments in the orbit. No globe is seen in the orbit on the left (arrow).

B, Axial CT scan through the maxillary sinuses and lower part of the face shows the intact left globe within the left maxillary sinus (arrow). The lens is situated anteriorly in its expected position.



Received August 29, 1997; accepted after revision December 12.

Supported by an unrestricted grant from the Research to Prevent Blindness, Inc, New York, NY.

From the Department of Ophthalmology, Cullen Eye Institute (R.W.P., A.M.R., A.G.L.); the Departments of Neurology (A.G.L.) and Neurosurgery (A.G.L.), Baylor College of Medicine, Houston, TX; and the Division of Neurosurgery, M. D. Anderson Cancer Center, The University of Texas, Houston (A.G.L.).

Address reprint requests to Andrew G. Lee, MD, Cullen Eye Institute, Baylor College of Medicine, 6565 Fannin St, NC 205, Houston, TX 77030.

### Discussion

It is well known that blunt trauma to the periocular region with an object larger than the orbital rim (eg, a fist or dashboard) can result in a fracture to the orbital floor without causing damage to the globe itself (1-6); however, complete dislocation of an intact globe into the maxillary sinus is rare (1-3). Ziccardi et al (4) reported a patient who retained 20/40 vision in an eye that had been subluxated into the maxillary sinus, and Berkowitz et al (5) described a patient with normal vision after subluxation of the globe into the antrum of the maxillary sinus, demonstrating that good vision can be recovered after massive injury to the orbit. Although our patient never recovered consciousness, and his visual outcome is unknown, no significant trauma to the globe was identified.

The globe is held in the orbit by fascial tissue, extraocular muscles, ligamentous tissue, and orbital fat, all of which provide substantial soft-tissue support. Because this soft-tissue padding is able to absorb considerable energy, blunt trauma to the ocular region can produce damage to the orbit (especially the floor) while causing little or no trauma to the globe itself. Conversely, trauma with objects smaller than the orbital rim may disrupt soft tissue without encountering orbital bone, and this may result in penetrating injury to the globe itself. Moreover, while a small fracture of the orbital floor may have no effect on the position of the globe, a large fracture may

cause clinically significant hypoglobus without affecting globe function.

### Conclusion

Our patient had extensive fractures of the medial wall and floor of the left orbit with herniation of most of the orbital contents into the left maxillary antrum. This soft-tissue globe apparently acted as padding for the globe against the bony walls of the traumatized orbit and sinus, thus sparing the globe from significant damage. Hence, massive disruption of the orbit as evidenced by CT may not correspond well with damage to the globe or final visual outcome.

### References

1. Schultz RC. **One thousand consecutive cases of major facial trauma.** *Rev Surg* 1970;27:394-410
2. Mustarde JC. **The orbital walls.** In: *Repair and Reconstruction in the Orbital Region.* Edinburgh: Churchill Livingstone; 1980:273
3. Whitaker LA, Schaffer DB. **Severe traumatic oculo-orbital displacement.** *Plast Reconstr Surg* 1977;59:352-359
4. Ziccardi VB, Patterson GT, Ramasastry S, Sotereanos GC. **Management of a severe zygomatico-orbital fracture with dislocation of the globe into the antrum.** *J Craniofac Surg* 1993;4:95-101
5. Berkowitz RA, Putterman AM, Patel DB. **Prolapse of the globe into the maxillary sinus after orbital floor fracture.** *Am J Ophthalmol* 1981;91:253-257
6. Koorneff L, Zonneveld FW. **Role of direct multiplanar high resolution CT in the assessment and management of orbital trauma.** *Radiol Clin North Am* 1987;25:753-766
7. Zilkha A. **Computed tomography of blowout fractures of the medial orbital wall.** *AJNR Am J Neuroradiol* 1981;2:427-429