

Transcranial Doppler Sonographic Monitoring during Cerebral Aneurysm Embolization: A Preliminary Report

Giovanni Lagalla, Maria Gabriella Ceravolo, Leandro Provinciali, Maria Antonietta Recchioni, Alessandro Ducati, Ugo Pasquini, Claudio Piana, and Ugo Salvolini

BACKGROUND AND PURPOSE: The wide application of embolization in the treatment of aneurysms has created the need for an intraprocedural means to anticipate a poor outcome by monitoring hemodynamic changes in the brain.

METHODS: Transcranial Doppler sonography was used to monitor flow velocity in the middle cerebral artery (MCA) in 23 patients undergoing embolization with Guglielmi detachable coils (GDCs) of either incidental or symptomatic intracranial aneurysms. Sonographic values were recorded from the ipsilateral MCA at the beginning, middle, and end of the interventional procedure and 24 hours afterward.

RESULTS: No complications occurred in 15 patients. In these cases, sonography showed an average decrease in MCA flow velocity of 2.7% after GDC application, returning to baseline at the end of treatment and then increasing by about 17% 24 hours later. In four patients with vasospasm on posttreatment angiograms, MCA flow velocity increased to values higher than 120 cm/s after GDC application, returning to baseline after 24 hours. In four patients with ischemic complications (two transient ischemic attacks, one stroke, one vascular death), MCA flow velocity decreased more than 30% and did not return to preoperative values within 24 hours.

CONCLUSION: The application of transcranial Doppler sonographic monitoring during endovascular treatment may help to identify patients at risk for posttreatment cerebral ischemia.

The endovascular treatment of intracranial aneurysms with Guglielmi detachable coils (GDCs) is an interventional technique that has been shown to be as safe and effective as the standard surgical approach in selected cases (1, 2). It is usually performed with the patient under general anesthesia or deep sedation (3, 4). Studies designed to monitor the safety and adequacy of such an approach intraprocedurally are under development (5, 6). Transcranial Doppler sonography is a reliable and noninvasive technique that can detect hemodynamic changes in the brain (7). Recently, this procedure has been applied to the monitoring of flow velocity changes in the middle cerebral artery (MCA) during percutaneous transluminal an-

gioplasty (PTA) of the carotid artery (8) in treatment of arteriovenous malformations (9) and giant serpentine aneurysms (10).

The wide application of embolization in the treatment of aneurysms supports the need for a noninvasive means to predict a poor outcome by evaluating hemodynamic changes in the brain intraprocedurally. The aim of this study was to assess the prognostic role of sonographic monitoring with respect to clinical outcome after aneurysm embolization with GDCs.

Methods

A group of 23 patients consecutively referred from the neurosurgery clinic to the neuroradiology department of our institution for GDC embolization of an intracranial aneurysm were enrolled in the study. The subjects included nine men and 14 women with a mean age of 56 ± 12 years (range, 33 to 76 years); 17 (74%) had subarachnoid hemorrhage (SAH) from a ruptured aneurysm and six (26%) had "incidental" aneurysms. The endovascular procedure had been determined to be the treatment of choice. Subjects with a "poor" transtemporal window were excluded. No patients had intracranial pressure monitors or previous ventriculostomies placed for hemorrhage.

Received September 17, 1997; accepted after revision February 9, 1998.

From the Clinics of Neurorehabilitation (G.L., M.G.C., L.P.) and Neurosurgery (M.A.R., A.D.), and the Department of Neuro-radiology (U.P., C.P., U.S.), University of Ancona, Italy.

Address reprint requests to Professor Ugo Salvolini, Dipartimento di Neuroradiologia, Azienda Ospedaliera Umberto I, via Conca, 60020 Ancona, Italy.

The aneurysmal site was at the MCA in four patients, the carotid siphon in eight patients, and the anterior communicating artery in 11 patients.

Procedure

In 21 subjects, GDC embolization was performed under general anesthesia; deep sedation was used in the remaining two patients. Narcotics were the only anesthetic used. A bolus of 5000 U of heparin was given to patients immediately before the catheterization and boluses of 100 U were administered every 30 minutes. The procedure, carried out by experienced neuroradiologists, began with the angiographic demonstration of the lesion; the aneurysm was then catheterized with a microcatheter, using the roadmap technique, and densely packed with 0.010 GDC coils (soft type). Angiography was repeatedly performed during treatment to evaluate GDC steadiness and at the end of the intervention to establish the complete exclusion of the aneurysm from the cerebral circulation and the patency of the parent vessel.

Perioperative complications, documented on the basis of clinical assessment by trained neurologists with the aid of angiography and CT, included vasospasm, transient ischemic attacks, and stroke or death.

Transcranial Doppler sonography was performed with a pulsed-wave device: MultiDop T, DWL Elektronische Systeme gmbH with a 2-MHz transducer. The MCA ipsilateral to the intervention side was insonated at a depth of 45 to 55 mm (11). The mean blood flow velocity (time-averaged peak frequencies of the envelope curve of the Doppler spectrum) and the pulsatility index (systolic velocity minus diastolic velocity divided by mean blood flow velocity) (12) were recorded before endovascular treatment; during GDC application, immediately after angiography; at the end of the intervention; and 24 hours later. Flow velocity and pulsatility index in the contralateral MCA were recorded just at baseline and on the day after treatment.

The World Federation of Neurosurgeons Scale (WFNS) score (13) and the CT pattern of hemorrhage as assessed by the Fisher Scale (14) were ascertained in symptomatic patients.

Data Analysis

The relationship between clinical data and the occurrence of perioperative complications was investigated by using either an analysis of variance (ANOVA) for parametric data (age and time elapsed from SAH in symptomatic patients) or contingency table analysis of categorical data (sex, aneurysmal site, WFNS and Fisher scores, success of embolization procedure). Flow velocity and pulsatility index trends in the ipsilateral MCA were analyzed during treatment by using an ANOVA test for repeated measures. Finally, a two-way ANOVA was applied to test differences in flow velocity changes between patients with and without complications.

Results

Clinical Findings

In symptomatic patients, endovascular treatment was performed within 20 days of SAH onset (median, 72 hours; range, 24 hours to 20 days). The distribution of WFNS scores was as follows: grade 1, 16 cases; grade 2, four cases; grade 3, one case; and grade 4, two cases. On the Fisher scale, eight patients had a score of 2, three had a score of 3, and six had a score of 4.

GDC embolization proved to be successful in 18 (78%) of the 23 patients. In the remaining five patients (one of whom was asymptomatic), technical

impediments led the neuroradiologist to stop the procedure before the aneurysm could be completely excised.

Transient and permanent perioperative complications were observed in eight (35%) of the patients. In four (17%) of the patients (one of whom had an incidental aneurysm), immediate posttreatment angiography showed the occurrence of vasospasm; one patient incurred persisting neurologic deficits with CT evidence of ischemic stroke a few hours after partial (50%) aneurysmal occlusion with GDCs; one patient bled again and died; and two patients had transient hemiparesis contralateral to the intervention site with a normal CT pattern. All ischemic events occurred within 24 hours and involved previously symptomatic patients.

No clinical data (ie, age, sex, time elapsed from SAH, aneurysmal site, WFNS and Fisher scores, and success of intervention) were associated with the occurrence of either vasospasm or cerebral ischemia. Table 1 summarizes the clinical information for all patients in the study.

Transcranial Doppler Sonographic Findings

In uncomplicated cases, intraoperative sonographic monitoring showed an ipsilateral decrease in MCA flow velocity of 2.7% on average (median, 2%), starting immediately after GDC application, which returned to baseline at the end of treatment and then increased by about 17% (median, 11%) 24 hours later. In all patients who had vasospasm at posttreatment angiography, ipsilateral MCA flow velocity increased to values higher than 120 cm/s after GDC application and decreased toward starting values after 24 hours. In the remaining four subjects, ipsilateral MCA flow velocity decreased more than 30% during the intervention and did not return to pretreatment values, even after 24 hours (Table 2). Figure 1 shows the ipsilateral MCA flow velocity trend in the three subgroups (two-way ANOVA, time \times treatment: $P < .0001$).

Similar differences were found by analyzing the contralateral variations in MCA flow velocity induced by the endovascular procedure. In particular, in patients without complications, this parameter showed an increase of 8.6% on average, against a 14.5% increase exhibited by patients with vasospasm and an 11.7% decrease recorded in subjects with ischemic complications. Pulsatility index values did not show any significant variation during sonographic monitoring. Sonograms showed both positive and negative predictive values of 100% in the diagnosis of vasospasm as documented by angiography.

Discussion

Previous studies have proved the usefulness of sonographic monitoring during and after carotid PTA (15, 16). Furthermore, other investigations have shown the high sensitivity of sonographic parameters in detecting cerebral ischemia with respect to neuro-

TABLE 1: Demographic and clinical data for 23 patients with intracranial aneurysm

Case	Age, y/Sex	Aneurysm Site	Symptoms	WFNS Score	Fisher Scale Score	Time from SAH, d	Aneurysm Exclusion	Complications
1	71/F	MCA	No	1	1	—	Yes	None
2	67/F	CS	Yes	2	4	1	Yes	Stroke
3	55/M	MCA	No	1	1	—	No	None
4	72/F	CS	Yes	1	3	2	No	None
5	48/F	ACoA	Yes	1	2	1	Yes	None
6	47/F	ACoA	Yes	1	2	3	Yes	None
7	67/F	ACoA	Yes	1	2	16	Yes	None
8	58/F	ACoA	Yes	1	2	7	Yes	Vasospasm
9	64/F	MCA	Yes	2	3	2	Yes	Stroke
10	34/M	MCA	No	1	1	...	Yes	None
11	66/F	CS	No	1	1	...	Yes	None
12	54/M	CS	No	1	1	...	No	Vasospasm
13	54/M	CS	No	1	1	...	Yes	None
14	49/F	CS	Yes	1	2	3	Yes	None
15	76/F	CS	Yes	4	4	18	Yes	None
16	57/M	ACoA	Yes	2	4	20	No	None
17	48/M	ACoA	Yes	1	4	15	Yes	Vasospasm
18	55/M	ACoA	Yes	1	2	16	Yes	Stroke
19	35/F	CS	Yes	2	4	1	Yes	None
20	48/M	ACoA	Yes	1	2	2	Yes	Stroke
21	66/F	ACoA	Yes	3	3	19	Yes	None
22	65/F	ACoA	Yes	4	4	3	Yes	Vasospasm
23	33/M	ACoA	Yes	1	2	12	No	None

Note.—MCA, middle cerebral artery; CS, carotid siphon; ACoA, anterior communicating artery; SAH, subarachnoid hemorrhage; WFNS, World Federation of Neurosurgeons Scale.

TABLE 2: Transcranial Doppler sonographic findings in 23 patients during embolization for intracranial aneurysms

Case	Complications	Flow Velocity in Ipsilateral MCA, cm/s				Flow Velocity in Contralateral MCA, cm/s	
		Baseline	After GDC Application	At End of Procedure	After 24 h	Baseline	After 24 h
1	None	52	45	43	57	50	54
2	Stroke	47	31	29	30	45	28
3	None	58	65	64	67	64	65
4	None	59	54	63	79	56	58
5	None	59	54	57	64	53	60
6	None	83	85	88	96	84	86
7	None	64	54	56	61	74	72
8	Vasospasm	63	184	111	99	63	100
9	Stroke	80	53	54	63	81	75
10	None	75	61	55	83	58	73
11	None	51	50	58	64	64	70
12	Vasospasm	50	124	72	57	47	50
13	None	47	47	50	56	50	72
14	None	45	44	42	65	58	64
15	None	37	37	39	35	37	39
16	None	48	40	38	42	48	48
17	Vasospasm	88	157	95	111	68	60
18	Stroke	60	38	51	53	55	58
19	None	75	79	79	80	81	86
20	Stroke	60	35	59	72	69	64
21	None	60	72	95	106	103	108
22	Vasospasm	50	148	69	54	64	67
23	None	72	76	84	80	84	82

Note.—MCA, middle cerebral artery.

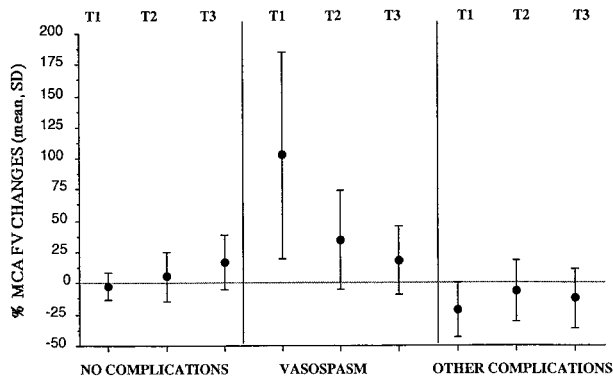


FIG 1. Percentage of change in ipsilateral MCA flow velocity with respect to baseline in three different phases of treatment: T1, immediately after GDC application; T2, at the end of the intervention; and T3, 24 hours later. The average and SD values are indicated for each subgroup of patients. Two-way ANOVA showed the intergroup difference in changes in MCA flow velocity (FV) during treatment ($P < .0001$).

physiological procedures (EEG and somatosensory evoked potentials) (17, 18). A recent report by Fukui et al (19) compared changes in sonographic parameters with data provided by a Doppler guidewire during the endovascular treatment of 12 patients (six with arteriovenous malformations, two with carotid cavernous fistulas, two with facial angiomas, and two with carotid stenosis) and stressed the important role of sonography in assessing hemodynamic consequences of interventional procedures. Schuknecht et al (20) recently used transcranial color Doppler sonography to demonstrate the lack of hemodynamic compromise adjacent to an occluded aneurysm. In our study, transcranial color Doppler sonograms depicted three different hemodynamic patterns in patients undergoing endovascular treatment. In patients without complications, sonography showed a slight transient reduction in MCA flow velocity immediately after GDC application. In agreement with the report by Fukui et al (19), such a finding probably reflects a distal vasoconstrictory reaction to the vascular procedure downstream from the catheter application. The subsequent increase in flow velocity in both MCA territories is difficult to explain, not being related to the administration of any drug with known vasoactive properties. In particular, no changes could be attributed to anesthetics, since only narcotics were used.

In a few patients in our study the enhancement and persistence of vasoconstriction after GDC application appeared to be highly correlated with the onset of cerebral ischemia. In this regard, Eckert et al (8) suggested that an MCA flow velocity reduction of more than 50% may be a negative prognostic factor when monitoring brain hemodynamics during carotid PTA. Our experience supports a lower cut-off, because a decrease in MCA flow velocity of more than 30% and persisting for 24 hours preceded the occurrence of ischemic complications in 100% of the cases. In the remaining patients, transient vasospasm was diagnosed at sonography with a 100% positive predictive value as determined by angiography, with

MCA flow velocity values higher than 120 cm/s. The occurrence of vasospasm in a patient with an asymptomatic aneurysm was possibly caused by the manipulation of the catheter guidewire. Pulsatility index values did not appear to be significantly related to any procedural event or clinical change, at variance with the observations of Fukui et al (19).

GDC application proved to be a relatively safe procedure. The cumulative rate of mortality and permanent disability was about 8% (2/23), overlapping that described either in surgical series (2) or in other experiences with endovascular treatment (5, 6). Complications were probably related to both the natural history of the aneurysm and to the embolization procedure. However, it was not possible to identify any clinical predictive factor. In particular, aneurysmal site did not correlate with the occurrence of perioperative complications and neither did the severity of clinical conditions (in terms of WFNS score) or cerebral hemorrhage (in terms of Fisher score). Furthermore, no evidence of any definite influence from treatment delay was found, as a similar rate of complications was observed in embolization procedures performed within or after 72 hours. Such findings may be a strong argument in favor of the endovascular procedure when comatose patients have to be treated and the more invasive surgical approach is contraindicated. No technical problems prevented sonographic monitoring during the endovascular procedure.

Conclusion

Although our study contained a small sample of patients, we believe the lack of clinical predictive factors enhances the usefulness of sonographic monitoring in detecting hemodynamic changes during GDC embolization. The finding of a persistent and severe reduction in MCA flow velocity (greater than 30%) during and after catheterization may be a positive prognosticator of ischemic complications, whereas an increase in MCA flow velocity greater than 120 cm/s is a reliable sign of vasospasm. Sonographic findings obtained during the endovascular treatment of intracranial aneurysms may be important in determining the timing of therapy. Abnormal intraprocedural findings may suggest that an interruption or delay in aneurysmal coiling might decrease the rate of complications. These data may have a positive impact on the clinical outcome of the endovascular treatment of aneurysms. However, the role and value of intraprocedural sonographic monitoring remain to be clarified.

References

1. Guglielmi G, Vinuela F, Sepetka I, Macellani V. **Electrothrombosis of vascular aneurysms via endovascular approach, I: electrochemical basis, technique and experimental results.** *J Neurosurg* 1991; 75:1-7
2. Richling B, Bavinski G, Gross C, Gruber A, Killer M. **Early clinical outcome of patients with ruptured cerebral aneurysms treated by endovascular (GDC) or microsurgical techniques: a single center experience.** *Intervent Neuroradiol* 1995;1:19-27

3. Byrne JV, Molyneux AJ, Brennan RP, Renowden SA. **Embolization of recently ruptured intracranial aneurysms.** *J Neurol Neurosurg Psychiatry* 1995;59:616–620
4. Manninen PH, Gignac EM, Gelb AW, Lownie SP. **Anesthesia for interventional neuroradiology.** *J Clin Anesth* 1995;7:448–452
5. Martin D, Rodesch G, Alvarez H, Lasjaunias P. **Preliminary results of embolization of nonsurgical intracranial aneurysms with GD coils: the 1st year of their use.** *Neuroradiology* 1996;38:S142–S150
6. Houdart E. **Traitement par spires (coils) à détachement contrôlé électrique de 315 aneurysmes intracrâniens.** *Bull Acad Natl Med* 1996;180:1173–1186
7. Newell DW, Aaslid R. **Transcranial Doppler: clinical and experimental uses.** *Cerebrovasc Brain Metab Rev* 1992;4:122–143
8. Eckert B, Thie A, Valdueza J, Zanella F, Zeumer H. **Transcranial Doppler sonography monitoring during percutaneous transluminal angioplasty of the internal carotid artery.** *Neuroradiology* 1997;39:229–234
9. Guglielmi G, Vinuela F, Duckwiler G, Dion J, Stocker A. **High flow, small-hole arteriovenous fistulas: treatment with electrode-tachable coils.** *AJNR Am J Neuroradiol* 1995;16:325–328
10. Mawad ME, Klucznik RP. **Giant serpentine aneurysms: radiographic features and endovascular treatment.** *AJNR Am J Neuroradiol* 1995;16:1053–1060
11. Fujioka KA, Douville CM. **Anatomy and freehand techniques.** In: **Newell DW, Aaslid R, eds.** *Transcranial Doppler*. New York: Raven Press; 1992:9–31
12. Aaslid R. *Transcranial Doppler Sonography*. Vienna: Springer; 1986
13. Drake CG. **Report of World Federation of Neurological Surgeons Committee on a universal subarachnoid haemorrhage grading scale.** *J Neurosurg* 1988;68:985–986
14. Fisher CM, Kistler JP, Davis JM. **Relation of cerebral vasospasm to subarachnoid haemorrhage visualized by CT scanning.** *Neurosurgery* 1980;6:1–9
15. McDowell HA, Gross GM, Halsey JH. **Carotid endarterectomy monitored with transcranial Doppler.** *Ann Surg* 1992;215:514–519
16. Chiesa R, Minicucci F, Melissano G, et al. **The role of transcranial Doppler in carotid artery surgery.** *Eur J Vasc Surg* 1992;6:211–216
17. Thiel A, Russ W, Zeiler D, Dapper F, Hempelmann G. **Transcranial Doppler sonography and somatosensory evoked potential monitoring in carotid surgery.** *Eur J Vasc Surg* 1990;4:597–602
18. Jansen C, Vriens EM, Eikelboom BC, Vermeulen FE, van Gijn J, Ackerstaff RGA. **Carotid endarterectomy with transcranial Doppler and electroencephalographic monitoring: a prospective study in 130 operations.** *Stroke* 1993;24:665–669
19. Fukui K, Negoro M, Takahashi I, Fukasaku K, Nakabayashi K, Yoshida J. **Usefulness of intravascular Doppler flow measurements in cerebral endovascular treatment: a comparison with transcranial Doppler.** *Intervent Neuroradiol* 1996;2:103–110
20. Schuknecht BF, Chen JJ, Scholz VH, Valavanis A. **Transcranial color coded Doppler sonography evaluation of intracranial aneurysms before and after endovascular occlusion with Guglielmi detachable coils.** In: *Book of Abstracts: American Society of Neuroradiology Annual Meeting, 1997*. Oak Brook, IL: American Society of Neuroradiology; 1997:187–188