

Are your **MRI contrast agents** cost-effective?

Learn more about generic **Gadolinium-Based Contrast Agents**.



FRESENIUS  
KABI

caring for life

# AJNR

## **Myelography of Spinal Block from Epidural Tumor: A New Approach**

Philip B. Katz, Ya-Yen Lee, Sidney Wallace and Ronald D. Ray

*AJNR Am J Neuroradiol* 1981, 2 (2) 121-123

<http://www.ajnr.org/content/2/2/121>

This information is current as  
of April 20, 2024.

# Myelography of Spinal Block from Epidural Tumor: A New Approach

Philip B. Katz<sup>1</sup>  
Ya-Yen Lee<sup>2</sup>  
Sidney Wallace<sup>1</sup>  
Ronald D. Ray<sup>2</sup>

Eleven patients with spinal canal block from metastatic epidural tumor, documented with Pantopaque myelography, were given an additional injection of up to 5 cc of air. This technique forced contrast material past the block in 10 of 11 cases. It failed in one case in which symptoms had been present for 19 days. Air injection allowed visualization of more cephalad lesions and defined the superior extent of the initial obstructing lesion without the need for a lateral cervical or cisternal puncture. It caused transient discomfort but no neurologic deterioration. This technique is less painful, requires less patient cooperation, expedites localization, and does not require the special skills needed for cervical puncture.

The most common neoplasms that cause myelographic spinal block are metastatic lesions. These arise most often from carcinoma of the breast in women and carcinoma of the lung in men, followed by carcinomas of the prostate and kidney. The initial presenting symptom is usually localized pain followed by progressive sensory and motor dysfunction. Patients with such symptoms are referred for emergency myelographic evaluation to determine the presence, location, and extent of spinal canal obstruction. If high grade or complete obstruction is present, the patient is considered for immediate treatment by decompressive laminectomy or radiation therapy in an attempt to avoid permanent neurologic deficits [1].

Conventional myelographic technique involves the introduction of a small quantity, usually 2–4 ml, of Pantopaque via the lumbar route. This small bolus of contrast material is manipulated cephalad under fluoroscopic control. If no block is encountered, the contrast material is returned to the lumbar level, cerebral spinal fluid is removed for study, and additional Pantopaque is introduced for total myelography. If a block is encountered, an attempt is made to manipulate the small contrast bolus past the block by a variety of maneuvers. If the block cannot be overcome, the patient may be returned to the horizontal position and additional contrast material introduced via cisternal or lateral C1–C2 puncture. Alternatively, a second injection of 2–4 ml of Pantopaque may be performed with the patient maintained in Trendelenburg position in an attempt to displace contrast material around and above the obstruction [2].

Water-soluble contrast medium (Metrizamide) has also been used in the evaluation of spinal block. The diffusibility of the medium has been believed to be helpful in distinguishing a stenotic lesion from complete obstruction. However, a high incidence of low back pain for 1–2 days after the examination has been encountered in patients with stenosis or block [3]. Furthermore, this contrast medium is reabsorbed, not allowing for follow-up fluoroscopic examination to assess the results of treatment.

It is essential that the level(s) of compression and the distance over which the compression occurs be accurately defined, either for possible decompressive laminectomy or the planning of appropriate fields for radiation therapy. We

Received September 16, 1980; accepted October 16, 1980.

<sup>1</sup>Department of Diagnostic Radiology, M. D. Anderson Hospital and Tumor Institute, University of Texas System Cancer Center, Houston, TX 77030. Address reprint requests to S. Wallace.

<sup>2</sup>Department of Radiology, University of Texas Health Science Center, Houston, TX 77030.

This article appears in March/April 1981 *AJNR* and May 1981 *AJR*.

**AJNR 2:121–123, March/April 1981**  
0195–6108/81/0022–0121 \$00.00  
© American Roentgen Ray Society



describe a simple alternative technique to define the upper margins of the block, as well as any additional levels of involvement, using air with Pantopaque. This technique avoids a potentially more hazardous cisternal or lateral cervical puncture and does not involve the introduction of additional Pantopaque which cannot be removed at the conclusion of the study.

### Subjects and Methods

We studied 11 patients with known primary neoplasms causing pain, neurologic dysfunction, and spinal block. After lumbar puncture in the prone position with an 18 gauge spinal needle, 3 ml of Pantopaque was introduced into the subarachnoid space. The patient was placed in steep Trendelenburg position and frontal and cross-table lateral views were obtained to define the inferior margin of the block. If the Pantopaque column did not advance after a few minutes, 5 cc of filtered air was slowly injected under fluoroscopic observation. The injection was terminated when the block was overcome. This maneuver increases the cerebrospinal fluid pressure below the level of the block. The contrast material was followed to the level of the clivus to detect any additional sites of obstruction. If none was noted, the patient was returned to the semierect position and frontal and cross-table lateral views were repeated to outline the superior margin of the obstruction. The extent of the lesion was marked on the patient's skin with an indelible marker.

### Representative Case Reports

#### Case 1

A 66-year-old man with stage D transitional cell carcinoma of the bladder was referred after sudden onset of numbness of both lower extremities and urinary incontinence. Physical examination revealed a sensory level of T2 on the left and T3–T4 on the right, as well as paraparesis of the lower extremities. He had previously received radiation therapy at a dose of 2,500 rad (25 Gy) over 2 weeks to the thoracic spine from T3 to T10 for known bone metastases. At myelography, 3 ml of Pantopaque outlined the inferior margin of an extradural obstructing lesion at the T2–T3 level (fig. 1A). The patient was left in Trendelenburg position for 2–3 min with no advance of the Pantopaque column. A 1 cc injection of air then easily displaced Pantopaque above the block, demonstrating the superior margin at the T1–T2 level (fig. 1B). The patient was treated with an additional 3,000 rad (30 Gy) over a 2 week period because he was considered an overall poor candidate for surgery. His clinical course deteriorated and he died from massive bilateral fungal and bacterial pneumonia 11 days after the study. Autopsy demonstrated metastatic involvement of the upper thoracic spine.

#### Case 2

A 63-year-old woman was seen for low back and right leg pain that developed acutely after lifting a heavy object. Conventional radiographs were normal and no further studies were performed. She developed ascending numbness and weakness in the lower extremities. Within 24 hr, total paraplegia and bladder incontinence were present. Blood studies disclosed a white blood cell count of 35,000/mm<sup>3</sup> with 80% lymphs. She was referred to M. D. Anderson Hospital for further evaluation, with a presumptive diagnosis of chronic lymphocytic leukemia.

Physical examination on admission revealed flaccid paraplegia as well as bladder and rectal incontinence. Thoracic spine radio-

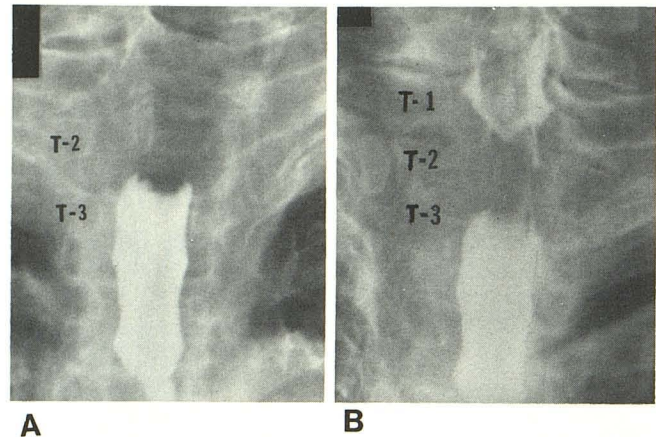


Fig. 1.—Metastatic carcinoma of bladder. **A**, Contrast material outlines inferior surface of block at T2–T3. **B**, 1 cc of air displaces contrast above block outlining superior surface at T1–T2.

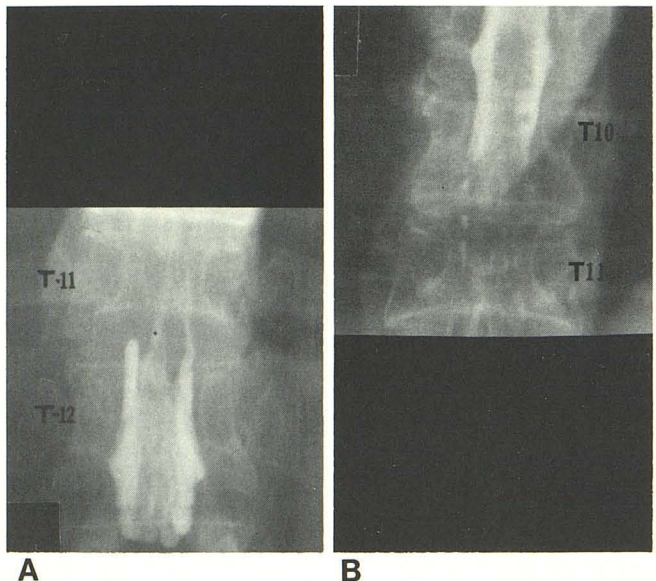


Fig. 2.—Chronic lymphocytic leukemia. **A**, Pathologic compression fracture of the body of T11. Contrast displaced by 5 cc air above block at T11–T12 level. **B**, Superior margin of block at T10.

graphs demonstrated pathologic compression fracture of the body of T11. High grade extradural block at the T11–T12 level was encountered at myelography with 3 ml of Pantopaque. The patient was left in Trendelenburg position for 2–3 min with no advance of the Pantopaque column. Injection of 5 cc air displaced contrast material around and above the lesion (fig. 2A), demonstrating the superior margin to lie at T10 (fig. 2B). The patient declined any form of treatment and returned home for further care by her local physician. She was lost to follow-up.

#### Case 3

A 37-year-old woman with stage IV carcinoma of the breast received 2,500 rad (25 Gy) in 2 weeks to the T8–L1 levels for metastatic involvement of T11 with partial collapse. At 20 months after treatment, she experienced sudden onset of disabling low back pain radiating to both legs. Plain films disclosed complete

collapse of the body of T11 with acute angulation at this site. At 19 days after onset of symptoms, she was referred for myelography. A complete extradural block at the inferior margin of T11 was encountered with Pantopaque. Routine maneuvers followed by introduction of 5 cc of air were totally ineffective in bypassing the block. The patient was treated with radiation (2,500 rad [25 Gy] over 2 weeks) to the region with considerable symptomatic improvement. A follow-up lumbar spine study demonstrated Pantopaque to lie both above and below the T11 level, and the patient was painfree and ambulatory 6 months after initial study.

### Discussion

Our experience with a simple technique to define the extent of spinal canal obstruction by metastatic epidural tumor is encouraging. Ten of 11 attempts were successful. In case 3, in which the block could not be bypassed, the patient had symptoms for 19 days before examination. It is possible the long duration of the obstruction contributed to the failure of the technique, since in all patients examined acutely after the onset of signs and symptoms, "complete" obstructions were bypassed with relative ease. All patients described mild, transient, pressurelike pain in the back and

legs during the introduction of air, but the symptoms immediately subsided after cessation of injection. No other complications were encountered and clinical deterioration did not occur. Information was obtained that aided considerably in planning surgical or radiotherapeutic management.

### ACKNOWLEDGMENT

We thank L. Anne Hayman for review of the manuscript and suggestions.

### REFERENCES

1. Rodriguez M, Dinapoli RP. Spinal cord compression with special reference to metastatic epidural tumors. *Mayo Clin Proc* **1980**;55:442-448
2. Levine HL, Olmstead EJ. Myelographic evaluation of nontraumatic spinal canal obstruction: a new approach. *AJR* **1979**;133:715-718
3. Sortland O, Magnaes B, Hauge T. Functional myelography with metrizamide in the diagnosis of lumbar spinal stenosis. *Acta Radiol [Suppl] (Stockh)* **1977**;355:42-53