

Are your **MRI contrast agents** cost-effective?

Learn more about generic **Gadolinium-Based Contrast Agents**.



FRESENIUS
KABI

caring for life

AJNR

CT of generalized gray matter infarction due to hypoglycemia.

M L Richardson, R E Kinard and M B Gray

AJNR Am J Neuroradiol 1981, 2 (4) 366-367

<http://www.ajnr.org/content/2/4/366.citation>

This information is current as
of April 19, 2024.

CT of Generalized Gray Matter Infarction due to Hypoglycemia

Michael L. Richardson,¹ Richard E. Kinard, and Mark B. Gray

Generalized infarction of cerebral gray matter with relative white matter sparing is found in a wide variety of anoxic injuries to the brain, including hypoglycemia. To our knowledge, our case report is the first to describe the computed tomographic (CT) findings in this entity.

Case Report

A 35-year-old man was found unconscious at home by his roommate. On arrival at a nearby hospital emergency room, he demonstrated decorticate posturing, an absent pupillary light reflex bilaterally, and was unresponsive to painful stimuli. A serum glucose drawn on arrival was 26 mg/dl. His initial laboratory studies, including electrolytes and a drug screen, were otherwise unremarkable. An admission CT scan of the head was considered normal.

He had no history of diabetes mellitus, and was taking no known medications. He had been diagnosed clinically as having "hypoglycemia" some 8 months before, but this was apparently never documented chemically. He was reported to have engaged in episodic bouts of heavy drinking, but his medical history was otherwise unremarkable.

He was initially treated with intravenous glucose, and maintained satisfactory serum glucose levels for the rest of his hospital course. Subsequent laboratory studies yielded a minimally decreased T4 of 2.3 $\mu\text{g/dl}$ (normal, 4.5–12 $\mu\text{g/dl}$) and decreased plasma cortisol of 2 $\mu\text{g/dl}$ (normal, 5–25 $\mu\text{g/dl}$). The rest of his endocrine workup was normal, including a normal fasting serum insulin level. A repeat CT head scan 1 week after admission (figs. 1A and 1B), demonstrated patchy cortical enhancement after contrast administration. He was treated with supplemental levothyroxine and hydrocortisone and nasogastric tube feedings. Repeat CT on hospital day 26 (figs. 1C – 1G) demonstrated intense enhancement of much of his cerebral gray matter after intravenous contrast administration.

Despite treatment, he never regained consciousness and died on hospital day 27. An autopsy was performed with particular attention to the endocrine system. However, no abnormalities were demonstrated in the thyroid or adrenals, and careful sectioning of the pancreas showed no evidence of an insulinoma. Sections of the cerebral cortex revealed diffuse and severe laminar necrosis of gray matter accompanied by gliosis. Sections of the basal ganglia, cerebellum, and pons also showed anoxic changes. The white matter was unremarkable, other than mild edema seen in some sections. The final diagnosis was diffuse gray matter encephalopathy due to hypoglycemia, etiology unknown.

Discussion

The pathologic changes in the brain in fatal hypoglycemia have been described by several authors [1, 2]. The most consistently described lesions are diffuse laminar cortical infarction and edema. These changes are nonspecific, and have been described in many other processes causing diffuse cerebral anoxia, such as carbon monoxide intoxication, nitrous oxide anesthesia, mechanical strangulation, cardiac arrest, shock, gastrointestinal bleeding, and myocardial infarction [2, 3].

The mechanism of brain injury in severe hypoglycemia depends on the fact that glucose is the main substrate which the brain uses for its oxidative processes. The hypoglycemic mechanism is not, strictly speaking, one of anoxia. However, the absence of glucose effectively brings the process of intracellular respiration in the brain to a halt, by causing a nonutilization of oxygen by the neurons. The resulting lesions closely resemble those caused by true cerebral anoxia [4].

The major difference between the changes seen in fatal hypoglycemia and those seen in cerebral infarctions due to atherosclerotic disease is primarily one of location. The latter type of infarction is usually focal, commonly affects both gray and white matter, and often occurs in the territory of a major cerebral artery or branch. In severe hypoglycemia, almost all cells in the central nervous system are affected to some degree. However, the most severely affected are those of the cerebral cortex, followed in order by the basal ganglia, the cerebellum, and the rest of the brainstem [1, 4, 5]. The white matter is frequently spared, other than a mild gliosis.

The temporal sequence of CT findings seen in our patient closely parallels the pathologic findings described by previous investigators. Courville [2] found that cases surviving only short periods after the hypoglycemic insult showed diffuse neuronal changes, sometimes associated with an irregular, patchy loss of nerve cells. He also found that as the survival time after the insult is increasingly lengthened, focal and then laminar necrosis becomes more evident. Lawrence et al. [1] described similar temporal changes in their series of six patients.

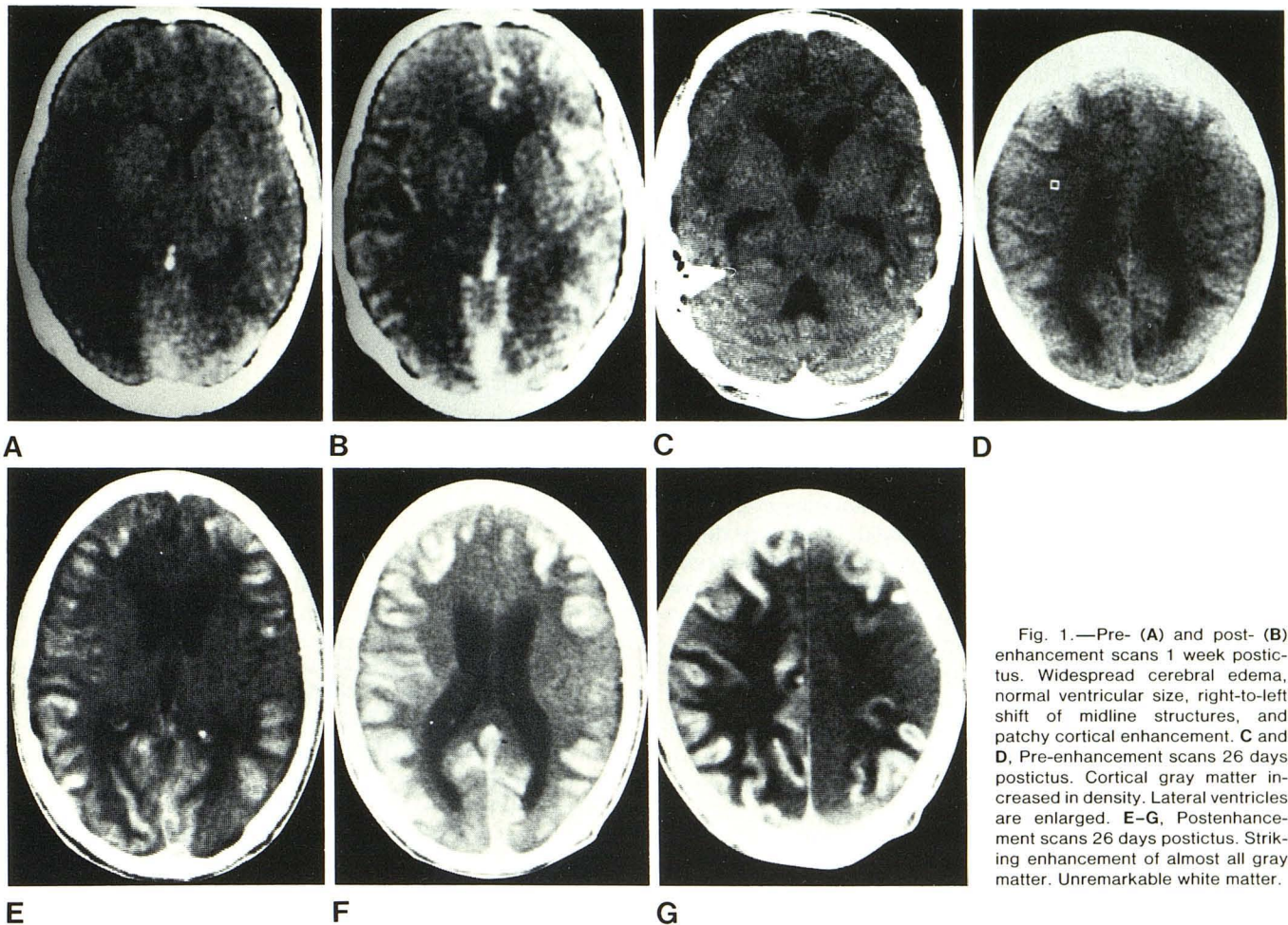


Fig. 1.—Pre- (A) and post- (B) enhancement scans 1 week postictus. Widespread cerebral edema, normal ventricular size, right-to-left shift of midline structures, and patchy cortical enhancement. C and D, Pre-enhancement scans 26 days postictus. Cortical gray matter increased in density. Lateral ventricles are enlarged. E-G, Postenhancement scans 26 days postictus. Striking enhancement of almost all gray matter. Unremarkable white matter.

It is interesting to compare the sequential CT findings in our patient with those seen in more focal cerebral infarction. The typical changes in acute cerebral infarction have been reported by numerous investigators [6, 7]. These consist of low density lesions, often in the distribution of a major cerebral artery, which tend to become more prominent with the passage of time. In general, few nonhemorrhagic infarctions enhance with intravenous contrast until 1–2 weeks postictus. This pattern of enhancement usually peaks around the second postictal week, and then gradually fades with time. About one-half of the patients who show enhancement at 1 or 2 weeks show no enhancement at the end of 1 month. Our patient followed this pattern initially, in that he showed no abnormalities at 24 hr, and definite contrast enhancement at 1 week postictus. However, the scan on his postictal day 26 was somewhat atypical in that the preenhancement scan showed a CT density of about 52 Hounsfield units in the areas of cortical necrosis. This was significantly higher than normal. After contrast administration, the

necrotic areas demonstrated intense enhancement. The explanation for this anomalous behavior is unknown.

REFERENCES

1. Lawrence RD, Meyer A, Nevin S. The pathological changes in the brain in fatal hypoglycaemia. *Q J Med* 1942;11:181–201
2. Courville CB. Late cerebral changes incident to severe hypoglycemia (insulin shock): their relation to cerebral anoxia. *Arch Neurol* 1957;78:1–14
3. Anderson WAD, Kissane JM. *Pathology*, 7th ed. St. Louis: Mosby, 1977:283–287
4. Elliott FH. *Clinical neurology*, 2d ed. Philadelphia: Saunders, 1971:583–585
5. Robbins SL, Cotran RS. *Pathologic basis of disease*, 2d ed. Philadelphia: Saunders, 1979:1552–1553
6. Inoue Y, Takemoto K, Miyamoto T, et al. Sequential computed tomography scans in acute cerebral infarction. *Radiology* 1980;135:655–662
7. Yock DH, Marshall WH. Recent ischemic brain infarcts at computed tomography: appearances pre- and postcontrast infusion. *Radiology* 1975;117:599–608