

Are your MRI contrast agents cost-effective?

Learn more about generic Gadolinium-Based Contrast Agents.



**FRESENIUS
KABI**

caring for life

AJNR

Effectiveness of contrast regimens in CT detection of vascular malformations of the brain.

L A Hayman, A J Fox and R A Evans

AJNR Am J Neuroradiol 1981, 2 (5) 421-425

<http://www.ajnr.org/content/2/5/421>

This information is current as of April 17, 2024.

Effectiveness of Contrast Regimens in CT Detection of Vascular Malformations of the Brain

L. Anne Hayman^{1, 2}
Allan J. Fox³
Robert A. Evans^{1, 4}

Forty-three patients with cerebral vascular malformation were studied with precontrast, immediate contrast, and 1 hr delayed high dose contrast computed tomography (CT) scans. The precontrast scans were abnormal in 81% of patients. The delayed high dose scans demonstrated one angiographically occult, thrombosed arteriovenous malformation not seen on pre- or immediate contrast scans, four cases with additional zones of encapsulated hemorrhage or infarction not seen on pre- or immediate contrast CT, and two cases of venous angiomas seen on immediate contrast scans but not on delayed high dose scans. In 50% of patients, large vessels surrounding the malformation faded on the delayed dose scans which were less specific for vascular malformation than immediate contrast CT. We conclude that: (1) delayed high dose scans offer no significant advantage in patients with symptoms suggesting vascular malformation of the brain; and (2) while less specific than immediate contrast CT, these scans do not preclude detection of vascular malformations of the brain. Therefore, delayed high dose CT can be used in patients with suspected blood-brain barrier lesions without fear of missing vascular malformations.

Contrast enhanced CT is used routinely to screen patients with suspected vascular malformations of the brain. The administration of contrast material has not been standardized, and there are considerable differences in the plasma iodine levels produced by different infusion techniques [1-3; Hayman LA, Hulse M, Feldman S, unpublished data]. We compared the diagnostic quality of scans immediately after administration of contrast media with 1 hr delayed high dose contrast scans in 43 patients with cerebrovascular malformations to determine if delayed high dose scans could be used as a screening procedure without fear of missing vascular malformations.

Received October 28, 1980; accepted after revision March 24, 1981.

Presented at the meeting of the American Society of Neuroradiology, Los Angeles, March 1981.

¹Department of Radiology, Baylor College of Medicine, Houston, TX 77030.

²Department of Radiology, U.S. V.A. Medical Center Hospital, Houston, TX 77030 and the University of Texas Medical School, 6431 Fannin St., Suite 2026, Houston, TX 77030. Address reprint requests to L. A. Hayman.

³Department of Diagnostic Radiology and Clinical Neurosciences, University Hospital, London, Ontario N6A 5A5, Canada.

⁴Department of Radiology, The Methodist Hospital, Houston, TX 77030.

AJNR 2:421-425, September/October 1981

0195-6108/81/0205-0421 \$00.00

© American Roentgen Ray Society

Material and Methods

A prospective study was performed on 39 patients ranging in age from 10 months to 60 years with subsequently surgically or angiographically proven vascular malformations of the brain, and four patients in a family with subsequently surgically proven autosomally dominant, cavernous angiomas of the brain [Hayman LA, Evans RA, Ferrell RE, Fahr LM, Ostrow P, Riccardi VM, unpublished data]. Eight patients had venous angiomas, 29 had 32 arteriovenous malformations, five had 12 cavernous angiomas, and one had Sturge-Weber syndrome. Five cases had acute hemorrhage and none had previous surgery. In 38 patients, the malformations were supratentorial; in five, subtentorial.

A precontrast CT scan was obtained in all patients. About 80 g iodinated contrast material was infused into the 42 adult and adolescent patients; 1 g iodine/kg was infused into the infant. Two infusion techniques were used in the adults. In 27 patients, the first half of the contrast material (about 300 ml Reno-M-Dip, ER Squibb) was given over 5 min, and scans were obtained during a rapid drip of the remaining half of contrast material (about 300 ml). In another 15 patients, half the iodinated contrast media (100 ml Conray 400, Mallinckrodt) was infused rapidly and the scan was performed. Within 15 min after the first infusion, a second injection of iodinated contrast media (300 ml Hypaque, Winthrop) was

given by rapid drip. All 43 patients had CT scanning repeated at 1 hr, delayed high dose scan. EMI 1010, ASE 5005, or GE 8800 scanners were used. The same unit was used for all scans on a given patient. Films were obtained at identical window settings to allow visual comparison of the pre-, immediate, and delayed high dose contrast scans.

Results

The precontrast scan was used to divide the patients into two groups: 35 patients with abnormal (group A) and eight with normal scans (group B) (table 1). Abnormalities in group A included acute hematoma (5), calcification (14), focal low density (4), polyurethane spheres (1), "blood pool" density (11). "Blood pool" density was also seen in most cases of hematoma, calcification, or focal low densities. The immediate contrast scans in each group were compared with the delayed high dose scans. Five categories were used: (1) both immediate contrast and delayed high dose scans falsely negative—3 cases (fig. 1); (2) abnormalities on delayed scans not seen on immediate contrast scans—5 cases (figs. 2 and 3); (3) fading of the malformation on delayed high dose scans—21 cases (figs. 4 and 5); (4) immediate contrast scan the same as delayed high dose scan—12 cases; (5) delayed high dose scan falsely nega-

tive and immediate scan positive—2 cases (table 2). There were no cases in which the immediate or delayed contrast scans obscured areas of low density seen on precontrast CT adjacent to the malformation. Lesion size was 0.3–8 cm, with an average diameter of 2–3 cm.

Arteriograms were diagnostic in 36 cases but were negative in the five cases of cavernous angioma, and in one case of the arteriovenous malformation (fig. 2). Angiography was not done on the patient with Sturge-Weber syndrome. The three category 1 lesions did not show contrast enhancement on immediate or delayed high dose CT but were detected by posterior fossa angiography (fig. 1); two of them had normal precontrast scans.

Discussion

A literature review revealed that CT without contrast material detected cerebral abnormalities in 81% of patients with cerebral vascular malformations. In the remaining 19%, angiomas could be detected if immediate contrast CT was added to the examination [4–15].

In our study, the precontrast CT was abnormal in 35 (81%) patients. In the remaining eight, with normal precontrast scans, the immediate contrast CT was abnormal in five and did not detect the malformation in three. Two of these anomalies were posterior fossa arteriovenous malformations which were also missed on delayed high dose scans (fig. 1); the third was an isodense, thrombosed, angiographically occult malformation that was only recognized on delayed high dose images (fig. 2).

The delayed scan showed zones of enhancement in one patient with normal precontrast and immediate contrast scans (fig. 2). In four patients with abnormal precontrast CT scans, delayed high dose CT demonstrated zones of enhancement not visualized on immediate scans. In one of

TABLE 1: Precontrast CT Appearance of Vascular Malformations of Brain

Type of Malformation	Group A (Abnormal)	Group B (Normal)	Total
Arteriovenous malformation	22	7	29
Venous angioma	7	1	8
Sturge-Weber syndrome	1	0	1
Cavernous angioma	5	0	5
Total	35	8	43

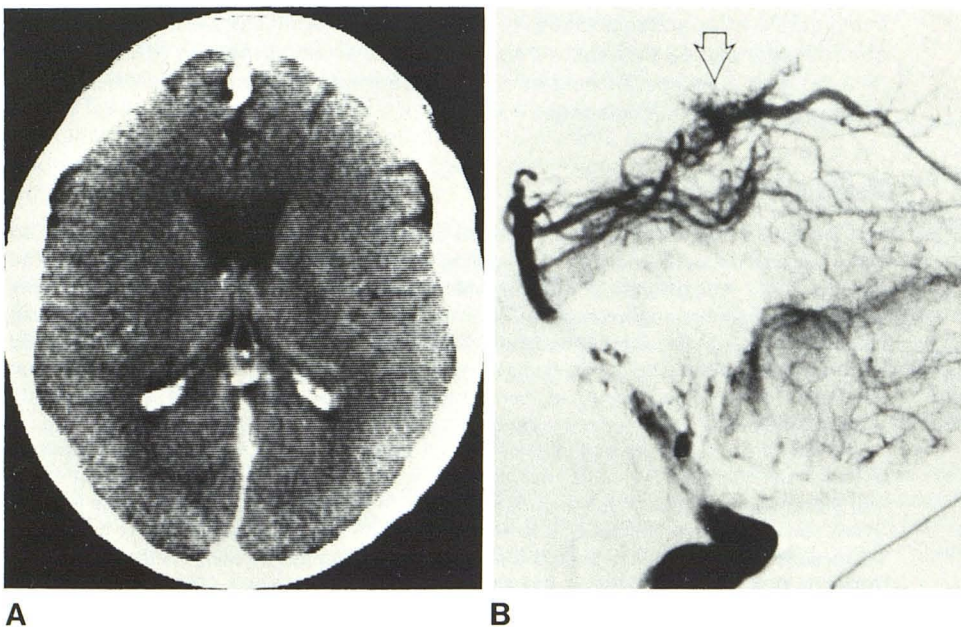


Fig. 1.—Category 1 lesion. A, Normal immediate contrast CT. Delayed high dose contrast scan (not shown) was normal. B, Lateral vertebral angiogram. Arteriovenous malformation of superior vermis and quadrigeminal cistern.

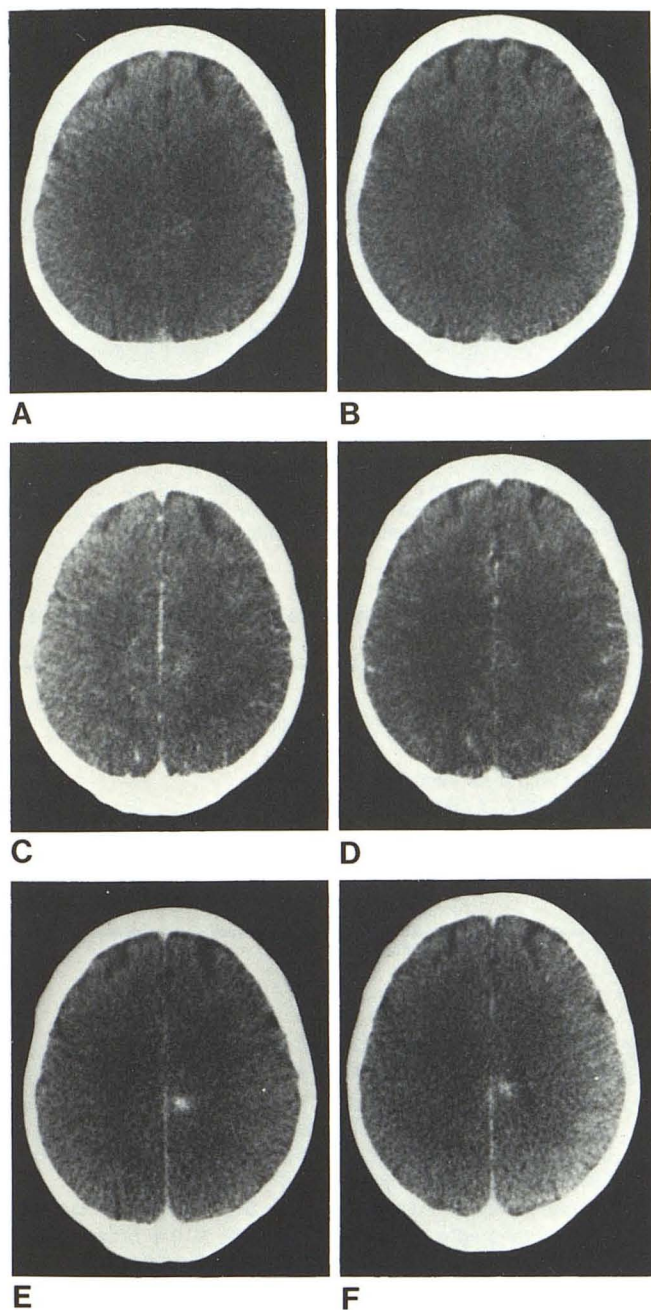


Fig. 2.—Category 2 lesion. Normal precontrast (A and B) and immediate (C and D) contrast CT. Delayed high dose contrast CT (E and F) shows arteriovenous malformation which was removed from left medial parietal cortex. Pathologic examination revealed thrombosis of vessels. Angiography with stereo magnified subtracted films of all cerebral vessels was normal.

these patients an infarction adjacent to an arteriovenous malformation enhanced on the delayed high dose scan (fig. 3). In the other three, enhancement of isodense encapsulated cerebral hemorrhages were seen. In one of the latter cases, there was a striking increase in lesion size on the delayed dose scan.

Although delayed high dose images detected additional zones of cerebral damage and a malformation missed both

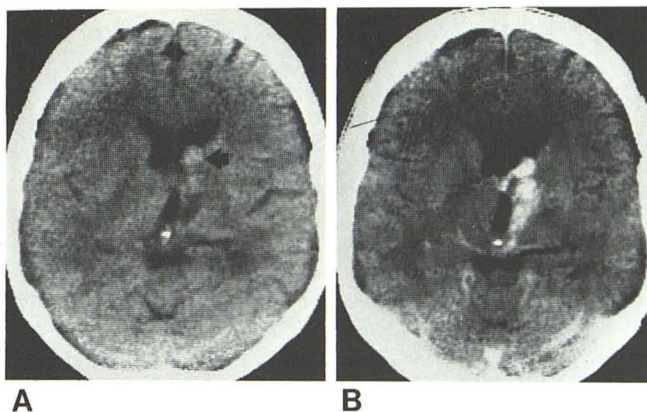


Fig. 3.—Category 2 lesion. A, Precontrast scan. Left anterior medial thalamic low density and blood pool lesion (arrow). B, Delayed high dose scan. Enhanced malformation and area of low density, presumed to be infarct from previous hemorrhage which was *not* enhanced on immediate contrast scan. Small thalamic malformation found at angiography corresponded in position to area of blood pool lesion.

by angiography and by the precontrast and immediate contrast scans, it was not the screening procedure of choice in patients with suspected vascular malformation of the brain. Because vessels often faded from view on the delayed high dose images (fig. 4), these scans were less specific for vascular malformations than immediate contrast images. In one case, the apparent size of the malformation diminished on the delayed high dose scan because the CT numbers of the lesion were very high on the immediate contrast scan. This artifactually magnified the size of the lesion (fig. 5). This phenomenon has been observed by others during CT angiography [16] and has been discussed in a recent publication on the difficulty of measuring object size with CT [17].

In two patients with venous angiomas, delayed high dose CT failed to show enlarged veins which were well seen on the immediate scan (category 5). Diminished blood iodine level and the position of the abnormal vein parallel to the scan slice (which predisposes to volume averaging errors) may account for the failure of the delayed high dose scans in these cases. This error did not, however, prevent detection since the pre- and immediate postcontrast scans were abnormal in both patients.

Although delayed high dose scanning is not the procedure of choice in screening patients with vascular malformations of the brain, it does improve detection of cerebral lesions which visualize because of contrast extravasation [18–20]. This advantage was demonstrated in our series in a patient with a grade II astrocytoma and a venous angioma in whom enhancement of the glioma was greatly improved on the delayed high dose scan.

Because delayed high dose scanning is necessary to detect some tumors but is often inferior to immediate contrast scans in patients with vascular malformations, it is prudent to adjust the technique of contrast administration according to the individual clinical problem. We suggest using delayed scans in patients with a suspected blood-

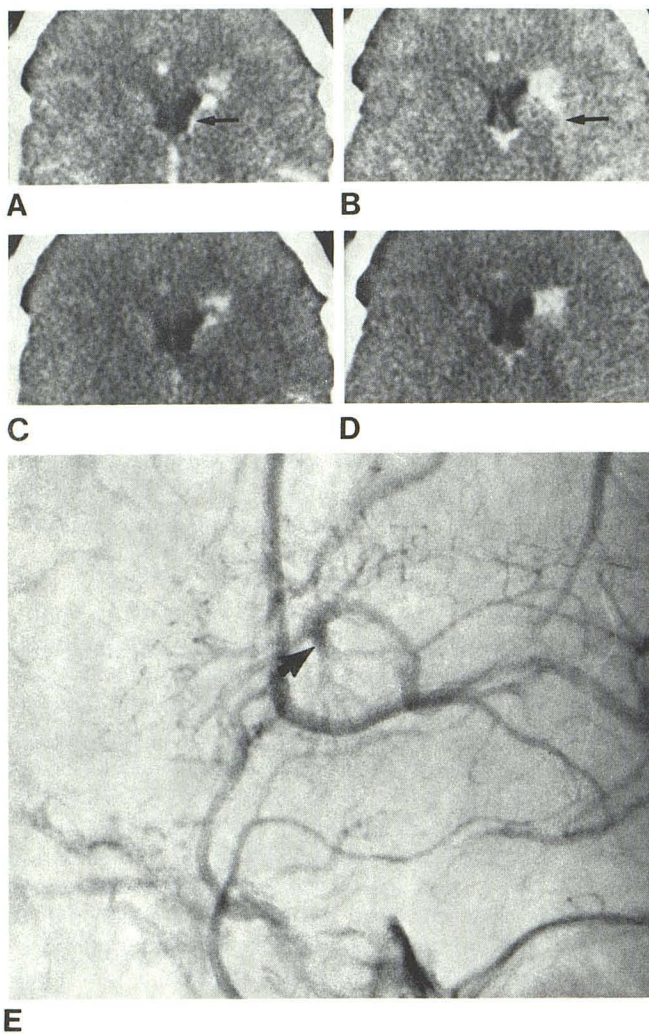


Fig. 4.—Category 3 lesion. **A** and **B**, Immediate contrast CT. High density lesion anterior to the head of caudate nucleus with linear densities extending from it (*arrows*). **C** and **D**, Delayed high dose contrast scan, same window settings. Fading linear densities with continued detection of lesion. **E**, Lateral carotid angiogram, venous phase. Lesion with extending vessels (*arrows*). Venous angioma was found at surgery adjacent to left frontal horn.

brain barrier lesion, adding an immediate contrast scan when a vascular malformation is also a clinical possibility.

ACKNOWLEDGMENTS

We thank I. Kricheff, A. Berenstein, D. Hudson, J. Valk, G. Debrun, S. Handel, P. Shalen, and Y. Y. Lee for contributing cases to this series, and Joyce A. Stedman for secretarial assistance.

REFERENCES

1. Ono N, Martinez CR, Fara JW, Hodges FJ. Diatrizoate distribution in dogs as a function of administration rate and time following intravenous injection. *J Comput Assist Tomogr* 1980;4:174-177
2. Norman D, Stevens EA, Wing SD, Levin V, Newton TH. Quantitative aspects of contrast enhancement in cranial computed tomography. *Radiology* 1978;129:683-688

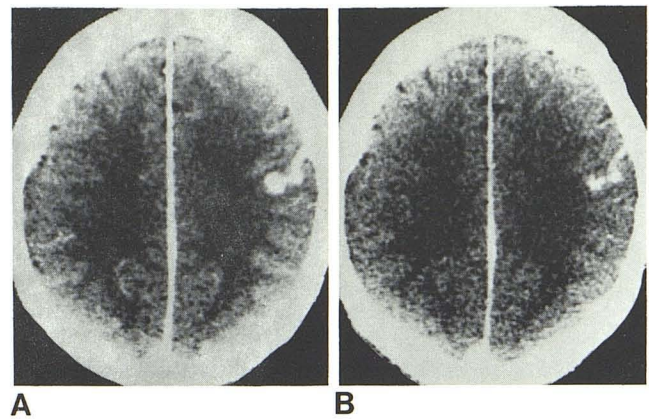


Fig. 5.—Category 3 lesion. **A**, Immediate contrast CT. Left convexity serpiginous density shown to be arteriovenous malformation at angiography. **B**, Delayed high dose CT. True size of lesion seen. Size no longer artifactually enlarged by higher CT units seen on immediate contrast scans.

TABLE 2: Comparison of Immediate and Delayed Contrast CT Scans

Category	Group A (Abnormal Precontrast)	Group B (Normal Precontrast)	Total
1: Both false negative	1	2	3
2: Additional info on delayed CT	4	1	5
3: Lesion faded on delayed CT	18	3	21
4: Same info on each	10	2	12
5: Delayed CT false negative, immediate CT positive	2*	0	2
Total	35	8	43

* Venous angiomas which did not require surgery.

3. Talner LB. Urographic contrast media in uremia; physiology and pharmacology. *Radiol Clin North Am* 1972;10:421-431
4. Hatam A, Bergvall V, Lewander R, Larsson S, Lind M. Contrast medium enhancement with time in computer tomography. In Lindgren E, ed. *Computed tomography of brain lesions. Acta Radiol [Suppl]* (Stockh) 1975;346:63-89
5. Pressman BD, Kirkwood JR, Davis DO. Computerized transverse tomography of vascular lesions of the brain. Part I: arteriovenous malformations. *AJR* 1975;124:208-214
6. Hayward RD. Intracranial arteriovenous malformations. Observations after experience with computerized tomography. *J Neurol Neurosurg Psychiatry* 1976;39:1027-1033
7. Kendall BE, Claveria LE. The use of computed axial tomography (CAT) for the diagnosis and management of intracranial angiomas. *Neuroradiology* 1976;12:141-160
8. Kramer RA, Wing SD. Computed tomography of angiographically occult cerebral vascular malformations. *Radiology* 1977;123:649-652
9. Terbrugge K, Scotti G, Ethier R, Melancon D, Tchang S, Milner C. Computed tomography in intracranial arteriovenous malformations. *Radiology* 1977;122:703-705
10. Bell BA, Kendall BE, Symon L. Angiographically occult arteriovenous malformations of the brain. *J Neurol Neurosurg Psychiatry* 1978;41:1057-1064
11. Weisberg LA. Computed tomography in the diagnosis of intracranial vascular malformations. *Comput Tomogr* 1979;3:125-132

12. Bicknell JM, Carlow TJ, Kornfeld M, Stovring J, Turner P. Familial cavernous angiomas. *Arch Neurol* **1978**;35:746-749
13. Golden JB, Kramer RA. The angiographically occult cerebrovascular malformation. *J Neurosurg* **1978**;48:292-296
14. Terao H, Matsutani M, Okeda R. Detection of cryptic vascular malformations by computerized tomography. *J Neurosurg* **1979**;51:546-551
15. Leblanc R, Ethier R, Little JR. Computerized tomography findings in arteriovenous malformations of the brain. *J Neurosurg* **1979**;51:765-772
16. Dobben GD, Valvassori GE, Mafee MF, Berninger WH. Evaluation of brain circulation by rapid rotational computed tomography. *Radiology* **1979**;133:105-111
17. Seibert CE, Barnes JE, Breisbach JN, Swanson WB, Heck RJ. Accurate CT measurements of the spinal cord using metrizamide: physical factors. *AJNR* **1981**;2:75-78
18. Shalen PR, Hayman LA, Wallace S, Handel SF. Protocol for delayed contrast enhancement in cranial computed tomographic evaluation of cerebral neoplasia. *Radiology* (In press)
19. Hayman LA, Evans RA, Bastion FO, Hinck VC. Delayed high dose contrast CT identifying patients at risk of massive hemorrhagic infarction. *AJNR* **1981**;2:139-147
20. Hayman LA, Evans RA, Hinck VC. Delayed high iodine dose contrast CT: cranial neoplasms. *Radiology* **1980**;136:667-684