

Are your **MRI contrast agents** cost-effective?

Learn more about generic **Gadolinium-Based Contrast Agents**.



FRESENIUS
KABI

caring for life

AJNR

Venous Hypertension Associated with a Posterior Fossa Dural Arteriovenous Fistula: Another Cause of Bithalamic Lesions on MR Images

Glen P. Greenough, Alex Mamourian and Robert E. Harbaugh

AJNR Am J Neuroradiol 1999, 20 (1) 145-147

<http://www.ajnr.org/content/20/1/145>

This information is current as of April 18, 2024.

Venous Hypertension Associated with a Posterior Fossa Dural Arteriovenous Fistula: Another Cause of Bithalamic Lesions on MR Images

Glen P. Greenough, Alex Mamourian, and Robert E. Harbaugh

Summary: We report a case of a posterior fossa arteriovenous fistula (AVF) with bithalamic hyperintensity on MR images. The thalamic abnormality improved after surgery, suggesting reversible venous hypertension as the pathogenesis of the finding, as opposed to infarction. This manifestation of a posterior fossa AVF should be considered in the differential diagnosis of bilateral thalamic disease.

Bithalamic hyperintensity on T2-weighted MR images has been reported with "top of the basilar" infarcts, deep venous thrombosis, and glial tumors (1). We report a case in which bithalamic hyperintensity probably resulted from a dural arteriovenous fistula (AVF) and subsequent venous hypertension. The patient presented with a striking abulia and trouble forming new memories. After surgery, his symptoms as well as the MR signal abnormalities improved over the course of 1 year.

Case Report

A 62-year-old man was admitted to the emergency department with complaints of nausea, confusion, and diaphoresis evolving over 1 day. Over the next 8 hours, a low-grade fever developed and the patient gradually became mute. His medical history was notable only for hypertension.

Initial examination included normal findings on a noncontrast head CT scan and an EEG that showed no background abnormalities and no periodic discharges. A lumbar puncture revealed no WBCs in tubes 1 and 4, but 6000 and 7000 RBCs in tubes 1 and 4, respectively. The CSF protein was 101 mg/dL; CSF glucose, 90 mg/dL; no xanthochromia was detected. Fungal culture, cryptococcal antigen, India ink stain, gram stain, and bacterial culture were all negative. The patient improved to the point where he would make a few one-word answers to direct questions. One week after presentation, a brain MR examination revealed bilateral thalamic findings, and he was then transferred to our institution.

On arrival, he was sitting quietly in a chair and would only speak when directly questioned. He appeared docile and abulic. He knew the day and date but reported that we were "in Jim-

my's house" when asked his location. The most striking abnormality was his inability to form new memories. He would confabulate responses to questions and had a total lack of awareness of his disability. Besides a paucity of speech and perseveration, his language function was intact. The remainder of the mental status examination was normal. General medical findings were normal except for a blood pressure of 174/100.

Results of a neurologic examination were normal except the patient's left side extinguished to double simultaneous tactile stimulation and his tandem gait was unsteady. Laboratory data included a normal complete blood count, electrolytes, blood urea nitrogen, creatinine, and erythrocyte sedimentation rate. Antithrombin III, homocysteine, lupus anticoagulant, protein C assay, protein S assay, anticardiolipin antibody, and thyroid-stimulating hormone assays were also normal.

A repeat head MR study with MR angiography and MR venography (Fig 1A-D) was performed specifically to ascertain whether internal cerebral vein thrombosis was a cause of the thalamic lesions. The MR studies again showed abnormal signal on T2-weighted images in both thalami and in the left caudate and splenium of the corpus callosum. No abnormality of the basilar artery was noted on the MR angiogram, and flow was evident in the internal cerebral veins on the MR venogram. There was no flow in the straight sinus, however, and the vein of Galen was visible on the 3D time-of-flight (TOF) MR angiogram. The following day, conventional cerebral angiography (Fig 1E and F) was performed, which demonstrated a posterior fossa AVF and thrombosed straight sinus. Retrograde flow through the vein of Galen and internal cerebral veins was evident.

During his hospital stay, the patient also underwent neuropsychological testing, which revealed disorientation, severely impaired naming to confrontation, impaired passage comprehension, and severely impaired verbal encoding. Overall, he showed severe cognitive impairment. On day 7 after admission, the patient had his first of three, several-hour-long episodes of nonresponsiveness and muteness. Findings at neurologic examination and vital signs were unremarkable. A CT head scan was unchanged. An EEG that day revealed a normal background and no periodic discharges.

Endovascular therapy was not considered feasible, and neurosurgical treatment was recommended via an occipital and suboccipital craniotomy. The straight sinus was skeletonized and an aneurysm clip was placed across the junction of the straight sinus and the vein of Galen to prevent retrograde flow into the galenic system. Postoperatively, hydrocephalus developed, requiring shunt placement.

A follow-up MR examination 1 week after surgery showed no evidence of the arteriovenous malformation (AVM). T2-weighted images again revealed bilateral thalamic and left caudate abnormalities, which now enhanced. A new cerebellar lesion was noted as well. On the MR study obtained 10 months after surgery, however, no significant signal abnormality or enhancement of the thalami was evident (Fig 1G).

At 4 and 11 months postoperatively, the patient's overall intellectual ability fell into the average range, consistent with

Received October 7, 1997; accepted after revision March 26, 1998.

From the Section of Neurology (G.P.G.), the Department of Radiology (A.M.), and the Section of Neurosurgery (R.E.H.), Dartmouth-Hitchcock Medical Center, Lebanon, NH.

Address reprint requests to Glen P. Greenough, MD, Section of Neurology, Dartmouth-Hitchcock Medical Center, One Medical Center Dr, Lebanon, NH 03756.

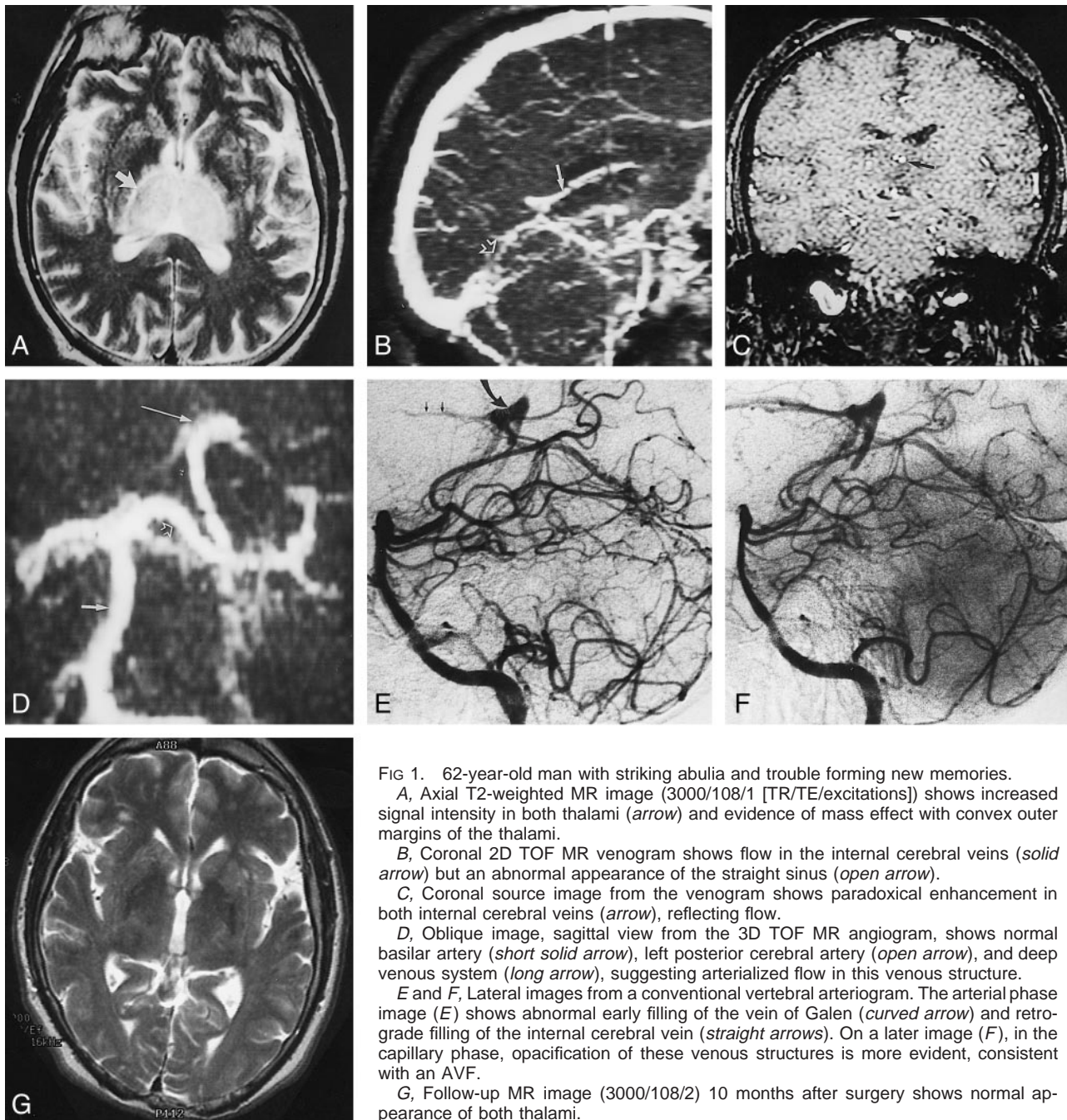


FIG 1. 62-year-old man with striking abulia and trouble forming new memories.

A, Axial T2-weighted MR image (3000/108/1 [TR/TE/excitations]) shows increased signal intensity in both thalami (*arrow*) and evidence of mass effect with convex outer margins of the thalami.

B, Coronal 2D TOF MR venogram shows flow in the internal cerebral veins (*solid arrow*) but an abnormal appearance of the straight sinus (*open arrow*).

C, Coronal source image from the venogram shows paradoxical enhancement in both internal cerebral veins (*arrow*), reflecting flow.

D, Oblique image, sagittal view from the 3D TOF MR angiogram, shows normal basilar artery (*short solid arrow*), left posterior cerebral artery (*open arrow*), and deep venous system (*long arrow*), suggesting arterialized flow in this venous structure.

E and F, Lateral images from a conventional vertebral arteriogram. The arterial phase image (E) shows abnormal early filling of the vein of Galen (*curved arrow*) and retrograde filling of the internal cerebral vein (*straight arrows*). On a later image (F), in the capillary phase, opacification of these venous structures is more evident, consistent with an AVF.

G, Follow-up MR image (3000/108/2) 10 months after surgery shows normal appearance of both thalami.

his educational and occupational background. However, his score on the California Verbal Learning Test-B remained in the severely impaired range at 4 and 11 months. The Wechsler Memory Scale-Revised showed similar deficits between 4 and 11 months. His delayed recall index stayed in the borderline range, and logical memory remained in the severely impaired range. His information and orientation scores improved dramatically from the preoperative to the postoperative tests. Of note, his visual reproduction ability was in the average range. When executive function was tested, the patient scored in the mildly impaired range for Trailmaking Test A and in the severely impaired range for Trailmaking Test B.

Initially, the patient had language deficits, and his verbal comprehension was severely impaired. Preoperatively, his score on a confrontational naming test was 24/60 but improved to 43/60 at 4 months then to 52/60 at 11 months, which placed

him in the average range. His deficits caused him little affective distress, suggesting a lack of awareness or insight into his problems.

Discussion

Dementia and memory loss have previously been described as symptoms of diencephalic stroke. In one report, six patients with infarcts of the paramedian thalamic, subthalamic, and mesencephalic areas were observed to have deficits in arousal, impaired attention, and memory disorder, characterized by anterograde and retrograde loss (2). In the acute phase, these patients were frequently coma-

tose and only later became more alert. The cause of the memory deficits that accompany lesions on the medial thalamus is not well understood. It seems reasonable to attribute them to damage to the dorsomedial nuclei of the thalamus and mamillothalamic tracts. It may be difficult, however, to discern the relative contributions of memory deficits and the apathetic features that may accompany them.

The appearance of abnormal signal in both thalami on T2-weighted images suggests a differential diagnosis that includes basilar artery distribution infarct (top of the basilar syndrome), tumor infiltration, and deep venous occlusion (1). We initially suspected deep venous occlusion, which prompted the initial MR venogram. Bell et al (1) suggested that MR angiography has an important role in distinguishing top of the basilar syndrome from deep cerebral vein thrombosis in patients with bithalamic hyperintensity. In our patient, MR angiography showed flow in the internal cerebral veins, but the straight sinus was not visible. On this basis, conventional angiography was performed, which showed a dural AVF and evidence of retrograde filling of the internal cerebral veins, which we believe explains the curious MR venographic findings.

A recent report (3) describing a case requiring thrombolysis of the deep venous system includes an MR image very similar to our Figure 1A, showing bithalamic signal changes. In that case, there was also complete resolution of the MR signal changes 6 months after treatment of the venous occlusion. In an earlier report of thalamic dementia caused by a tentorial dural AVM (4), there was also reversal of the abnormal thalamic findings as well as marked improvement in the patient's symptoms after surgery. The improvement in MR appearance and clinical symptoms in both cases would suggest that the thalamic lesions reflect venous hypertension as opposed to infarction.

Venous hypertension without infarction has been reported as a cause of neurologic deficits. In a case reported by Hurst et al (5), a patient with a posterior fossa dural AVM manifested paresis of the left hand and changes in mental status that resolved after partial embolization. The authors argued that because of the distance from the AVM, which was supplied by the external carotid artery, arterial steal was an unlikely explanation for the patient's symptoms. A similar case was reported by Kurata et al

(6), in which the patient had visual hallucinations and a quadrantanopia from a dural AVM of the tentorium. The patient's symptoms resolved immediately after endovascular treatment. Neurologic symptoms in patients with spinal dural AVMs have also been attributed in most cases to venous hypertension as opposed to arterial steal (7).

Our patient's cognitive deficits improved substantially after resection of the malformation, suggesting resolution of the presumed venous hypertension. Follow-up neuropsychological testing revealed significant improvement in attention, concentration, language function, and verbal episodic and semantic memory. However, verbal memory, ability to learn new information, semantic retrieval, and processing speed all still showed significant deficits, with verbal memory accounting for the most severe problems.

Conclusion

We report this case to emphasize a potential pitfall of MR venography as well as to offer another consideration for patients with bithalamic MR signal abnormalities. Differentiating venous hypertension from infarction has clinical significance, since the treatment of venous occlusion involves anticoagulation, which might place a patient with a dural AVF at greater risk.

References

1. Bell DA, Davis WL, Osborn AG, Harnsberger HR. **Bithalamic hyperintensity on T2-weighted MR: vascular causes and evaluation with MR angiography.** *AJNR Am J Neuroradiol* 1994;15:893-899
2. Katz DI, Alexander MP, Mandell AM. **Dementia following strokes in the mesencephalon and diencephalon.** *Arch Neurol* 1987;44:1127-1133
3. Holder CA, Bell DA, Lundell AL, Ulmer JL, Glazier SS. **Isolated straight sinus and deep cerebral venous thrombosis: successful treatment with local infusion of urokinase.** *J Neurosurg* 1997;86:704-707
4. Ito M, Sonokawa T, Mishina H, Sato K. **Reversible dural arteriovenous malformation-induced venous ischemia as a cause of dementia: treatment by surgical occlusion of draining dural sinus: case report.** *Neurosurgery* 1995;37:1187-1192
5. Hurst RW, Hackney DB, Goldberg HI, Davis RA. **Reversible arteriovenous malformation-induced venous hypertension as a cause of neurological deficits.** *Neurosurgery* 1992;30:422-425
6. Kurata A, Miyasaka Y, Yoshida T, Kunii M, Yada K, Kan S. **Venous ischemia caused by dural arteriovenous malformation.** *J Neurosurg* 1994;80:552-555
7. Rosenblum B, Oldfield EH, Doppman JL, DiChiro G. **Spinal arteriovenous malformations: a comparison of dural arteriovenous fistulas and intradural AVMs in 81 patients.** *J Neurosurg* 1987;67:795-802