AJNR

The Need for Objective Assessment of the New Imaging Techniques and Understanding the Expanding Roles of Stroke Imaging

William T. C. Yuh, Toshihiro Ueda, Matthew White, Michael E. Schuster and Toshiaki Taoka

AJNR Am J Neuroradiol 1999, 20 (10) 1779-1784
http://www.ajnr.org/content/20/10/1779

The Need for Objective Assessment of the New Imaging Techniques and Understanding the Expanding Roles of Stroke Imaging

William T. C. Yuh, Toshihiro Ueda, Matthew White, Michael E. Schuster, and Toshiaki Taoka

With the advancement of functional imaging and stroke therapy, patients with acute stroke now have a realistic opportunity to benefit from early diagnosis and prompt intervention (1–5). Great enthusiasm and expectation have been generated in stroke imaging, particularly with diffusion-weighted imaging, which has been reported to be highly sensitive and specific in the detection of ischemic changes of parenchyma and in the prediction of infarction in both animal models and in humans (6–25). Although the evaluation of acute ischemia with diffusion-weighted imaging appears to be impeccable, controversies have also arisen (18, 21, 26–30).

Having a better understanding of the underlying pathophysiology of ischemic stroke, we have discovered a vast array of events that can occur after the initial ischemic insult (31–38). Further complicating the issue, all these elements may be involved to various degrees at different times after the onset of the initial ischemic insult. Any attempt to apply a single parameter obtained at a single time point (including diffusion-weighted imaging) to resolve such a dynamic and complex disease process will not be completely successful. Regardless of how complex and dynamic the stroke process can be, we must realize that it is the pre-existing collateral circulation that plays the most critical role to permit us to have an opportunity to treat the stroke (therapeutic window) and to influence the clinical and therapeutic outcome. With complete cessation of blood supply and inadequate collateral circulation, as in cardiac arrest, a neuron will die within 5 minutes. In an occluded artery, re-establishment of blood supply (thrombolysis/recanalization) to ischemic tissue that has been without adequate collateral circulation will not be able to salvage (reverse) the ischemic tissue and may actually cause hemorrhagic complications. In addition, the evolution and outcome of the ischemic injury depends upon the severity and duration of ischemia, which again is critically influenced by collateral circulation (39–42).

Two articles by Lefkowitz et al and Wang et al (pages 1871 and 1876, respectively) in this issue of the *AJNR* reported that infarction can occur in brain parenchyma while diffusion-weighted imaging findings obtained during hyperacute ischemia are negative. In addition, diffusion-weighted imaging can be negative when perfusion-weighted imaging shows extensive abnormalities. These two articles support the notion that the conclusions made by prior studies need to be re-examined in their full context. We must consider the type of patient population (treated versus untreated) that prior reports derived conclusions from as well as the changing role of stroke imaging within expanded clinical needs, including detection/confirmation of acute strokes and assessment of viability/reversibility of ischemic tissue.

Some images of cases reported by these two articles may, particularly in retrospective review, show diffusion abnormality that could represent early ischemic changes. Some of these diffusion changes were subtle when compared with the corresponding perfusion-weighted imaging findings and might not be easily appreciated prospectively. Even if all these changes found retrospectively were true, one can argue that the majority of the infarcted tissue actually did not have diffusion abnormality on the initial examinations. Therefore, the majority of the infarcted tissue of these cases support the fact that ischemic parenchyma with initial negative diffusion-weighted imaging findings can develop into infarction later (Figs 1–2). In addition, marked perfusion abnormality without diffusion abnormality can occur during acute ischemia, which may or may not evolve into infarction in patients with or without recanalization treatment. These facts are contrary to the general belief that diffusion-weighted imaging is more sensitive than perfusion-weighted imaging in detecting acute ischemia and more specific in prediction of ischemic outcome (infarction).

Before making any judgments about these discrepancies, however, there are fundamental principles that have not been emphasized in the past that deserve to be addressed. These include the complex and dynamic pathophysiology involving acute ischemia, differences in capabilities/limitations between techniques, potential bias by the patient population (treated versus untreated), and the expanding roles of stroke imaging in clinical diagnosis and treatment.

Prior studies did not include patients with early recanalization (treated patients). Based upon the untreated patient population, diffusion-weighted imaging has been reported to have a sensitivity and specificity ranging from 88% to 100% and 95% to 100%, respectively, in the diagnosis of acute stroke

Address reprint requests to William T.C. Yuh, MD, Department of Radiology, University of Iowa Hospital, 0416 JCP, Iowa City, Iowa 52242.

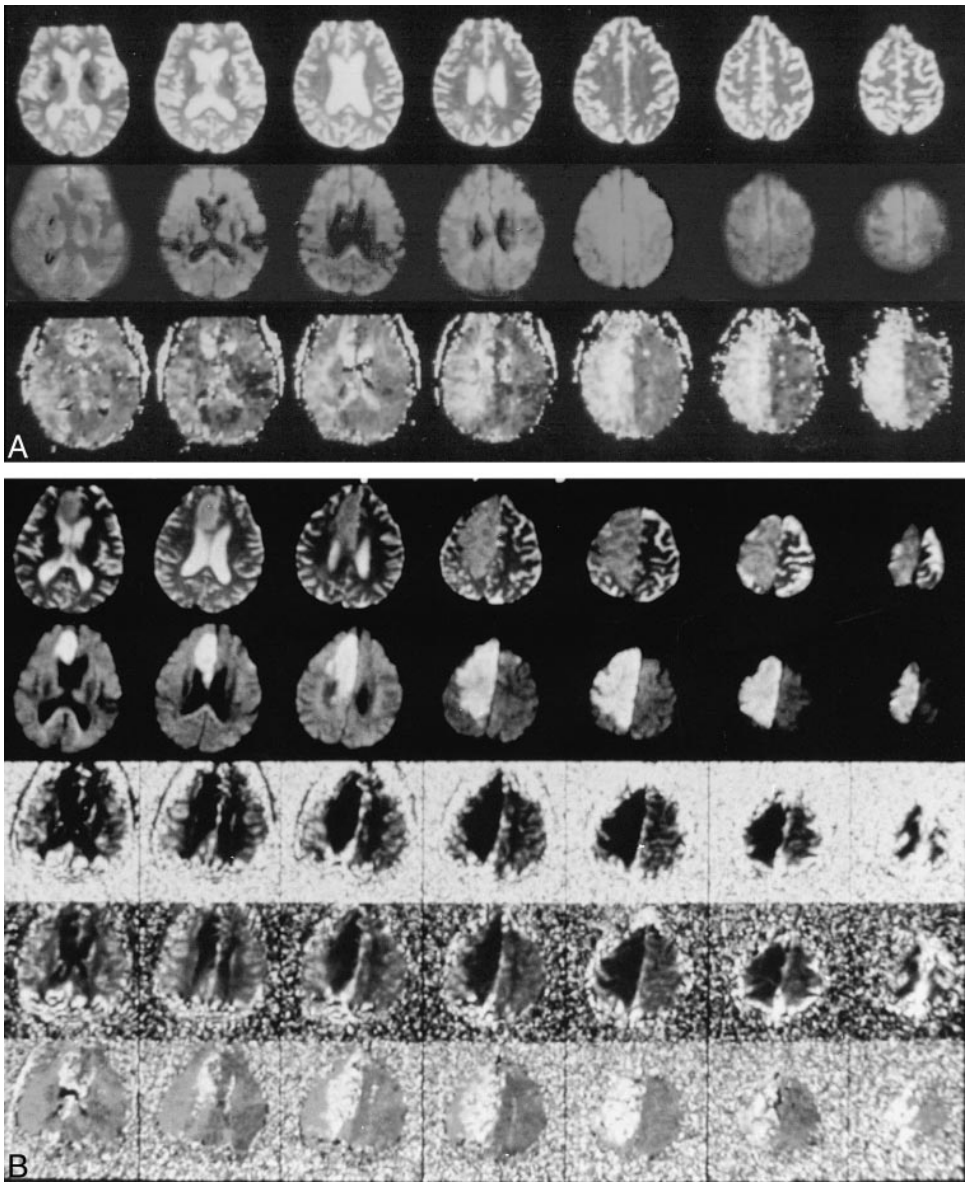

FIG 1. *A,* T2-weighted (*top*), diffusion-weighted (*middle*), and perfusion-weighted (TTP) (*bottom*) images obtained 2.5 hours after onset of symptoms. T2 and diffusion findings are negative, but profound perfusion abnormality (hyperintensity) of the right hemisphere is shown.

B, 3-day follow-up T2-weighted (*top*), diffusion-weighted (*middle*), and perfusion-weighted (*bottom*) images (rCBV, max ΔR2*, and TTP) show large right anterior and middle cerebral artery infarctions.

(Courtesy of Michael E. Moseley, Stanford University.)

and prediction of infarction (9, 10, 21–25). Are we satisfied with these prior reports or have we ''overrated'' the efficacy of diffusion-weighted imaging in the diagnosis of acute stroke as judged by the ''gold standard'' set up by early investigators? Despite the high sensitivity of diffusion-weighted imaging for the detection of ischemia, the clinical or bedside diagnosis of acute stroke by the clinician without the aid of diagnostic imaging has been excellent. Von Arbin et al (43) prospectively evaluated 2252 patients who had been admitted to a medicine department and found that stroke was clinically diagnosed with a sensitivity of 86% and a specificity of 99%. They point out that their bedside diagnosis of stroke could have had a sensitivity of 97% and specificity of 100% had clinical criteria been adhered to more strictly. Several other studies have also analyzed the accuracy of the bedside diagnosis of stroke. In seven such studies (44–50), a total of 2213 patients were given the diagnosis of stroke based on clinical information with a sensitivity of 90.2% (range, 81%–98.5%). Clearly there is variability in the sensitivity of the bedside diagnosis of stroke, but an expert clinician usually can make a correct diagnosis with high accuracy. Therefore, the real contribution of diffusion-weighted imaging thus far has been early confirmation of the clinician's suspicion of acute stroke,

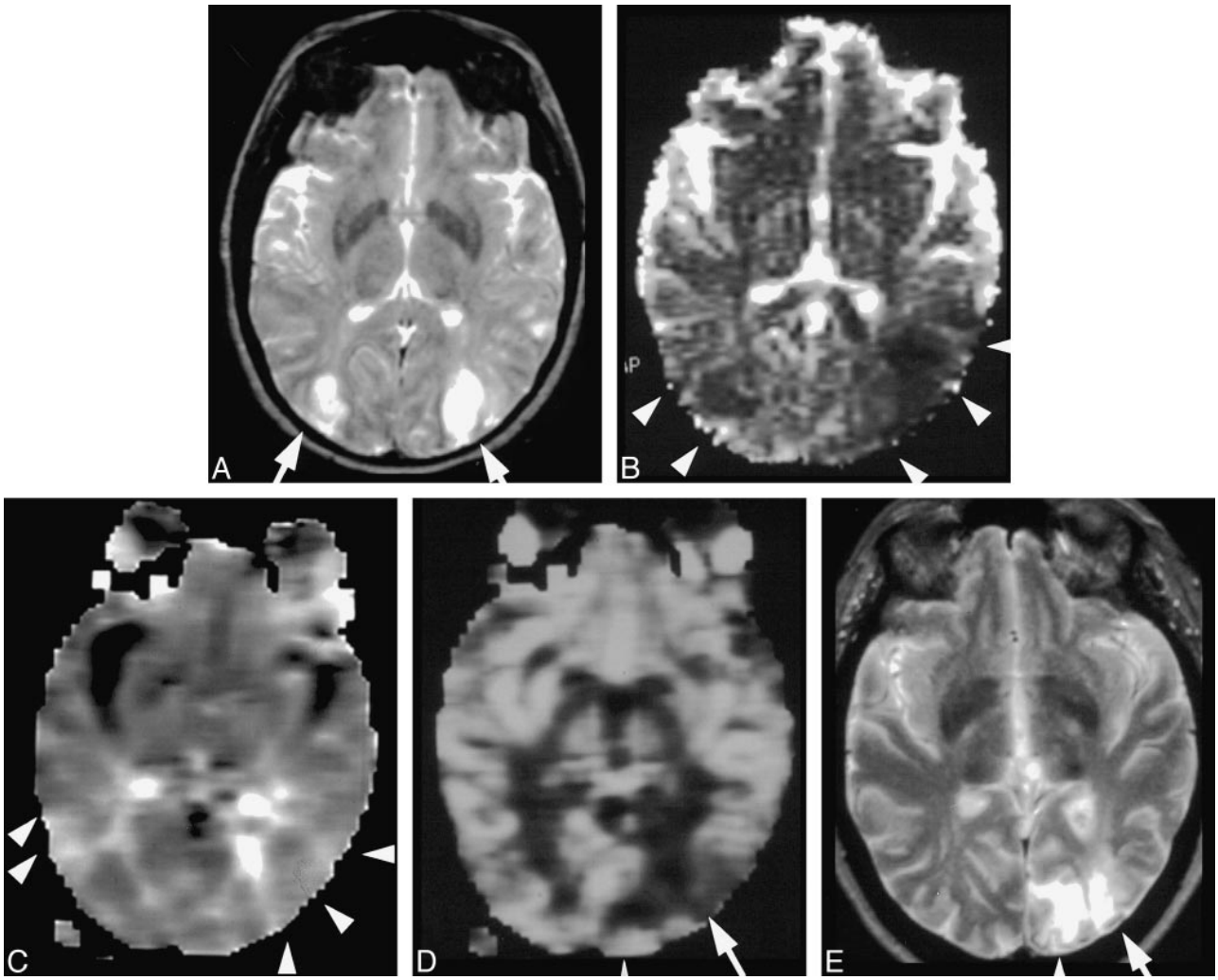

FIG 2. 72 hours after the onset of stroke symptoms in a patient with vasculitis.

A, T2-weighted MR image shows bilateral posterior watershed lesions (*arrows*).

B, The ADC map also shows bilateral posterior watershed lesions (*arrowheads*), but both lesions are larger than those seen on T2-weighted images (*A*).

C, The rMTT map shows hypoperfusion (hyperintensity) of both posterior watershed territories (*arrowheads*).

D, The rCBV map shows only a left-sided lesion (*arrow*), including posterior watershed and part of the posterior cerebral artery territory (*arrowhead*).

E, The 16-month follow-up T2-weighted image confirmed small left posterior watershed infarction (*arrow*) and new infarction at the territory of the left posterior cerebral artery (*arrowhead*), which was not apparent on initial T2-weighted image (*A*) or ADC map (*B*) but was partially visible on rCBV map (*D*). The abnormality of the right posterior watershed area initially demonstrated on the T2-weighted image (*A*) and ADC map (*B*) did not develop into infarction (*E*). It was accurately predicted by the rCBV map whereas the T2-weighted image and ADC map were falsely positive. The left posterior cerebral artery infarction (*arrowhead*) was partially diagnosed by the rCBV map, but the ADC map and T2-weighted images were falsely negative.

(Permission granted from the AJNR 20:983–989, June/July 1999)

particularly within the first 6 hours of symptom onset, in the vast majority of cases.

In addition, the capability of predicting infarction size has been reported to be different with different diffusion-weighted imaging techniques (20, 26, 51). Furthermore, prior reports suggested that ischemic penumbra (reversible ischemia) can be assessed by perfusion-, or diffusion-weighted imaging, or both, based upon untreated patients (24, 52, 53). Nonetheless, the definition of penumbra is ischemic tissue at risk that is potentially reversible (reversibility) only if early recanalization occurs (ie, in treated patients). Without early and successful treatment, the penumbra will become infarcted and therefore cannot be adequately assessed in the untreated patient population, as was done in prior reports. The penumbra cannot be differentiated from the dead (nonviable) and irreversibly damaged tissues by comparing the perfusion-weighted imaging findings obtained during acute ischemia with the follow-up study. Despite that diffusion-weighted imaging has high sensitivity and specificity for acute stroke in the untreated patient, its efficacy in the assessment of tissue viability and reversibility, particularly for early intervention, has not been established (5, 18, 26, 54–56). Diffusion-

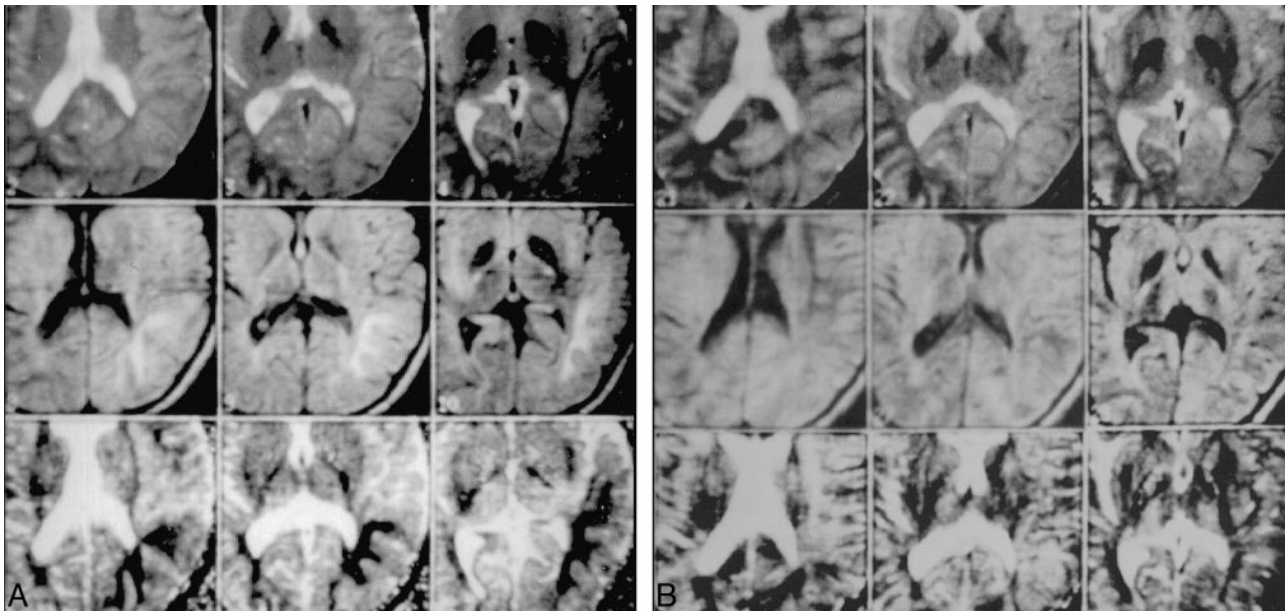

FIG 3. *A,* T2-weighted (*top*) and diffusion-weighted (*middle*) as well as ADC map (*bottom*) obtained 11 hours after onset of symptoms show normal T2 and abnormal diffusion (*hyperintensity*). ADC findings (*hypointensity*) are in the left parietal lobe of the ADC map.

B, T2-weighted (*top*) and diffusion-weighted images (*middle*) and ADC map (*bottom*) obtained 35 hours after onset of symptoms show disappearance of the abnormality previously noted on diffusion-weighted image and ADC map obtained at 11 hours (*A*) and persistent normal T2. These imaging findings are consistent with the resolution of clinical symptoms.

(Courtesy of Michael E. Moseley, Stanford University.)

weighted imaging has been reported to overestimate (Figs 2–3) (18, 55, 57, 58) or underestimate infarction (Figs 1–2) (21, 24, 51), as demonstrated in the two articles by Wang et al and Lefkowitz et al. In addition, reversal of the diffusion abnormality has been reported after thrombolysis of acute ischemic stroke (54).

Acute ischemia involves rather complex and dynamic pathophysiologic processes. For imaging purposes, it can be divided into three sequential (time-dependent) pathophysiologic processes. The imaging findings depend upon the time of onset as well as the predominant underlying pathophysiology when the imaging is obtained. The temporal changes in the underlying pathophysiology of acute cerebral ischemia can be generalized into three sequential stages: 1) flow abnormalities; 2) cellular dysfunction; and 3) structural breakdown (19–20, 36, 37). Flow abnormality is a kinetic phenomenon that can be detected immediately (19, 20). Perfusion-weighted imaging, therefore, is likely to provide the earliest and most direct imaging information about the regional cerebral blood flow (CBF) that causes ischemia even at the microcirculatory level. As time proceeds, the diminished CBF results in cellular dysfunction as a result of Na^+-ATP pump failure. This causes abnormal water shifts (diffusion abnormality) and abnormal accumulations of lactate (spectroscopic abnormality). Therefore, both diffusion-weighted imaging and spectroscopy provide early biological signs of ischemia indirectly, reflecting the underlying flow abnormality, and may not be specific for ischemia (59–60). These changes require time (ie, usually a few hours after onset of symptoms) to accumulate sufficient changes to be appreciated by imaging. This, in part, may explain initial negative diffusion findings and positive perfusion findings in both Lefkowitz et al's and Wang et al's articles. Finally, blood brain–barrier breakdown, a structural disruption, occurs approximately 6 hours after onset of ischemia and allows intravascular content to extravasate into the extracelluar space, which then can be detected by T2-weighted fluid-attenuated inversion-recovery imaging (19–20).

The question of what has contributed to diffusion abnormalities has been long debated. Most popular hypotheses involve ''abnormal water movement'' related to ''cytotoxic edema'' (61–66). Although many studies that have investigated where these water molecules circulate and how much cytotoxic edema is involved, definitive proof for the basis of the diffusion abnormality has not yet been established. Currently, there has been more work done on evaluating water molecule movement and cytotoxic edema during acute stroke than on obtaining crucial information regarding the status of the collateral circulation for acute patient management. Nevertheless, the status of tissue blood flow (ie, the severity and duration of ischemia), the fundamental underlying pathophysiologic process influenced by collateral circulation, is more important in the microenvironmental emergency management of patients than the oft-cited ''cytotoxic edema'' and is more influential for the treatment outcome in acute stroke.

In contrast to most beliefs, diffusion-weighted imaging can provide false-negative (Figs 1–2) or

false-positive (Figs 2–3) information regarding infarction because of the complex and dynamic process of acute stroke, heterogeneity of imaging techniques (such as different b-values), and sensitivity to hypoperfusion (18, 21, 26–30, 57, 58). Different imaging techniques provide different types of information reflecting the CBF in the previously mentioned three sequential pathophysiologic processes, and have different sensitivities to degree of hypoperfusion. CBF of normal brain parenchyma ranges from 45–110 cc/100gm/min, and varies with time and location in the same individual. Within the range of hypoperfusion, it includes oligoemia (in asymptomatic patients) and ischemia (in symptomatic patients) (67–68). The CBF threshold of ischemia (ischemic threshold) is generally believed to be around 20 cc/100 gm/min. The ischemic parenchyma is believed to suffer from infarctions quickly if the CBF is below 10 cc/100 gm/min (infarction threshold). CBF between 10–20 cc/100 gm/min is generally considered reversible ischemia, and parenchyma with CBF in this range is called penumbra.

The abnormal findings demonstrated by diffusion-weighted imaging and spectroscopy have been reported to be associated with a CBF threshold above the ischemic range (ie, oligoemia). In one animal study of diffusion MR imaging in global ischemia, Busza et al (7) reported a slight increase in signal at $20 < \text{CBF} < 30$ mL/100 g/min and a sharp increase in signal at CBF $<$ 15–20 mL/100 g/min. Although the apparent diffusion coefficient (ADC) value is sensitive to change in CBF, it is a function of a number of variables, of which CBF is one. Kohno et al (8) reported regional correspondence of hyperintensity in diffusion-weighted imaging, with perfusion deficits at CBF thresholds of 34 mL/100 g/min after 30 minutes and 41 mL/100 g/min after 2 hours of middle cerebral artery occlusion. Their reports suggest that the threshold for ADC changes at a given CBF depends on the duration of ischemia. Therefore, abnormalities revealed by these imaging techniques are not always specific for ischemia or indicative of infarction (5, 18, 54, 56–60).

In conclusion, Wang and colleagues and Lefkowitz and colleagues amplify the need for re-examination of the capabilities and limitations of new techniques, including those of diffusion-weighted imaging. The analysis should include not only untreated but also treated patients, particularly in the assessment of viability and reversibility. Diffusion- and perfusion-weighted imaging should be used simultaneously and interpreted with caution for the expanding clinical needs of stroke imaging. The future holds real excitement and challenges us to provide valuable information to salvage ischemic tissue promptly.

Acknowledgments

I would like to express my special thanks for the expert input from Drs. Michael E. Mosley, Stanford University, and Joan E. Maley, University of Iowa.

References

1. The National Institute of Neurological Disorders and Stroke rt-PA Stroke Study Group. **Tissue plasminogen activator for acute ischemic stroke.** *N Engl J Med* 1995;333:1581–1587
2. del Zoppo GJ, Higashida RT, Furlan AJ, et al. **PROACT: a phase II randomized trial of recombinant pro-urokinase by direct arterial delivery in acute middle cerebral artery stroke.** *Stroke* 1998;29:4–11
3. Furlan AJ, Higashida R, Wechsler L, Schlz G. **PROACT II Investigators. PROACT II: Prourokinase (r-ProUK) in acute cerebral thromboembolism: initial trial results.** *Stroke* 1999;30:–234
4. Ueda T, Hatakeyama T, Kumon Y, Sakaki S, Uraoka T. **Evaluation of risk of hemorrhagic transformation in local intra-arterial thrombolysis in acute ischemic stroke by initial SPECT.** *Stroke* 1994;25:298–303
5. Ueda T, Sakaki S, Yuh WTC, Nochide I, Ohta S. **Outcome in acute stroke with successful intra-arterial thrombolysis and predictive value of initial single-photon emission-computed tomography.** *J Cereb Blood Flow Metab* 1999;19:99–108
6. Moseley M, Cohen Y, Mintorovitch J, et al. **Early detection of regional cerebral ischemia in cats: comparison of diffusion- and T2-weighted MRI and spectroscopy.** *Magn Reson Med* 1990;14:330–346
7. Busza AL, Allen KL, King MD, van Bruggen N, Williams SR, Gadian DG. **Diffusion-weighted imaging studies of cerebral ischemia in gerbils. Potential relevance to energy failure.** *Stroke* 1992;23:1602–1612
8. Kohno K, Hoehn-Berlage M, Mies G, Back T, Hossmann KA. **Relationship between diffusion-weighted MR images, cerebral blood flow, and energy state in experimental brain infarction.** *Mag Res Imag* 1995;13:73–80
9. Lövblad KO, Laubach HJ, Baird AE, et al. **Clinical experience with diffusion-weighted MR in patients with acute stroke.** *AJNR Am J Neuroradiol* 1998;19:1061–1066
10. Gonzalez RG, Schaefer PW, Buonanno FS, et al. **Diffusion-weighted MR imaging: diagnostic accuracy in patients imaged within 6 hours of stroke symptom onset.** *Radiology* 1999;210:155–162
11. Lövblad K, Baird A, Schlaug G, et al. **Ischemic lesion volumes in acute stroke by diffusion-weighted magnetic resonance imaging correlate with clinical outcome.** *Ann Neurol* 1997;42:164–170
12. van Everdingen KJ, van der Grond J, Kappelle LJ, Ramos LMP, Mali WPTM. **Diffusion-weighted magnetic resonance imaging in acute stroke.** *Stroke* 1998;29:1783–1790
13. Schlaug G, Siewert B, Benfield A, Edelman R, Warach S. **Time course of the apparent diffusion coeffient (ADC) abnormality in human stroke.** *Neurology* 1997;49:113–119
14. Bryan RN. **Diffusion-weighted imaging: to treat or not to treat? That is the question.** *AJNR Am J Neuroradiol* 1998;19:396–397
15. Powers WJ, Zivin J. **Magnetic resonance imaging in acute stroke: not ready for prime time.** *Neurology* 1998;50:842–843
16. Davis D, Ulatowski J, Eleff S, et al. **Rapid monitoring of changes in water diffusion coefficients during reversible ischemia in cat and rat brain.** *Magn Reson Med* 1994;31:454–460
17. Miyabe M, Mori S, van Zijl PCM, et al. **Correlation of the average water diffusion constant with cerebral blood flow and ischemic damage after transient middle cerebral artery occlusion in cats.** *J Cereb Blood Flow Metab* 1996;16:881–889
18. Ueda T, Yuh WTC, Maley JE, Quets JP, Hahn PY, Magnotta VA. **Outcome of acute ischemic lesions detected by diffusion and perfusion MR imaging.** *AJNR Am J Neuroradiol* 1999;20:983–989
19. Maeda M, Maley J, Crosby D, et al. **Application of contrast agents in the evaluation of stroke: conventional MR and echo-planar MR imaging.** *JMRI* 1997;7:23–28
20. Maeda M, Yuh WTC, Ueda T, et al. **Severe occlusive carotid artery disease: hemodynamic assessment by MR perfusion imaging in symptomatic patients.** *AJNR Am J Neuroradiol* 1999;20:43–51
21. Tong DC, Yenari MA, Albers GW, O' Brien M, Marks MP, Moseley ME. **Correlation of perfusion and diffusion-weighted MRI with NIHSS score in acute (<6.5 hr) ischemic stroke.** *Neurology* 1998;50:864–869
22. Warach S, Gaa J, Siewert B, Wielopolski P, Edelman RR. **Acute human stroke studied by whole brain echo planar diffusion-weighted magnetic resonance imaging.** *Ann Neurol* 1995;37:231–241

23. Warach S, Dashe JF, Edelman RR. **Clinical outcome in ischemic stroke predicted by early diffusion-weighted and perfusion magnetic resonance imaging: a preliminary analysis.** *J Cereb Blood Flow Metab* 1996;16:53–59
24. Sorensen AG, Buonanno FS, Gonzalez RG, et al. **Hyperacute stroke: evaluation with combined multisection diffusion-weighted and hemodynamically weighted echo-planar MR imaging.** *Radiology* 1996;199:391–401
25. Singer MB, Chong J, Lu D, Schonewille WJ, Turhim S, Atlas SW. **Diffusion-weighted MRI in acute subcortical infarction.** *Stroke* 1998;29:133–136
26. Yuh WTC, Maeda M, Wang AM, et al. **Fibrinolytic treatment of acute stroke: are we treating reversible cerebral ischemia?** *AJNR Am J Neuroradiol* 1995;16:1994–2000
27. Ueda T, Yuh WTC, Maley JE, et al. **Evaluation of reversibility of acute ischemic lesions detected by perfusion MR imaging.** Presented at: the 37th Annual Meeting of American Society of Neuroradiology; May, 1999; San Diego, CA
28. Tong DC, Yenari M, O' Brien MW, et al. **Perfusion MRI time to peak (TTP) map compared with diffusion MRI and clinically apparent neurologic deficit in hyperacute stroke.** Presented at: the American Heart Association 22nd International Joint Conference on Stroke and Cerebral Circulation; February 6–8, 1997; Anaheim, CA
29. Ay H, Buonanno FS, Sorensen G, et al. **Negative diffusion-weighted MR imaging (DWI) with stroke-like focal deficits.** Presented at: the American Heart Association 23rd International Joint Conference on Stroke and Cerebral Circulation; February 5–7, 1998; Orlando, FL
30. Warach S, Edelman RR. **On the sensitivity and specificity of diffusion weighted imaging for acute stroke: analysis of 122 cases.** Presented at: the American Society of Neuroradiology 34th Annual Meeting; June 23–27, 1996; Seattle, WA
31. Kucharczyk J, Chew W, Derugin N, et al. **Nicardine reduces ischemic brain injury: magnetic resonance imaging/spectroscopy study in cats.** *Stroke* 1989;20:268–273
32. del Zoppo GJ, Zeumer H, Harker LA. **Thrombolytic therapy in acute stroke: possibilities and hazards.** *Stroke* 1986;17:595–607
33. Ginsberg MD, Budd WW, Welsh FA. **Diffuse cerebral ischemia in the cat. 1. Local blood flow during severe ischemia and recirculation.** *Ann Neurol* 1978;3:482–492
34. Kagstrom E, Smith M-L, Siesjo BK. **Recirculation in the rat brain following incomplete ischemia.** *J Cereb Blood Flow Metab* 1983;3:183–192
35. Miller CL, Lampard DG, Alexander K, et al. **Local cerebral blood flow following transient cerebral ischemia. 1. Onset of impaired reperfusion within the first hour following global ischemia.** *Stroke* 1980;11:534–541
36. Yuh WTC, Loes DJ, Greene GM, et al. **MR imaging of cerebral ischemia: findings in the first 24 hours.** *AJNR Am J Neuroradiol* 1991;12:621–629
37. Crain MR, Yuh WTC, Greene GM, et al. **Cerebral ischemia: evaluation with contrast-enhanced MR imaging.** *AJNR Am J Neuroradiol* 1991;12:631–639
38. Elster AD, Moody DM. **Early cerebral infarction: gadopentate dimeglumine enhancement.** *Radiology* 1990;177:626–632
39. Sato A, Takahashi S, Soma Y, et al. **Cerebral infarction: early detection by means of contrast-enhanced cerebral arteries at MR imaging.** *Radiology* 1991;178:433–439
40. Yuh WTC, Crain MR. **Magnetic resonance imaging of acute cerebral ischemia.** *Neuroimaging ClinNorth Am* 1992;2:421–427
41. Mueller DP, Yuh WTC, Chandran KB, et al. **MRI arterial enhancement in acute ischemic stroke: a correlation of angiographic findings and in-vitro experience.** Presented at: the 29th annual meeting of the American Society of Neuroradiology; June, 1991
42. Jones T, Morawetz R, Crowell R, et al. **Thresholds of focal cerebral ischemia in awake monkeys.** *J Neurosurg* 1981;54:773–782
43. von Arbin M, Britton M, de Faire U, Helmers C, Miah K, Murray V. **Validation of admission criteria to a stroke unit.** *J Chron Dis* 1980;33:215–220
44. Britton M, Hindmarsh T, Murray V, Tyden SA. **Diagnostic errors discovered by CT in patients with suspected stroke.** *Neurology* 1984;34:1504–1507
45. Kinkel WR, Jacobs L. **Computerized axial transverse tomography in cerebrovascular disease.** *Neurology* 1976:924–930
46. Norris JW. **Misdiagnosis of stroke.** *Lancet* 1982;1:328–331
47. Libman RB, Wirkowski E, Alvir J, Rao TH. **Conditions that mimic stroke in the emergency department.** *Arch Neurol* 1995;52:1119–1122
48. Sandercock P, Molyneux A, Warlow C. **Value of computed tomography in patients with stroke: Oxfordshire community stroke project.** *BMJ* 1985:193–197
49. Allen CMC. **Clinical diagnosis of the acute stroke syndrome.** *Q J M* 1983;208:515–523
50. von Arbin M, Britton M, de Faire U, Helmers C, Miah K, Murray V. **Accuracy of bedside diagnosis in stroke.** *Stroke* 1981;12:288–293
51. Rordorf G, Koroshetz WJ, Copen WA, et al. **Regional ischemia and ischemic injury in patients with acute middle cerebral artery stroke as defined by early diffusion-weighted and perfusion-weighted MRI.** *Stroke* 1998;29:939–943
52. Kucharczyk J, Mintorovitch J, Asgari HS, **MEM. Diffusion/perfusion MR imaging of acute cerebral ischemia.** *Magn Reson Med* 1991;19:311–315
53. Sorenson AG, Copen WA, Ostergaard L, et al. **Hyperacute stroke: simultaneous measurement of relative cerebral blood volume, relative cerebral blood flow, and mean tissue transit time.** *Radiology* 1999;210:519–527
54. Jahan R, Kidwell SC, Alger JR, et al. **Reversibility of abnormal diffusion MR imaging postthrombolysis for acute ischemic stroke.** Presented at: the 37th Annual Meeting of American Society of Neuroradiology; May, 1999; San Diego, CA
55. Kidwell CS, Alger JR, Di Salle F, et al. **Diffusion MRI in patients with transient ischemia attacks.** *Stroke* 1999;30:1174–1180
56. Sunshine JL, Tarr RW, Lanzieri CF, Landis DMD, Selman WR, Lewin JS. **Hyperacute stroke: ultrafast MR imaging to triage patients prior to therapy.** *Radiology* 1999;212:325–332
57. Marks MP, de Crespigny A, Lentz D, Enzmann DR, Albers GW, Moseley ME. **Acute and chronic stroke: navigated spin-echo diffusion-weighted MR imaging.** *Radiology* 1996;199:403–408
58. Kidwell CS, Alger JR, Di Salle F, Starkman S, Villablanca P, Bentson J, Saver JL. **Diffusion MRI in patients with transient ischemic attacks.** *Stroke* 1999;30:1174–1180
59. Moritani T, Hirotsugu M, Takumi A, et al. **Diffusion-weighted echo-planar MR imaging: clinical applications and pitfalls.** Presented at: the 37th Annual Meeting of American Society of Neuroradiology; May, 1999; San Diego, CA
60. Burnette WC, Nesbit GM. **The differential diagnosis in diffusion-weighted imaging. Not everything that is white is stroke.** Presented at: the 37th Annual Meeting of American Society of Neuroradiology; May, 1999; San Diego, CA
61. Beauchamp NJ, Barker PB, Wang PY, van Zijl PCM. **Imaging of acute cerebral ischemia.** *Radiology* 1999;212:307–324
62. Benveniste H, Hedlund LW, Johnson GA. **Mechanisms of detection of acute cerebral ischemia in rats by diffusion-weighted magnetic resonance microscopy.** *Stroke* 1992;23:746–754
63. Norris DG, Niendorf TG, Leibfritz D. **Healthy and infarcted brain tissue studies at short diffusion times: the origins of apparent restriction and the reduction in apparent diffusion constant.** *NMR Biomed* 1994;7:304–310
64. Helpern JA, Ordidge RJ, Knight RA. **The effect of cell membrane water permeability on the apparent diffusion coefficients of water (abstract).** In: Program and abstracts of the ?? th annual meeting of the Society of Magnetic Resonance in Medicine;? month, 1992; Berkeley, CA:1201
65. Duong TQ, Ackerman JJH, Ying HS, Neil JJ. **Evaluation of extra and intracellular apparent diffusion in normal and intracellular apparent diffusion in normal and globally ischemic rat brains via 19F NMR.** *Magn Reson Med* 1998;40:1–13
66. van der Toorn A, Sykova EDRM, Vorisek I, et al. **Dynamic changes in water ADC, energy metabolism, extracellular space volume, and tortuosity in neonatal rat brain during global ischemia.** *Magn Reson Med* 1996;36:52–60
67. Obrenovitch TP. **The ischaemic penumbra: twenty years on.** *Cerebrovascular and Brain Metabolism Reviews* 1995;7:297–323
68. Furlan M, Marchal G, Viader F, Derlon J-M, Baron J-C. **Spontaneous neurological recovery after stroke and the fate of the ischemic penumbra. Spontaneous neurological recovery after stroke and the fate of the ischemic penumbra.** *Ann Neurol* 1996;40:216–226