

Are your **MRI contrast agents** cost-effective?

Learn more about generic **Gadolinium-Based Contrast Agents**.



FRESENIUS
KABI

caring for life

AJNR

**Radiologic and Histopathologic Evaluation of
Canine Artery Occlusion after Collagen-Coated
Platinum Microcoil Delivery**

Shinichi Tamatani, Tsunenori Ozawa, Takashi Minakawa,
Shigekazu Takeuchi, Tetsuo Koike and Ryuichi Tanaka

This information is current as
of April 17, 2024.

AJNR Am J Neuroradiol 1999, 20 (4) 541-545
<http://www.ajnr.org/content/20/4/541>

Radiologic and Histopathologic Evaluation of Canine Artery Occlusion after Collagen-Coated Platinum Microcoil Delivery

Shinichi Tamatani, Tsunenori Ozawa, Takashi Minakawa, Shigekazu Takeuchi, Tetsuo Koike, and Ryuichi Tanaka

BACKGROUND AND PURPOSE: Platinum coil embolization is one of the significant advances in interventional neuroradiologic techniques that has been introduced this decade. Our purpose was to evaluate the angiographic and histologic effects of collagen-coated platinum microcoil delivery in the canine artery.

METHODS: We embolized the bilateral internal maxillary arteries of 18 dogs; one uncoated and one collagen-primed coil was used in each dog. We evaluated all coils by angiography, macroscopy, and scanning electron microscopy within 30 minutes of embolization. We then studied a proportional number of coated and collagen-primed coils at either 1 or 3 days, or 1, 2, 3, 4, 8, 12, or 16 weeks postoperatively.

RESULTS: Six (33%) of 18 arteries embolized with uncoated coils were occluded 30 minutes after delivery, whereas 11 (61%) of 18 arteries treated with collagen-primed coils were occluded within 30 minutes of embolization. Late occlusion (3 weeks after embolization) occurred in 2 (25%) of 8 arteries embolized with untreated coils, and 6 (75%) of 8 arteries embolized with collagen-primed coils. We calculated differences in late occlusion rates by the χ^2 (chi-square) test, and found these differences were significant ($P=.04$). Histologic findings of arteries embolized with unprimed coils revealed endothelial cell growth was limited to the organized thrombi 4 weeks after coil delivery. In contrast, endothelial cells grew directly on the collagen-primed coils 3 days postoperatively, and coils were completely covered by endothelial cells within 2 weeks. We found an organized thrombus in the inner space of coils in angiographically occluded arteries, a finding that was not evident in angiographically patent arteries.

CONCLUSION: Collagen-coated platinum coils can produce rapid and stable occlusion of embolized vessels.

Significant advances have been achieved in the treatment of neurologic diseases with this decade's development of interventional neuroradiologic techniques (1, 2). The aim of cerebral aneurysmal coil embolization is to obtain complete organization of the aneurysmal lumen and complete endothelial coverage over the orifice of the aneurysm. Coil embolization, however, does not always result in permanent occlusion of aneurysms. Several investigators have found recurrent aneurysms in human studies employing Guglielmi detachable coils (GDCs) (1, 3-7) or fibered coils (7, 8), and in animal studies applying GDCs (7, 9) or fibered coils (10).

Research into the development of coil embolization as the optimal embolic agent for endovascular aneurysmal treatment continues (11, 12). Tamatani et al (11) found that endothelial cells proliferated on platinum coils when coils were primed with extracellular matrices, and type 1 collagen produced a significant outgrowth of endothelial cells on the surface of the platinum coils. In this preliminary in vivo study, we compared angiographic and histopathologic findings of canine arteries treated with collagen-coated platinum microcoils to vessels treated with uncoated platinum microcoils. We evaluated the endothelial cell growth in the vessel lumen after coil delivery by examining gross macroscopic features and by scanning electron microscopy.

Received in original form February 10, 1998; accepted after revision October 29.

From the Department of Neurosurgery, Brain Research Institute, Niigata University, Niigata, Japan.

Address reprint requests to Shinichi Tamatani, MD, Department of Neurosurgery, Brain Research Institute, Niigata University, 1-757, Asahimichi, Niigata 951-8585, Japan.

Methods

We used Interlocking Detachable Coils (IDCs) (Target Therapeutics, Fremont, CA) as endovascular embolic agents. The dimensions of the coils used were either 3 mm \times 6 cm or 2 mm \times 4 cm. An IDC is a platinum coil with a 0.015-inch

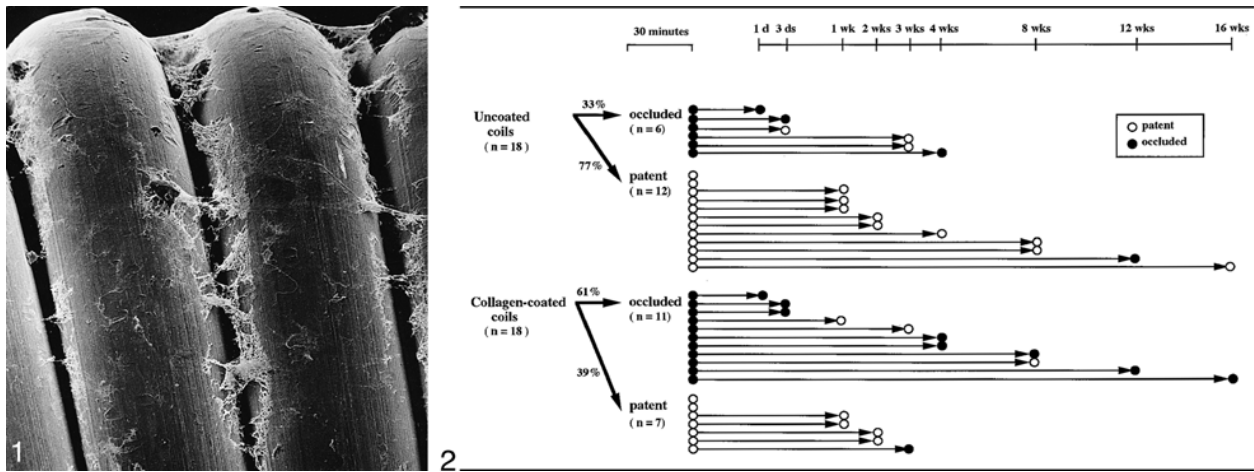


FIG 1. Scanning electron microscopic image of a collagen-coated platinum microcoil that was inserted into an internal maxillary canine artery via a Tracker 18 microcatheter (magnification $\times 430$). Most of the coil surface was covered with a thin layer of collagen.

FIG 2. Graphic representation of angiographic findings of 18 canine arteries treated with one uncoated and one collagen-primed coil. Angiography was performed 30 minutes postoperatively, and either 1 or 3 days, 1, 2, 3, 4, 8, 12, or 16 weeks after embolization.

diameter and a two-dimensional shape memory that is interlocked to a coil pusher.

We applied type 1 collagen solution to coat the IDCs. Type 1 collagen is derived from the swine tendon, and is mainly used for preparing cell cultures. We prepared the collagen solution by mixing 80% volume cold Cellmatrix collagen solution (3.0 mg/ml) (Cellmatrix®, Nitta, Osaka, Japan), 10% volume 10x Minimum Essential Medium (Nissui, Osaka, Japan), and 10% volume of 0.1N NaOH. We applied a thin layer of the collagen solution onto coils with an attached coil pusher, and then the coils were incubated at 37°C in a humidified atmosphere of 5% CO₂/95% air (20% O₂). Preliminary scanning electron microscopy, which we performed in our laboratory, confirmed that the collagen was intact after the coils were passed through a Tracker 18 microcatheter (Target Therapeutics) (Fig 1).

Young mongrel dogs weighing approximately 10 kg were used under a protocol approved by the Niigata University Animal Care Committee. Dogs were maintained in the Animal Care Facilities of Niigata University. Dogs were anesthetized with pentobarbital sodium (5 mg/kg), then a No. 4 French untapered angiographic catheter (Glidecath®, Terumo Inc., Tokyo, Japan) was positioned in the common carotid artery as a guiding catheter by a sterilized transfemoral approach. A Tracker 18 microcatheter was navigated into an internal maxillary artery through the guiding catheter, and arteries of 2–3 mm were chosen for occlusion. A collagen-primed platinum microcoil was advanced via a microcatheter into the chosen vessel, the microcatheter was released by unlocking from the coil pusher, and the vessel was occluded by dense packing. We then released an uncoated coil in the same manner in the contralateral internal maxillary artery of the same dog. Two coils (one collagen-primed, one uncoated) were delivered into the internal maxillary artery of each dog, a total of 36 coils (18 collagen-primed, 18 uncoated) in the vessels of 18 dogs. A single operator performed all embolizations, and did not use heparinization during the procedure.

We evaluated the patency of the arteries during the acute stage by angiography via the guiding catheter 30 minutes after coil delivery. We also evaluated patency of the arteries angiographically by another transfemoral catheterization just prior to sacrificing the dog (Fig 2).

We sacrificed the dogs in order to perform histologic evaluation of all 32 coils 30 minutes after embolization. Further histologic studies were performed in a proportional number of uncoated and collagen-primed coils at either 1 or 3 days, or 1, 2, 3, 4, 8, 12, or 16 weeks postoperatively. We also performed

transcardial perfusion with a 5-liter mixture of glutaraldehyde diluted in a sodium cacodylate buffer in order to obtain optimal fixation of vessels for scanning electron microscopic study. After performing in situ perfusion, the carotid arteries were removed, their gross features noted, and they remained in this medium for 5 days. Then they were postfixed in 1% osmium tetroxide, dehydrated in a graded series of ethanol solution, dried in CO₂ at the critical point, spattered with gold, and observed with a HITACHI S-450LB scanning electron microscope (Hitachi, Hitachi City, Japan). Specimens were examined on the proximal and distal ends of the coils, and the trans-sectional surface of the middle portion was also examined by cutting the artery with the coil inside.

Results

Angiographic Evaluation

Angiographic evaluation after coil delivery was performed to compare early occlusion, recanalization, and late occlusion rates between vessels treated with uncoated and those treated with collagen-primed coils. All angiographic results are summarized in Figure 2. Six (33%) of 18 arteries treated with unprimed coils were occluded within 30 minutes of embolization, whereas 11 (61%) of 18 arteries treated with collagen-primed coils were occluded after the same interval. Of those arteries that were occluded within 30 minutes, three (50%) of six were recanalized 3 weeks after uncoated coil placement (one in 3 days, two in 3 weeks). Recanalization, however, only occurred in two (18%) of eleven arteries within 3 weeks of the collagen-primed coil delivery (one in 1 week, one in 3 weeks). Two arteries that were occluded before sacrifice became patent 30 minutes after coil delivery: one of the 12 patent arteries treated with an unprimed coil and one of seven with collagen-primed coil in 3 weeks. The former again occluded 12 weeks after embolization, and the latter occluded within 4 weeks of delivery. Total late occlusion after 3 weeks occurred in two (25%) of eight un-

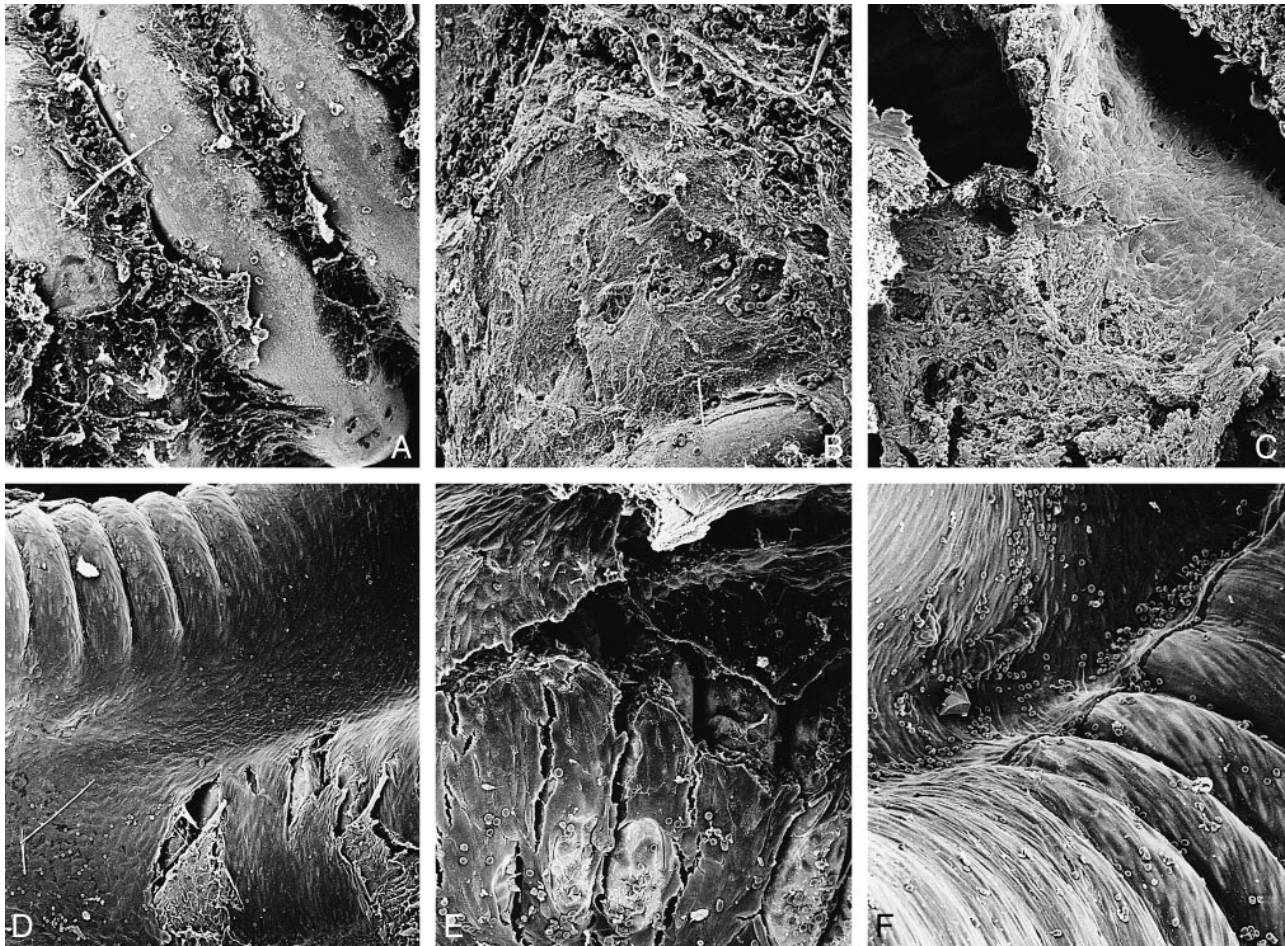


FIG 3. Scanning electron microscopic images of coils after embolization.

A, An uncoated platinum microcoil shows limited thrombic formation 30 minutes after delivery (magnification $\times 350$).

B, A collagen-coated platinum microcoil shows massive thrombic formation 30 minutes after delivery (magnification $\times 310$).

C, An uncoated platinum microcoil shows endothelial cells beginning to proliferate on the fibrous tissue formed on the coil within 1 week of embolization (magnification $\times 200$).

D, An uncoated platinum microcoil surface is completely covered with endothelial cells within 4 weeks of embolization. Organized tissue is seen under the endothelial cells (magnification $\times 160$).

E, A collagen-coated platinum microcoil surface is covered with endothelial cells within a week of embolization (magnification $\times 280$).

F, A collagen-coated platinum microcoil shows a typical mosaic pattern of flat, elongated, spindle-shaped endothelial cells throughout its surface 2 weeks after embolization (magnification $\times 290$).

coated coils, and in six (75%) of eight collagen-coated coils. Statistical significance of late occlusion rates was calculated by the χ^2 (chi-square) test. Arteries embolized with collagen-primed coils had a significantly higher late occlusion rate than uncoated coils ($P=.04$).

Macroscopic Findings

Two dogs were sacrificed 30 minutes after coil delivery. Although limited thrombic organization was observed on the proximal, distal and transectional surfaces of unprimed coils, massive thrombi were seen on all surfaces of collagen-primed coils. The same two dogs were examined 2 weeks after coil delivery. Proximal and distal surfaces of both collagen-primed coils were completely covered by a thin membrane; however, no membranous tissue was on any part of either uncoated coil. Membra-

nous tissue growth was first observed on proximal and distal surfaces of the unprimed coils 4 weeks after embolization.

Scanning Electron Microscopic Findings

Two dogs were sacrificed 30 minutes after embolization. Limited thrombic formation was observed on the surfaces and inner spaces of the two uncoated coils (Fig 3A); however, significant thrombic formation occurred immediately after embolization on the surfaces and inner spaces of the two collagen-primed coils (Fig 3B). Fibrous clot formation was seen on all uncoated coils 1 week after coil delivery, but occurred within 3 days on the two collagen-primed coils. Organized thrombi were first observed in the inner space of one of the two uncoated coils 4 weeks after delivery. On the other hand, highly organized thrombi occupied the

inner spaces of the collagen-primed coils in as early as 1 week after the procedure.

Endothelial cells began to proliferate on the fibrous tissue formed on both of the uncoated coils 1 week after delivery (Fig 3C). Three weeks later, the treated part of the proximal surface of both uncoated coils were covered with endothelial cells, but cells only proliferated on the fibrous tissue formed on the coils. Four weeks after delivery both uncoated coils were covered with endothelial cells and had a bulky appearance (Fig 3D). Endothelial cells proliferated directly on the surface of the collagen-primed coils 3 days postoperatively, and the coil surface was covered by endothelial cells 1 week after surgery (Fig 3E). The proximal and distal surfaces of the collagen-primed coils were completely covered by endothelial cells 2 weeks after delivery (Fig 3F).

A marked difference was noted between angiographically occluded and patent arteries. Although occluded and patent arteries had similar thrombic formation and endothelial coverage on the surface of the coils, there were no organized thrombi in the inner space of either type of coil in angiographically patent arteries.

Discussion

Microcoil embolization for cerebral aneurysms requires precise evaluation of the occlusive processes related to the aneurysmal lumen, such as the cellular reaction, thrombic formation, and fibrinolytic changes occurring after coil placement. Although a number of investigations report angiographic results of long-term occlusion in experimental aneurysms treated with platinum coils (7, 9, 10, 13–16), few evaluate early histologic changes after coil delivery (16).

Platinum coils have been used for the endovascular occlusion of aneurysms because they promote the thrombic formation that leads to fibrosis in the aneurysmal lumen. Nevertheless, a thrombus is composed of biologically dynamic material that is prone to lysis. This may be why several clinical (1, 3–6, 8, 17) and experimental (7, 10) reports have demonstrated recanalization of aneurysmal lumens after coil embolization. These studies comprised various models and embolic materials. Studies performed in human subjects have applied GDCs (1, 3–6, 8, 17), fibered coils (7, 10), or IDCs (18). Investigations in animal models have employed GDCs (7), fibered coils (8), or mechanical detachable coils (7). Platinum coils are biologically inert and therefore are lacking in thrombogenic properties. Some collagen preparations are thrombogenic (19, 20) and promote fibroblastic migration that transforms the thrombus into a stable fibrous scar (21–24). Furthermore, collagen can produce a significant outgrowth of endothelial cells (11), and is therefore considered an ideal embolic agent. We chose collagen for priming coils because of its thrombogenic properties.

In our study, complete angiographic occlusion was achieved in 6 (33%) of 18 arteries 30 minutes after the delivery of uncoated platinum microcoils, whereas 11 (61%) of 18 arteries embolized with collagen-coated microcoils resulted in angiographic occlusion within the same interval. The early formation of massive thrombi might indicate that collagen-primed coils have a higher early occlusive effect.

Immediate thrombic formation may have several advantages for vessel occlusion. When aneurysms are embolized, early thrombic formation in the aneurysmal lumen will prevent recurrent rupture at an early stage. Thrombic formation, however, also has a disadvantage; a thrombus formed after collagen-primed coil delivery could lead to the occlusion of the distal artery. In order to prevent this unfortunate event, anticoagulant therapy may be useful until the coil surface is covered by endothelial cells.

Our results show that embolization with collagen-coated platinum microcoils reduced the recanalization rate of the initially occluded artery (60% recanalization with uncoated coils; 29% recanalization with collagen-primed coils). Stable angiographic occlusion (3 weeks postoperative) of arteries was observed in only two (25%) of the eight arteries that we treated with an uncoated coil. On the other hand, embolization with collagen-primed coils induced angiographic occlusion in six (75%) of eight arteries within the same interval; a significantly higher occlusive rate. Our scanning electron microscopic study of the transectional surface of the occluded vessels indicated that there were organized thrombi in the inner space of the coil, but not in the patent vessels. Vessels could be recanalized through the inner space of the coils. Our study also indicated that collagen-primed coils induced fibrosis as early as 1 week postoperatively, whereas fibrosis occurred in the uncoated coils within 2 weeks of embolization. It is likely that endothelial growth over the surface of the collagen-primed coil protected against fibrinolysis of the thrombi in the inner space of coils, reduced the recanalization rate, and produced a significantly higher rate of occlusion (13).

There are investigations describing histologic reactions after coil embolization in experimental aneurysms, and complete aneurysmal occlusion from complete endothelial cell coverage of the orifice (9, 10, 14–16, 25). Several authors, however, reported that complete occlusion could not be obtained in the experimental setting (7, 17). Most experimentally induced aneurysms are side-wall or venous-pouch, and perhaps the trauma caused by these surgical procedures may produce thrombosis and fibrosis of the aneurysms. We used a simple canine model, applying one uncoated and one collagen-primed coil in an isolated arterial lumen to evaluate the histologic reaction to coils. We believed this method created less artificial conditions for examining the *in vivo* reaction.

We observed the *in vivo* histologic changes occurring on the platinum microcoil by scanning electron microscopy. Our findings showed that plati-

num coil embolization resulted in a low rate of thrombosis. Collagen-primed coils promoted rapid and massive thrombotic formation in and around the coils, and accelerated endothelial cell coverage of the coil surface (coverage 3 days after embolization). Uncoated coils did not show endothelial coverage until 2 weeks after coil delivery. Collagen-primed coils induced thrombosis in the inner space of coils, promoted early endothelial coverage of the coil surface that protected the thrombi from fibrinolysis, and prevented recanalization of the vessels. These results demonstrate the effectiveness of collagen-coated coil as an embolic agent, especially for the treatment of aneurysms. Collagen-coated microcoils may also improve the endovascular treatment of other vascular diseases such as arteriovenous fistulas or for sinus packing of intractable dural arteriovenous fistulas.

We conducted a preliminary study of limited scope that was not designed to answer all questions related to the endovascular therapy of vascular disease. We address how to control the thrombogenic properties of collagen, but a number of questions remain about collagen-primed coil delivery for endovascular therapy in the human subject. Characteristics unique to different species should be evaluated. Our in vivo findings were consistent with our previous in vitro findings (11); both studies were based on the same canine models. Because human physiology differs from the more dynamic canine thrombolytic system (26), early thrombotic formation could be more stable in the human aneurysm. Second, precautions should be taken during coil priming in order to prevent viral or bacterial contamination during coil delivery (27). The collagen should be highly purified, nonpyrogenic, and telopeptide-free to avoid immunologic and inflammatory reactions (27–28). Autologous collagen may match these criteria.

Further research into the cellular response to coil embolization is essential, and will continue to advance endovascular surgery.

Acknowledgments

We would like to thank Kiyoshi Uesugi for his assistance with scanning electron photomicroscopy and Target Therapeutics Inc. for contributing platinum microcoils for our investigation.

References

1. Guglielmi G, Viñuela F, Duckwiler G, et al. **Endovascular treatment of posterior circulation aneurysms by electrothrombosis using electrically detachable coils.** *J Neurosurg* 1992;77:515–525
2. Marks MP, Chee H, Liddell RP, Steinberg GK, Panahian N, Lane B. **A mechanically detachable coil for the treatment of aneurysms and occlusion of blood vessels.** *AJNR Am J Neuroradiol* 1994;15:821–827
3. Guglielmi G, Viñuela F, Dion J, Duckwiler G. **Electrothrombosis of saccular aneurysms via endovascular approach. Part 2: preliminary clinical experience.** *J Neurosurg* 1991;75:8–14
4. Gurian JH, Martin NA, King WA, Duckwiler GR, Guglielmi G, Viñuela F. **Neurosurgical management of cerebral aneurysms following unsuccessful or incomplete endovascular embolization.** *J Neurosurg* 1995;83:843–853

5. Richling B, Bavinszki G, Gross C, Gruber A, Killer M. **Early clinical outcome of patients with ruptured cerebral aneurysms treated by endovascular (GDC) or microsurgical techniques.** *Intervent Neurodiol* 1995;1:19–27
6. Ronowden SA, Molyneux AJ. **Thrombosis in giant basilar tip aneurysms during coil embolization.** *AJNR Am J Neuroradiol* 1995;16:866–871
7. Spetzger U, Reul J, Weis J, Bertalanffy H, Thron A, Gilsbach JM. **Microsurgically produced bifurcation aneurysms in a rabbit model for endovascular coil embolization.** *J Neurosurg* 1996;85:488–495
8. Casasco AE, Aymard A, Gobin YP, et al. **Selective endovascular treatment of 71 intracranial aneurysms with platinum coils.** *J Neurosurgery* 1993;79:3–10
9. Mawad ME, Mawad JK, Cartwright J Jr, Gokaslan Z. **Long-term histopathological changes in canine aneurysm embolized with Guglielmi detachable coil.** *AJNR Am J Neuroradiol* 1995;16:7–13
10. Kwan ES, Heilman CB, Roth PA. **Endovascular packing of carotid bifurcation aneurysm with polyester fiber-coated platinum coils in a rabbit model.** *AJNR Am J Neuroradiol* 1993;14:323–333
11. Tamatani S, Ozawa T, Minakawa T, Takeuchi S, Koike T, Tanaka R. **Histological interaction of cultured endothelial cells and endovascular embolic materials coated with extracellular matrix.** *J Neurosurg* 1997;86:109–112
12. Murayama Y, Viñuela F, Suzuki Y, et al. **Ion implantation and protein coating of detachable coils for endovascular treatment of cerebral aneurysms: concepts and preliminary results in swine models.** *Neurosurgery* 1997;86:109–112
13. Dowson RC, Krisht AF, Barrow DL, Joseph GJ, Shengelaia GG, Bonner G. **Treatment of experimental aneurysms using collagen-coated microcoils.** *Neurosurgery* 1995;36:133–140
14. Graves VB, Partington CR, Rüfenacht DA, Rappe AH, Strother CM. **Treatment of carotid artery aneurysms with platinum coils: An experimental study in dogs.** *AJNR Am J Neuroradiol* 1990;11:249–252
15. Guglielmi G, Viñuela F, Sepetka I, Macellari V. **Electrothrombosis of saccular aneurysms via endovascular approach. Part 1: electrochemical basis, technical and experimental results.** *J Neurosurgery* 1991;75:1–7
16. Tenjin H, Fushiki S, Nakahara Y, et al. **Effect of Guglielmi detachable coils on experimental carotid artery aneurysms in primates.** *Stroke* 1995;26:2075–2080
17. Molyneux AJ, Ellison DW, Morris J, Byrne JV. **Histopathological findings in giant aneurysms treated with Guglielmi detachable coils.** *J Neurosurg* 1995;83:129–132
18. Ozawa T, Koike T, Takeuchi S, Tanaka R. **Scanning electron microscopic study of the migrated platinum coil after endovascular embolization of a giant cerebral aneurysm (letter).** *AJNR Am J Neuroradiol* 1998;19:594–595
19. DeLustro F, Condell RA, Nguym MA, McPherson JM. **A comparative study of the biological and immunological response to medical devices derived from dermal collagen.** *J Biomed Mater Res* 1986;20:93–107
20. Kuhn K. **The classical collagens type I, II, and III.** In: Kuhn K. *Structure and Function of Collagen Types.* Mayne R. and Burgeson RE, eds. London, England: Academic Press Inc;1987:1–42
21. Gauss-Müller V, Kleinman HK, Martin GR, Schiffmann E. **Role of attachment factors and attachment in fibroblast chemotaxis.** *J Lab Clin Med* 1980;96:1071–1079
22. Ross R. **The fibroblast and wound repair.** *Biol Rev* 1968;43:51–96
23. Ross R. **Wound healing.** *Sci Am* 1969;220:40–50
24. Tiollier J, Dumas H, Tardy M, Tayot JL. **Fibroblast behavior on gels on type I, III, and IV human placental collagens.** *Exp Cell Res* 1991;193:310–319
25. Dowson RC, Shemgelania GG, Krisht AF, Bonner GD. **Histologic effect of collagen-filled interlocking detachable coils in the ablation of experimental aneurysms in swine.** *AJNR Am J Neuroradiol* 1996;17:853–858
26. Cade JF, Robinson TF. **Coagulation and fibrinolysis in the dog.** *Can J Comp Med* 1975;39:296–298
27. Turjman F, Massoud TF, Vinters HV, et al. **Collagen microbeads: Experimental evaluation of an embolic agent in the rete mirabile of the swine.** *AJNR Am J Neuroradiol* 1975;39:296–298
28. De Lustro F, Dasch J, Keefe J, Ellingsworth L. **Immune responses to allogenic and xenogenic implants of collagen and collagen derivatives.** *Clin Orthop* 1990;260:263–279
29. Dupont D, Gravagna P, Albinet P, et al. **Biocompatibility of human collagen type IV in intracorneal implant.** *Cornea* 1989;8:251–258