

Are your **MRI contrast agents** cost-effective?

Learn more about generic **Gadolinium-Based Contrast Agents**.



FRESENIUS
KABI

caring for life

AJNR

Epidurography and Therapeutic Epidural Injections: Technical Considerations and Experience with 5334 Cases

Blake A. Johnson, Kurt P. Schellhas and Steven R. Pollei

AJNR Am J Neuroradiol 1999, 20 (4) 697-705

<http://www.ajnr.org/content/20/4/697>

This information is current as of April 17, 2024.

Epidurography and Therapeutic Epidural Injections: Technical Considerations and Experience with 5334 Cases

Blake A. Johnson, Kurt P. Schellhas, and Steven R. Pollei

BACKGROUND AND PURPOSE: Even in experienced hands, blind epidural steroid injections result in inaccurate needle placement in up to 30% of cases. The use of fluoroscopy and radiologic contrast material provides confirmation of accurate needle placement within the epidural space. We describe our technique and experience with contrast epidurography and therapeutic epidural steroid injections, and review the frequency of systemic and neurologic complications.

METHODS: Epidural steroid injections were performed in 5489 consecutive outpatients over a period of 5½ years by three procedural neuroradiologists. In 155 cases (2.8%), the injections were done without contrast material owing to either confirmed or suspected allergy. The remaining 5334 injections were performed after epidurography through the same needle. Patients and referring clinicians were instructed to contact us first regarding complications or any problem potentially related to the injection. In addition, the referring clinicians' offices were instructed to contact us regarding any conceivable procedure-related complications.

RESULTS: Only 10 patients in the entire series required either oral (n = 5) or intravenous (n = 5) sedation. Four complications (0.07%) required either transport to an emergency room (n = 2) or hospitalization (n = 2). None of the complications required surgical intervention, and all were self-limited with regard to symptoms and imaging manifestations. Fluoroscopic needle placement and epidurography provided visual confirmation of accurate needle placement, distribution of the injectate, and depiction of epidural space disease.

CONCLUSION: Epidurography in conjunction with epidural steroid injections provides for safe and accurate therapeutic injection and is associated with an exceedingly low frequency of untoward sequelae. It can be performed safely on an outpatient basis and does not require sedation or special monitoring.

The use of epidural injections for the treatment of back and/or radicular pain was described by Evans in 1930 (1). The procedure has been traditionally performed using a blind technique without fluoroscopic guidance, as described by Barry and Kendal (2). The blind interlaminar technique introduces the potential for erroneous needle placement and subsequent injection of substances into undesired locations, such as the subarachnoid space. White and coworkers (3, 4) found that inaccurate needle placement occurred in 25% to 30% of injections, even in the hands of skilled and experienced proceduralists. The documentation of accurate delivery of therapeutic injectate is crucial with respect to the

safety and efficacy of this procedure. The potential complications of intrathecal steroid injections, such as adhesive arachnoiditis, have been well described (5, 6). In addition, even with negative needle aspiration, a significant number of injections following blind needle placement have been shown to be intravascular (3, 7).

Because of the high rate of erroneous needle placement associated with blind techniques, there has been movement toward fluoroscopically guided injections and epidurography to document accurate needle placement and to evaluate the epidural space before the instillation of therapeutic substances (8-13). Injecting variable amounts of radiologic contrast material under direct fluoroscopic observation, with filming (epidurography), before therapeutic injection provides improved safety and efficacy as compared with blind techniques (7). The risk of unintended intrathecal injection and its consequences can be virtually eliminated. Moreover, the practice of second and third steroid injections as a

Received September 11, 1998; accepted after revision November 30.

From the Center for Diagnostic Imaging, 5775 Wayzata Blvd, Suite 190, St Louis Park, MN 55416.

Address reprint requests to Blake A. Johnson, MD.

© American Society of Neuroradiology

routine series (to assess efficacy) becomes unnecessary. We recount our experience with 5334 procedures in which epidurography was used immediately before and after epidural steroid injection, describe the technique of this relatively painless procedure, and present the complications we encountered.

Methods

A total of 5489 patients (aged 16–93 years) underwent lumbar (4780), cervical (669), or thoracic (40) epidural steroid injections performed by any one of three experienced procedural neuroradiologists during a 5½-year period. Cases in which contrast material was not used because of either confirmed or possible contrast or iodinated compound allergy ($n = 155$) were excluded from this review. The remaining 5334 epidural steroid injections, which form the basis for this study, were preceded by epidural injection of nonionic, low-osmolar contrast material and followed by filming in at least two projections immediately before and after steroid instillation through the same needle. Sedation and cardiac monitoring of patients were only rarely performed in this series (10 cases total: five oral and five intravenous sedations with diazepam).

Patient Selection

Patients were referred for epidural steroid injection by experienced clinicians (most commonly, orthopedic spine surgeons and neurosurgeons) to an independent third-party group of three procedural neuroradiologists with no economic affiliation with the referral group. All patients had undergone a thorough medical history and physical examination before referral. Patients suffered from back or neck pain with or without radiculopathy. Although it was not a requirement, a majority of patients had undergone CT and/or MR imaging before the procedure. All available imaging studies were reviewed by the proceduralist before injections were administered. Patients were informed of potential risks associated with the procedure and with use of steroids before signing a consent form. Patients also completed a pain diagram and questionnaire relating to the distribution of their symptoms. If there was pure radicular pain in a particular nerve root distribution, a transforaminal approach at the appropriate level was generally used. Sacrococcygeal distribution of pain on rare occasions prompted a caudal (sacral hiatus) approach, although an S1 (or less frequently an S2) transforaminal placement was used more commonly for such patients, especially when symptoms were unilateral. An interlaminar technique at L3, L4, or L5 was used for most patients who primarily had back pain, depending on individual circumstances.

Injection Technique

Interlaminar Lumbar Epidural Injection.—The patient is placed in a prone position on a fluoroscopy table and the target spinal osseous anatomy is assessed with the use of a multidirectional, high-resolution, C-arm apparatus. If an imaging study (CT or MR) is available, assessment of epidural anatomy facilitates the choice of site for needle placement. The injection is ideally targeted to the level of greatest disease and pain symptoms, unless there are mitigating circumstances, such as stenosis, prior surgical scarring, instrumentation, or fusion, that direct the proceduralist to an alternative injection site. The intended puncture site is initially marked on the skin using a radiopaque marker with the C-arm unit in the appropriate orientation (approximately 15° caudal and lateral angulation). The skin is then prepped in a sterile fashion using povidone-iodine (Betadine) followed by an alcohol rinse, after which a fenestrated drape is applied. Local anesthetic (1% lidocaine) is gen-

erally not needed and is only rarely injected subcutaneously. Two slightly different techniques for interlaminar needle introduction are used in our practice.

Technique 1: Under intermittent fluoroscopic guidance, a 22-gauge spinal needle with a Quincke type point (Becton Dickinson and Co, Franklin Lakes, NJ) is advanced into the epidural space via a dorsal, oblique paramedian approach. The puncture site is typically 2 to 4 cm from the midline and 2 to 3 cm caudal to the intended point of entry into the dorsal epidural space (Fig 1). After the injection is complete and the needle is removed, postinjection films are obtained in two projections to document the extent and dispersal pattern of the injectate within the epidural space (Fig 2).

Technique 2: The skin is marked then prepped and draped in a sterile fashion as described above. An 18-gauge venipuncture needle is placed from a puncture site 2 to 3 cm from the midline and without caudal offset over the desired interlaminar gap. An epidural needle with a blunt tip and side hole (Whitacre, Becton Dickinson) is then passed through the introducer needle to the midline dorsal epidural space (Fig 3). After the needle is placed, contrast material is injected for epidurography, followed by therapeutic injection and postinjection filming (Fig 2), as described above for the spinal needle technique.

Transforaminal Epidural Injection.—The patient is placed in a prone position on the fluoroscopy table. The skin is marked with the C-arm oriented posterolaterally approximately 30° to 45° and with craniocaudal angulation to profile the caudal undersurface of the pedicle above the target foramen (Fig 4). For sacral foramen (S1 or S2) injections, a dorsal approach from directly above the appropriate foramen is used, and the same injection technique is employed (Fig 5).

Caudal (Sacral Hiatus) Epidural Injection.—The sacral hiatus is palpated with the patient in the prone position and is visualized fluoroscopically. Before sterile preparation, gauze pads are placed in the cleft between the buttocks to prevent excess Betadine and alcohol from irritating the perineum and the genitals. A fenestrated drape is placed and a 22-gauge 3.5-inch spinal needle is advanced ventrally and rostrally at the midline to the sacral hiatus (Fig 6).

Cervical and Thoracic Epidural Injections.—The patient is placed prone and the skin is marked 1 to 2 cm from the midline, slightly caudal to the interlaminar gap. The C-arm fluoroscopic axis is angled 10° to 15° off midline and caudal for this alignment. After sterile preparation and draping, 1 to 3 mL of 1% to 2% lidocaine is injected subcutaneously for local anesthesia. The skin is then punctured and an epidural needle is advanced to the dorsal midline epidural space (Fig 7). After filming, 2 to 5 mL of steroid is injected. Anesthetic agent is not injected into the cervical epidural space to avoid the risk of respiratory suppression resulting from high cervical anesthesia. We perform virtually all our cervical epidural punctures at the C7 to T1 level. The epidural space above this level is diminutive and associated with higher risk of dural puncture. For lower thoracic injections (T7 to T8 or below), 3 to 5 mL of 1% lidocaine is injected after instillation of the steroid suspension (Fig 8). Postinjection films are then obtained to document dispersal of injectate and to demonstrate possible epidural space abnormalities.

Postinjection Patient Evaluation

After completion of the injection procedure and filming, the patients are monitored for 30 to 45 minutes for safety purposes (all injections) and to assess initial therapeutic response to the injected local anesthetic (lumbar and thoracic injections). The response to injected local anesthetic is rated as R0 (no change), R1 (quantified partial response of 1% to 99%), or R2 (complete relief of the pain symptoms that were present before the injection). The response is documented in the report, as is the indication for the procedure, the injection site, and the volume of injected material. The report also includes interpretation of the radiographic images, with a description of the extent of contrast dispersal before and after the introduction of thera-

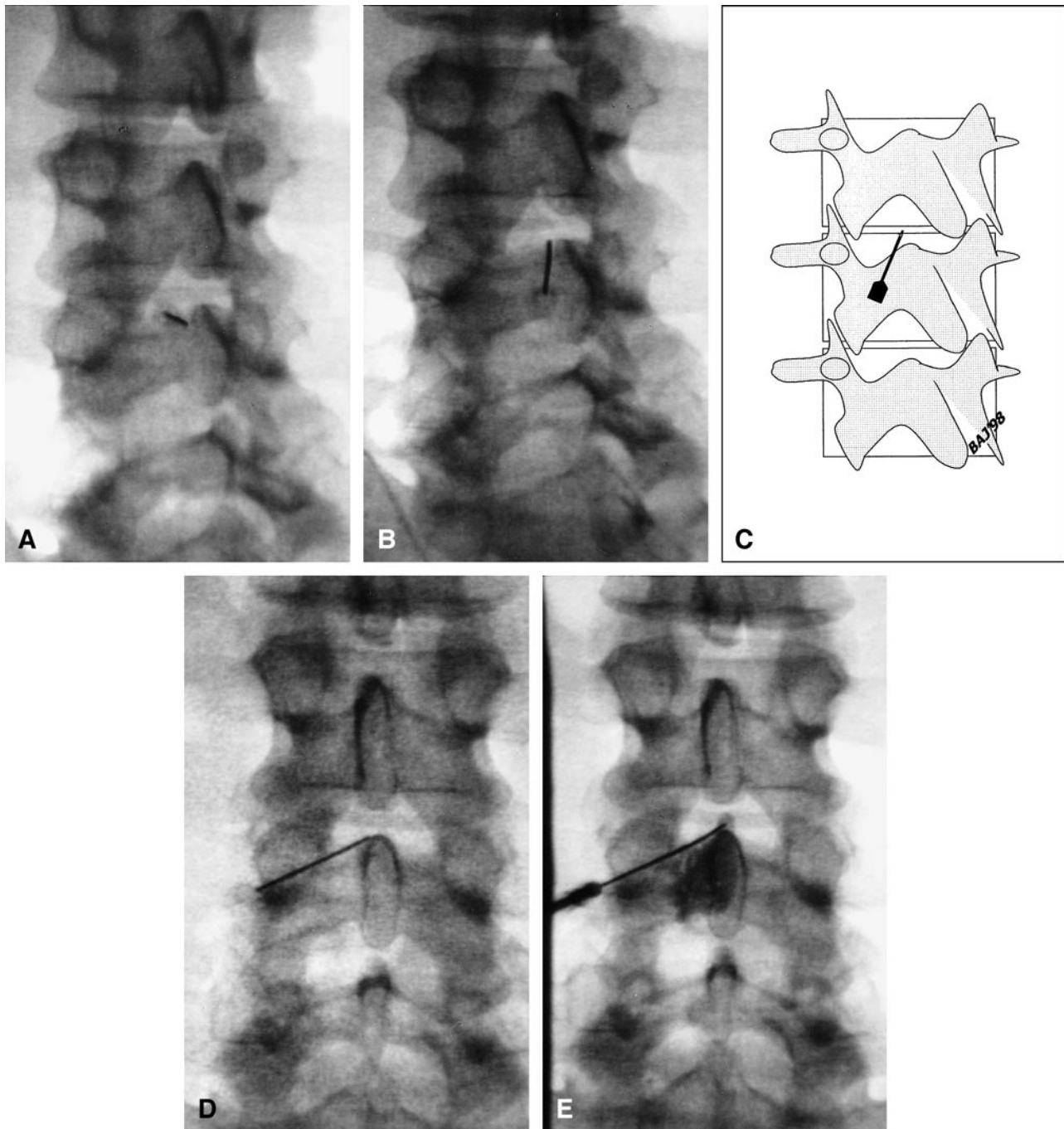


FIG 1. *A*, Fluoroscopic image with approximately 15° left and caudal angulation shows a 3.5-inch spinal needle (5-inch needles are used for obese patients), which is advanced toward the superior aspect of the spinal lamina just below the interlaminar gap. Intermittent fluoroscopic checks of position are used after needle advancement. Allowing the needle to contact the superior aspect of the lamina provides depth control.

B, The needle is then redirected cephalad using bevel rotation and control to guide it over the lamina, passing through the ligamentum flavum and into the posterior epidural space at the midline.

C, Schematic representation of needle orientation relative to the posterior elements after advancing the needle tip over the lamina (oblique view).

D, Anteroposterior fluoroscopic image shows the orientation of the needle as it is advanced over the lamina from a left posterolateral and slightly caudal approach.

E, The needle is then advanced into the epidural space and contrast agent is injected after negative testing for CSF aspiration. On this image, the tip of the needle is seen in the midline and contrast material is beginning to flow into the epidural space. A total of 5 to 6 mL of iohexol, 240 mg/mL, are injected under direct fluoroscopic observation to ensure distribution within the epidural space and exclude opacification of the thecal sac (subarachnoid space), venous structures, or adjacent compartments (subdural/extracranial or paraspinous). After confirmation of epidural space opacification and filming, 2 to 3 mL of betamethasone sodium phosphate/betamethasone acetate suspension followed by 3 to 5 mL of 1% lidocaine or 0.5% miconazole nitrate are injected through the same needle, which has not been moved.

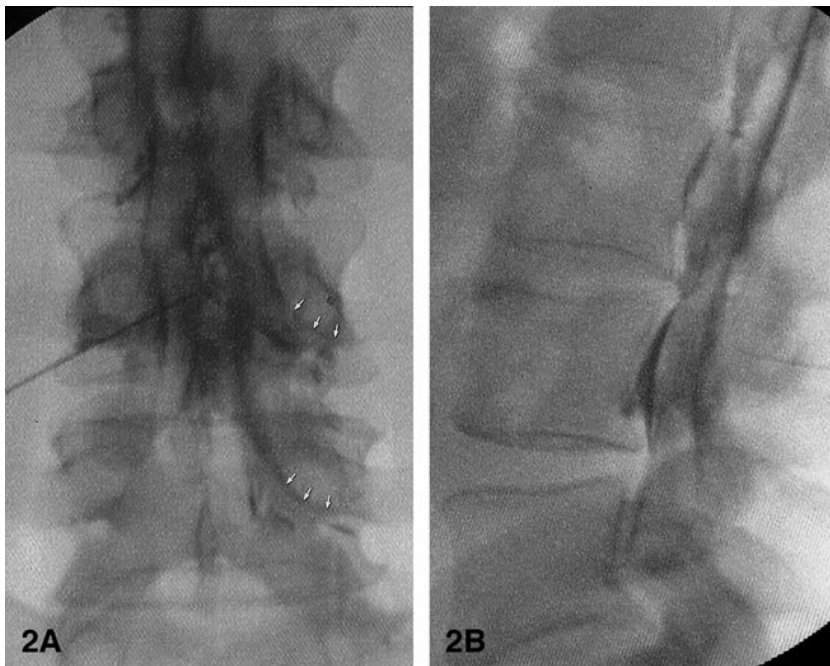


FIG 2. A and B, Anteroposterior (A) and lateral (B) radiographs after contrast injection. The needle is positioned centrally within the dorsal epidural space using technique 1 or 2; the contrast material is seen circumferentially within the epidural space and along the proximal nerve sheaths (arrows).

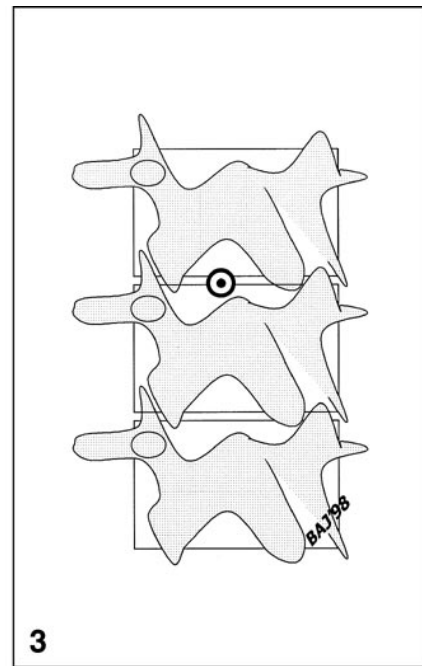


FIG 3. Schematic representation of needle placement and orientation relative to osseous structures. The needle is aligned with the X-ray beam and is seen en face at fluoroscopy 15° to 20° off midline. A 22-gauge epidural needle is passed in a coaxial fashion through the 18-gauge introducer needle and into the dorsal epidural space at the midline. Anteroposterior and lateral fluoroscopy is used to confirm midline needle tip position in the dorsal epidural space.

peutic material. Any epidural defects, evidence of spinal stenosis, or adhesions are documented as well. Patients are instructed to contact the proceduralist or on-call procedural physician in our group in the event of any bothersome side effects or complications during the first 2 weeks after the procedure. They are all given an instruction sheet with potential side effects and symptoms. Referring physicians' offices are also instructed to contact us with regard to any conceivable procedure-related complication(s) they either hear of from the patient or observe on follow-up visits.

Results

Of 5489 consecutive outpatient procedures performed by the three investigators, steroid injection was preceded by epidurography in 5334 cases (155 procedures were performed without contrast material owing to a history of allergy). In two cases, we failed to gain access to the epidural space, and four patients had complications.

Access Failures

In one patient, a complete spinal fusion precluded access to the epidural space. This patient was treated before we were routinely using transforaminal techniques, which most likely would have circumvented this obstacle. In the second failure, the patient had severe scoliosis and osteoporosis. She elected to ter-

minate the procedure when needle redirection was required to access the interlaminar gap.

Complications

The four complications occurred early in our experience. They included a significant hypotensive episode in an 84-year-old patient who was monitored and released without further treatment 2 hours later. In the second complication, which followed one of our early cervical epidural injections, a small dorsal epidural hematoma developed at the injection site and extended upward and downward one segment without any cord or neural compression; symptoms resolved in 18 hours without intervention. The third complication occurred in a 39-year-old man who experienced a severe vasovagal response after injection; he was observed for 3 hours in the emergency department and ultimately discharged without further treatment. The fourth complication was in a 45-year-old mildly hypertensive woman who experienced tachycardia of 130 to 140 and blood pressure of 160 to 180/100 to 110 mg Hg approximately 12 hours after an uneventful lumbar epidural injection. She was observed in the hospital for 3 days. Symptoms were attributed to unusual sensitivity to steroids after consultation

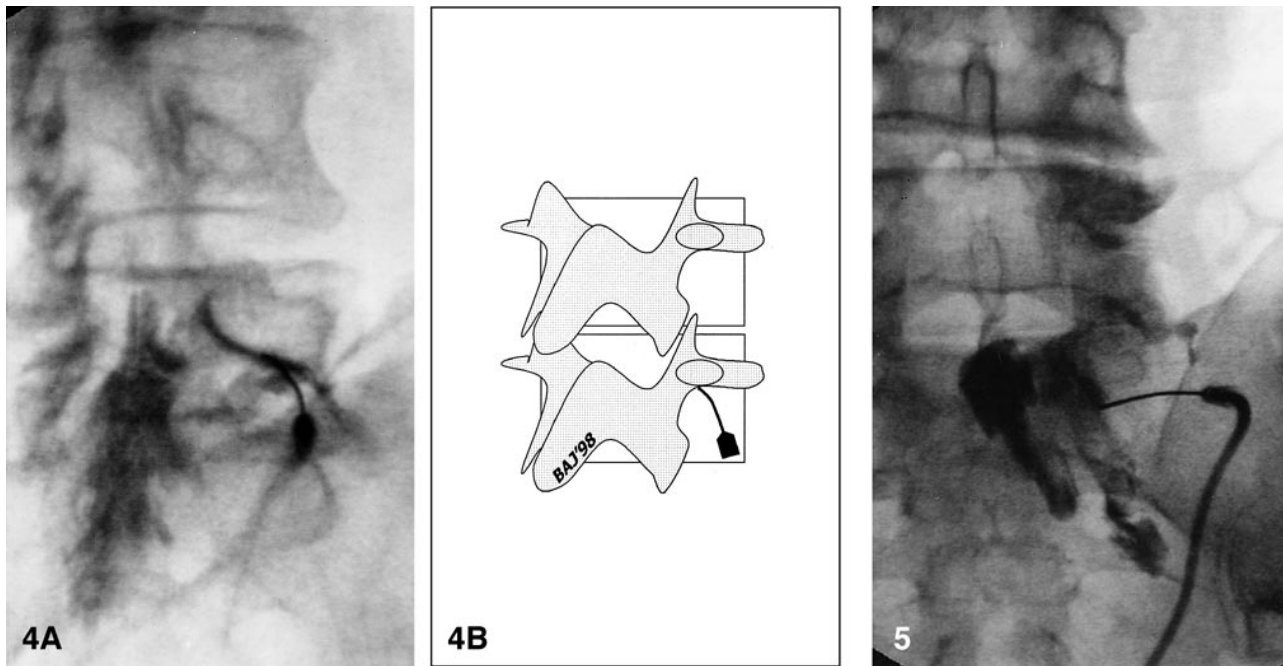


FIG 4. A, After sterile preparation and draping, a 22-gauge spinal needle is carefully advanced into the appropriate neuroforamen immediately adjacent to the vertebral pedicle via a dorsal/lateral approach using intermittent, brief (1–2 second), low-dose fluoroscopic checks. Oblique radiograph after contrast injection shows the needle tip within the right L5–S1 neural foramen. There is opacification of the proximal L5 nerve sheath, with epidural reflux of contrast material, which extends from the L4–L5 level to the S1–S2 level within the epidural space. Ideal needle placement produces opacification of the proximal nerve sheath and adjacent epidural space. After filming (anteroposterior, lateral, and/or oblique images), 2 to 3 mL of water-soluble steroid mixture followed by 3 to 5 mL of local anesthetic are injected through the same needle. Postinjection films are then obtained to document dispersal of the injectate.

B, Schematic representation depicts position of the needle within the foramen using a posterolateral approach. The target for the needle tip in this position is the inferior aspect of the pedicle, which defines the superior margin of the neural foramen. The tip should be at the central (six-o'clock) or slightly medial position for a transforaminal epidural injection. It is positioned slightly lateral to this for a selective nerve root injection.

FIG 5. Anteroposterior radiograph after contrast injection via a right S1 transforaminal epidural approach reveals contrast material extending along the S1 and S2 nerve root sheaths and within the sacral epidural space on the right. The contrast material does not ascend above the L5–S1 level owing to a large herniated nucleus pulposus, which was documented on a CT study.

with an endocrinologist. Her back pain was nonetheless dramatically relieved by the procedure.

There were no local or epidural infections in this series. In order to assess long-term complications, we selected 150 consecutive patients from this subject pool for a 2-year follow-up assessment. None of these patients had infections or other delayed complications.

Discussion

We perform epidurography in conjunction with epidural steroid injections in all patients unless there is either a history or reasonable suspicion of allergy to iodinated contrast agents. These are safe outpatient procedures that can assure correct needle placement as well as demonstrate anatomic rearrangements (14). They require an adequate volume of contrast material to be diagnostically useful; we advocate the use of 5 to 6 mL of contrast material in order to adequately opacify the epidural space and exclude loculations, adhesions, or other barriers to injectate dispersal.

Based on the high rate of erroneous needle placement described in the literature for blinded techniques and the potentially devastating effects of intrathecal steroid injection, we believe it is advisable to perform epidurography before therapeutic injection(s) into the epidural space. Logically, this argument also holds true for the placement of epidural catheters and other devices (13, 15). It is not always possible to confirm needle placement within the epidural compartment on the basis of low resistance with injection. In some patients, the infra-fascial compartment provides little resistance to injection. Although a soft-tissue injection is not harmful, it will likely be of no therapeutic value and will provide a false-negative response to the procedure. Likewise, a venous injection of a low dose of steroid is unlikely to cause significant sequelae, but it is not desirable and it is unlikely to be effective. Negative aspiration for blood is insufficient to exclude intravascular needle placement (3, 7). While CSF will generally return with aspiration after intrathecal needle placement, a needle tip that has punctured the dura and is partially sub-

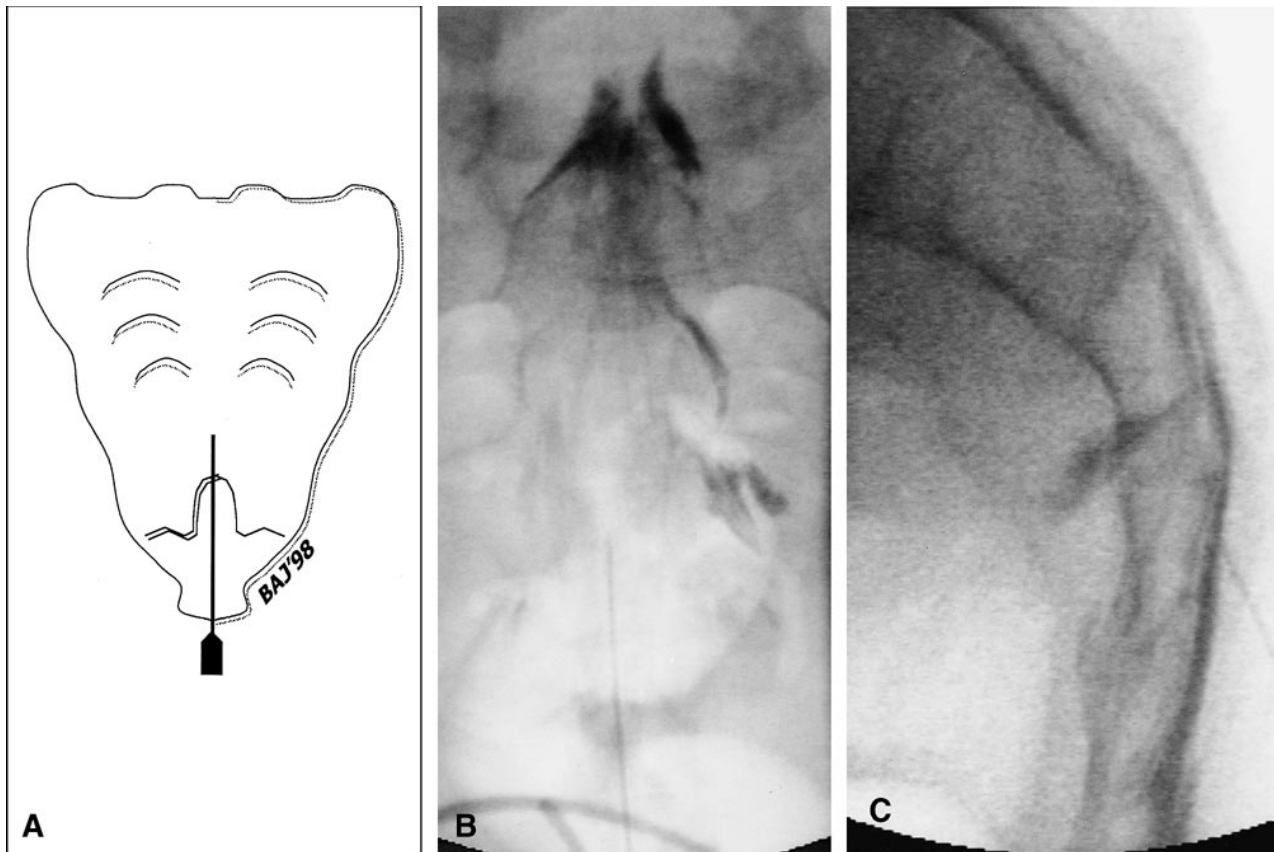


FIG 6. A, Schematic representation of anteroposterior view shows the orientation and position of the needle relative to the sacrum. The needle is passed into the sacral hiatus from below and posteriorly, but is not advanced above the S3 level to avoid inadvertent thecal sac puncture.

B and C, Anteroposterior (B) and lateral (C) radiographs after needle placement in the midline through the sacral hiatus reveal contrast material throughout the sacral epidural space (5 to 6 mL of contrast agent is injected before the radiographs are obtained). After documenting opacification of the caudal epidural space and excluding venous or intrathecal opacification, 2 to 3 mL of steroid mixture followed by 3 to 5 mL of local anesthetic are introduced. Postinjection films are obtained to document dispersal of the injectate. Note that contrast material extends cephalad to the L5-S1 level, but not above this. A significant amount of injectate remains in the caudal sacral canal.

arachnoid may not return CSF upon aspiration. The subsequent injection, however, could result in intrathecal delivery of the steroid agent. Intrathecal delivery of a significant dose of anesthetic may result in profound systemic hypotension, as well as undesired spinal anesthesia. Even more severe complications may result from intrathecal steroid administration: arachnoiditis and adhesions are potential consequences of intrathecal injection of steroid agent, especially with multiple injections (16). This can lead to profound and irreversible clinical sequelae. In skilled hands, our procedure ensures delivery of the therapeutic materials into the epidural space and prevents complications due to intrathecal or intravascular injections.

In addition to enhancing the safety of the procedure, the efficacy of this technique merits discussion. As discussed above, the blind technique does not reliably deliver the injectate into the epidural space. It is therefore a common practice to routinely perform three consecutive epidural injections even if there is no initial response to the first injection. In our practice, if there is no response to

the initial injection (and injectate delivery was shown to be accurate with epidurography), second or third injections are not performed. Since we are certain of injection accuracy, arbitrary follow-up epidural injections become unnecessary for nonresponders. Furthermore, targeting and documenting the distribution of injectate to the epidural space relative to the site of a known disorder on the basis of results of advanced imaging studies and pain diagrams increase the chance of a therapeutic response. Documenting the distribution of injected materials may also explain a patient's response if a unilateral or limited epidural block is encountered (17, 18). On the other hand, if the injectate does not descend below a surgical site because of epidural adhesions, a subsequent injection at a more caudal location may prove effective.

We observed substantially greater delivery (and dispersal) of contrast agent and injected therapeutic substances in the lumbar region after either interlaminar or transforaminal injections at L2 to S1 as compared with caudal or sacral hiatus injections (Figs 4-6). In many caudal epidurograms and ther-

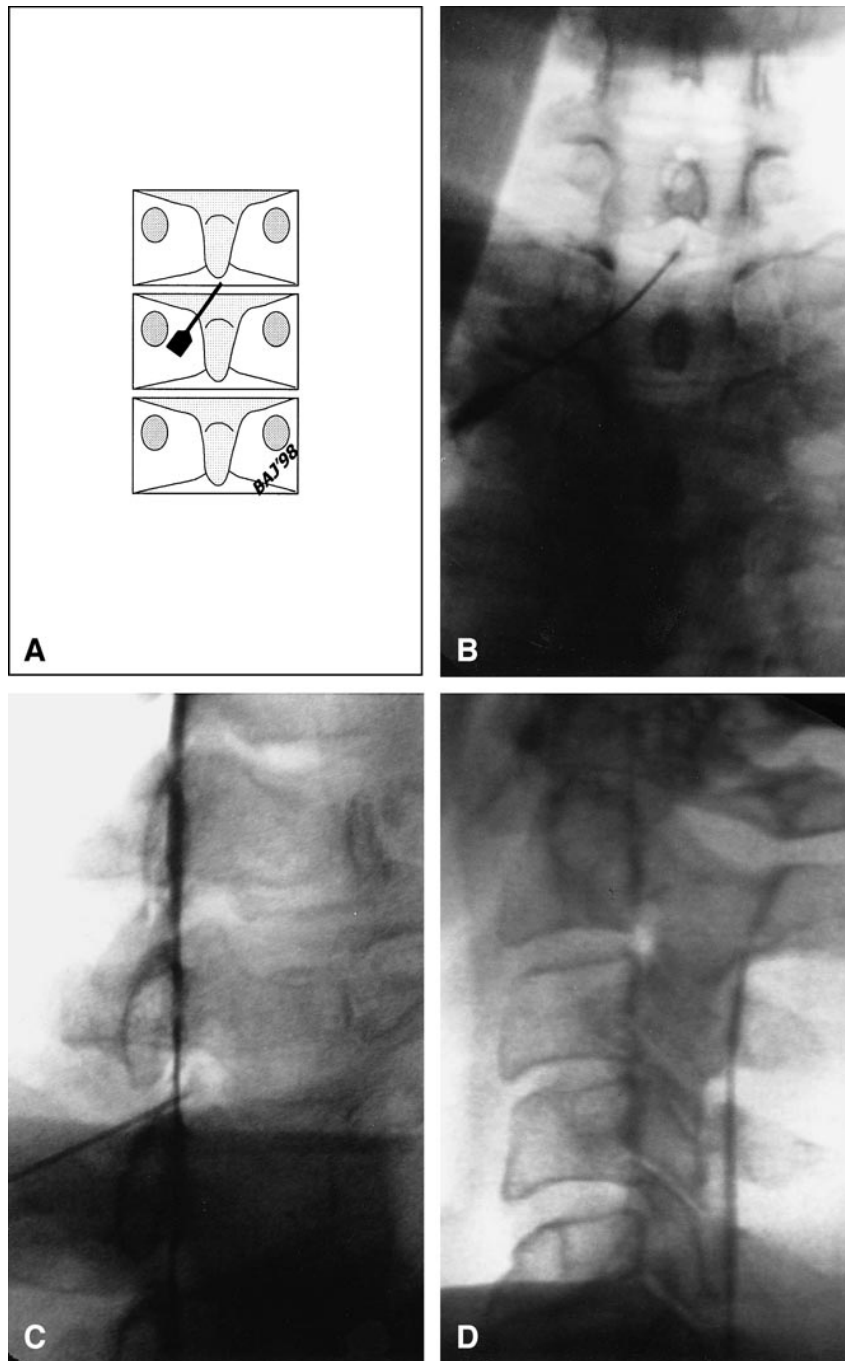


FIG 7. A, Schematic representation of an anteroposterior view shows orientation of the blunt-tipped Whitacre needle relative to the lamina at the C7-T1 level. The needle tip is midline in the dorsal epidural space. An introducer needle is used before placement of the blunt-tipped 22-gauge Whitacre needle. In smaller patients, the introducer needle may be left in place for coaxial insertion of the needle. In larger patients, the 18-gauge needle is removed after skin puncture and before introduction of the Whitacre needle, as the hub of this needle limits the depth of the epidural needle insertion. The needle is advanced rostral and central toward the midline interlaminar gap with the use of intermittent fluoroscopy. Contact with the lamina before entry into the epidural space provides depth control, which is crucial to prevent cord injury.

B, After needle placement, 4 to 5 mL of iohexol, 240 mg/mL, is injected, followed by anteroposterior radiography, which reveals diffuse opacification of the lower cervical and upper thoracic epidural space with extension of contrast material along the proximal nerve sheaths bilaterally.

C, Oblique radiograph shows needle placement over the lamina and into the spinal canal. Contrast agent in the posterior epidural space is profiled in this projection. No venous or thecal sac opacification is exhibited.

D, Lateral radiograph after steroid injection and removal of the needle reveals widespread dispersal of the previously injected contrast agent within the cervical epidural space, outlining the unopacified cervical thecal sac.

apeutic injections, a significant volume remains in the sacral region, often well below the targeted abnormality in the lumbar region. We attempt to perform our injections either directly at or as near as is possible to the segmental disease exhibited on prior imaging studies and as determined by pain diagrams in order to maximize the volume of steroid (and local anesthetic) that reaches the target anatomy (Figs 4 and 5). The posttherapeutic injection epidurogram details the full extent of spread of injected materials. In addition, we select the type of injection technique (interlaminar versus transforaminal) on the basis of both observed structural disease and the patient's pain distribution. For pa-

tients with bilateral pain, we prefer to use an interlaminar technique, if possible, to ensure widespread, bilateral dispersal of the injectate (Fig 2). If pain is unilateral, we typically use a transforaminal technique (if anatomy permits) to maximize delivery of therapeutic substances to the foramen and epidural space nearest the observed target disorder and/or suspected origin of radicular symptoms (Figs 4 and 5).

We advocate that the proceduralist take direct responsibility for follow-up care during the 5 to 7 days after injection. This requires familiarity with the side effects and complications that might develop in relation to steroid treatment. The proce-

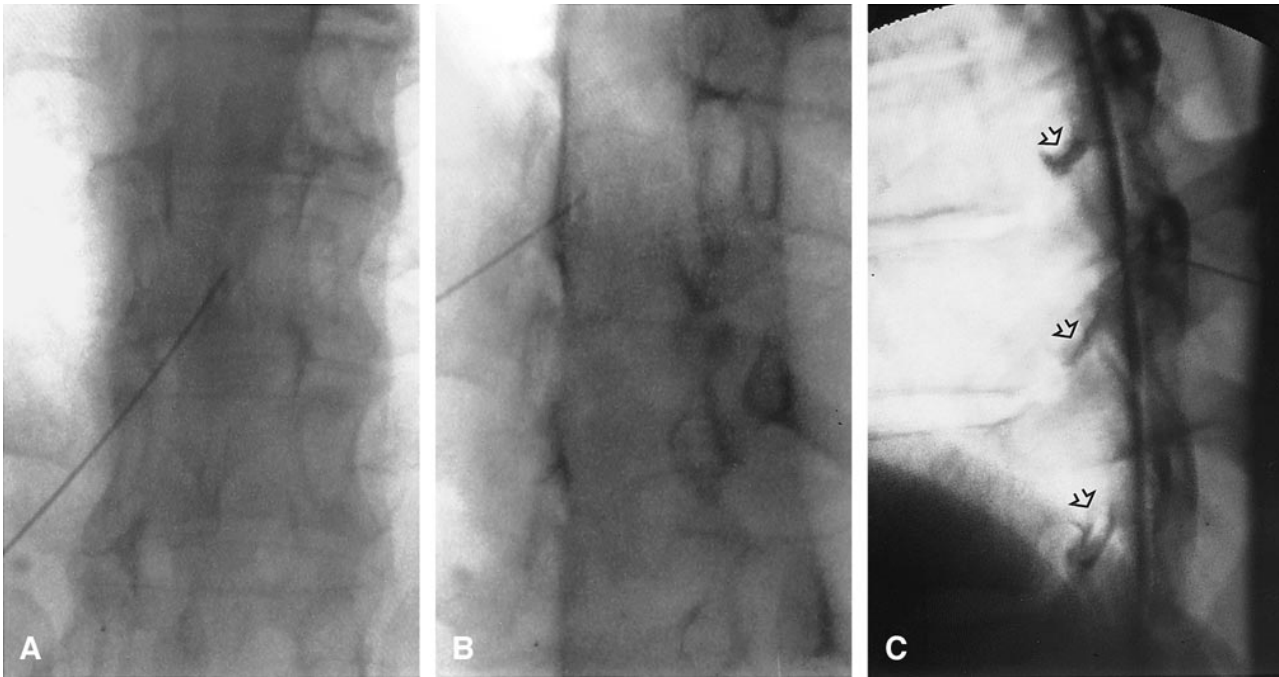


FIG 8. A–C, Anteroposterior (A), oblique (B), and lateral (C) radiographs after thoracic interlaminar epidural injection of contrast material reveal opacification of the lower thoracic epidural space dorsally before injection of steroid and local anesthetic. The Whitacre needle tip is in the midline within the posterior epidural space. Contrast material is seen extending along the proximal thoracic nerve sheaths (arrows).

duralist is in a much more informed position to address procedure-related calls than is the referring clinician or an emergency physician in most circumstances. Maintaining direct responsibility for and communication with patients eliminates unnecessary visits to emergency rooms and helps the proceduralist develop a knowledge of common side effects, complaints, questions, and possible significant complications. We also contact patients between 3 and 7 days after their epidural injection to assess therapeutic response and status with respect to untoward sequelae. If there are any unusual complaints or circumstances, additional follow-up is then provided.

We have reviewed the efficacy of epidural steroid injections in our exclusively referral practice and have confirmed a high rate of success (19). Clinicians who specialize in spinal disorders identify the specific abnormality and indications for epidural steroid injections and refer these patients without economic incentive, thus eliminating the motivation for self-referral (for spine injection procedures).

A final justification for using these techniques is provided by the patients. Hundreds of our patients have commented on the relatively painless nature of the procedure as compared with their prior experience with a blind injection technique. This is an important point with respect to patient sedation and monitoring. We intravenously sedated (conscious sedation with monitoring) only five patients in this series of over 5400 patients, and these were done because of severe anxiety before the procedure.

Every patient who required sedation had previously undergone blind epidural injection(s) elsewhere with a most unfavorable experience. Because fluoroscopically guided epidural injection performed after epidurography is extremely safe and causes minimal patient discomfort, intravenous (IV) sedation and monitoring are only rarely necessary. Because IV sedation is not used, hospitalization and cardiac monitoring are not required for epidural steroid injections when performed under these circumstances, making the procedure ideally suited to outpatient settings. A recent report by Hodges et al (20) further underscores our conviction that IV sedation is not necessary, and in fact may be contraindicated. These authors reported two serious and permanent complications that occurred in sedated patients undergoing cervical epidural steroid injection. Heavily sedated patients are unable to respond with the expected pain and paresthesias due to spinal cord irritation in the event of errant needle placement. Not only were these patients deeply sedated but contrast material was not injected before steroid injection to confirm needle placement within the dorsal epidural space. Performing epidurography in an awake and fully alert patient before steroid injection virtually eliminates the potential for serious complications when done by skilled and experienced proceduralists.

Conclusion

The technique of epidurography followed by therapeutic epidural steroid injection (with or with-

out a local anesthetic) is a safe radiologic procedure that is easily performed by skilled proceduralists on an outpatient basis without intravenous sedation and cardiac monitoring.

Acknowledgment

We thank Becky Borgerson for her assistance in preparing this manuscript.

References

1. Evans W. **Intrasacral epidural injection therapy in the treatment of sciatica.** *Lancet* 1930;2:1225-1229
2. Barry PJ, Hume Kendall P. **Corticosteroid infiltration of the extradural space.** *Ann Phys Med* 1962;6:267-273
3. White AH, Derby R, Wynne G. **Epidural injections for the diagnosis and treatment of low-back pain.** *Spine* 1980;5:67-86
4. White AH. **Injection techniques for the diagnosis and treatment of low back pain.** *Orthop Clin North Am* 1983;14:553-567
5. Abram SE, O'Connor TC. **Complications associated with epidural steroid injections.** *Reg Anesth* 1996;21:149-162
6. Nelson DA. **Intraspinal therapy using methylprednisolone acetate: twenty-three years of clinical controversy.** *Spine* 1993;18:278-286
7. Renfrew DL, Moore TE, Kathol MH, El-Khoury GY, Lemke JH, Walker CW. **Correct placement of epidural steroid injections: fluoroscopic guidance and contrast administration.** *AJNR Am J Neuroradiol* 1991;12:1003-1007
8. El-Khoury GY, Renfrew DL. **Percutaneous procedures for the diagnosis and treatment of lower back pain: diskography, facet-joint injection, and epidural injection.** *AJR Am J Roentgenol* 1991;157:685-691
9. Hatten HP Jr. **Metrizamide lumbar epidurography with Seldinger technique through the sacral notch and selective nerve root injection.** *Neuroradiology* 1980;19:19-25
10. Emery I, Hamilton G. **Epidurography using metrizamide: an out-patient examination.** *Clin Radiol* 1980;31:643-649
11. Hamilton G. **Metrizamide epidurography.** *J R Soc Med* 1983;76:126-130
12. Devulder J, Bogaert L, Castille F, Moerman A, Rolly G. **Relevance of epidurography and epidural adhesiolysis in chronic failed back surgery patients.** *Clin J Pain* 1995;11:147-150
13. Du Pen SL, Williams AR, Feldman RK. **Epidurograms in the management of patients with long-term epidural catheters.** *Reg Anesth* 1996;21:61-67
14. Stewart HD, Quinnell RC, Dann N. **Epidurography in the management of sciatica.** *Br J Rheumatol* 1987;26:424-429
15. Asato F, Goto F. **Radiographic findings of unilateral epidural block.** *Anesth Analg* 1996;83:519-522
16. Sklar EML, Quencer RM, Green BA, Montalvo BM, Donovan Post MJ. **Complications of epidural anesthesia: MR appearance of abnormalities.** *Radiology* 1991;181:549-554
17. Sjogren P, Gefke K, Banning A-M, Parslov M, Overgaard Olsen LB. **Lumbar epidurography and epidural analgesia in cancer patients.** *Pain* 1989;36:305-309
18. Fukushige T, Kano T, Sano T. **Radiographic investigation of unilateral epidural block after single injection.** *Anesthesiology* 1997;87:1574-1575
19. Johnson BA, Schellhas KP, Pollei SR, Kraker D. **Lumbar epidural myelography and steroid injections: correlation of clinical efficacy related to specific pathology and symptoms.** Presented at the annual meeting of the International Spinal Injection Society, Denver, October 1997
20. Hodges SD, Castleberg RL, Miller T, Ward R, Thornburg C. **Cervical epidural steroid injection with intrinsic spinal cord damage.** *Spine* 1998;23:2137-2142