

Case Report

Bitemporal Pseudohemianopia Related to the “Tilted Disk” Syndrome: CT, MR, and Fundoscopic Findings

Luigi Manfrè, Sergio Vero, Cesare Focarelli-Barone, and Roberto Lagalla

Summary: We describe a case of the “tilted-disk” syndrome in a patient with a bitemporal field depression (a pseudohemianopia). CT and MR imaging showed thinning and prolapse of the nasal sectors of the posterior walls of the globes and flattening of the temporal portion of the globes.

A coloboma involving the optic nerve and the eye is an uncommon congenital disorder, which is bilateral in 60% of patients (1), and is at times inhibited as an autosomal dominant defect. Despite several reports of optic and eye colobomas, colobomatous cysts, and morning-glory syndrome (2–5), no MR depiction of tilted-disk (TD) syndrome has been described.

TD syndrome is also described as “situs inversus” of the papilla, congenital optic crescent, nasal fundus ectasia syndrome, or Fuchs’s inferior coloboma. TD syndrome is a rare congenital malformation of the globe, consisting of an oval-shaped papilla, with minor ectasia of the inferonasal area of the posterior wall of the bulb related to scleral thinning (6). The nasal bulge represents sectoral myopia.

We report of a case of TD syndrome in a patient with occult “bitemporal hemianopia” attributable

to a particular malformation of the globe and optic nerve head, and describe the CT, MR, and fundoscopic findings.

Case Report

A 32-year-old woman who complained of severe headaches underwent an ophthalmologic examination. She had an oblique myopic astigmatism, as confirmed by corneal topography, that was corrected with refraction (2.00 = -4.00 ax 25° in right eye, -1.50 = -4.00 ax 5° in left eye), with final visual acuity of 6/10. Fundoscopic evaluation revealed bilateral, small oval-shaped optic disks with distinct temporal disk borders and blurring of nasal borders. Retinal arteries originated from the temporal side of the papilla, curving nasally before arching temporally. Hypopigmentation of nasal chorioretinal layers was also discovered (Fig 1A–B). Bitemporal symmetrical pseudohemianopsia crossing the midline of the visual field was found (Fig 2A–B). Considering the ophthalmologic data, diagnosis of TD syndrome was proposed; however, a radiologic study of the sella and chiasm was considered to exclude a mass involving the chiasm. CT and MR examinations of the brain, the chiasm, and the pituitary gland were normal. Supplementary axial and coronal scans of the orbits showed a symmetrical globe defect, with focal thinning and ectasia of the nasal sectors of the posterior wall of the globe, as well as temporal flattening (Fig 3A–B). The optic nerve size was normal, despite its oblique insertion into the globe. Fundoscopic features, visual-field defects, and the CT and MR findings led to the diagnosis of nasal fundus ectasia with oblique insertion of the optic nerve syndrome.

Discussion

TD syndrome, which is bilateral in 80% of patients, is related to an incomplete closure of the optic fissure, which is located in the inferonasal sector of the globe and optic stalk, with infolding

Received March 23, 1998; accepted after revision April 29, 1999.

From the Departments of Radiology (L.M., S.V.) and Ophthalmology (C.F.-B.), “Pugliese-Ciaccio” Hospital, Catanzaro, and the Institute of Radiology “P. Cignolini” (R.L.), University of Palermo, Palermo.

Address reprint requests to Luigi Manfrè, MD, Department of Radiology, via Duca degli Abruzzi n. 40, 95127, Catania, Italy.

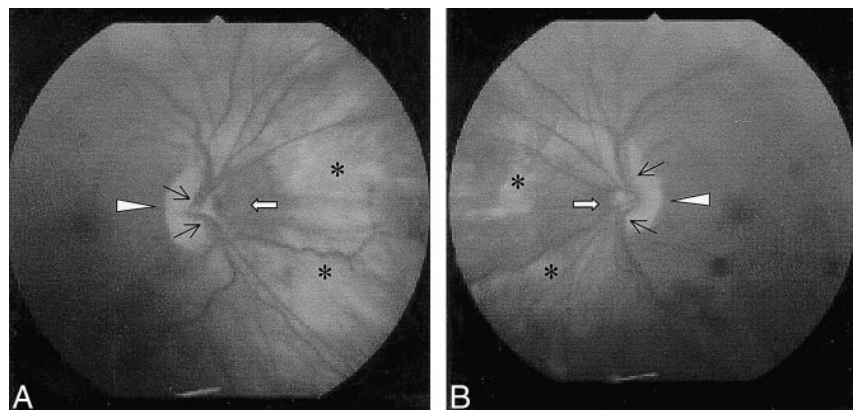


FIG 1. Right (A) and left (B) fundus reveals bilateral, small oval-shaped discs with bulging of temporal disk borders (arrowheads) and blurring of nasal margins (arrows). Retinal arteries originate from temporal side of papilla, and curve nasally before arching temporally (thin black arrows). Note hypopigmentation of nasal chorioretinal layers (asterisks).

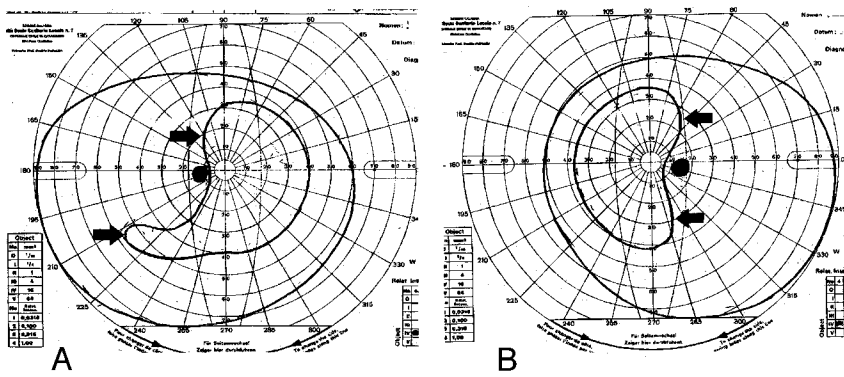


FIG 2. Visual field of right (A) and left (B) eyes. Visual-field defect involving temporal sectors typically crosses midline (arrows).

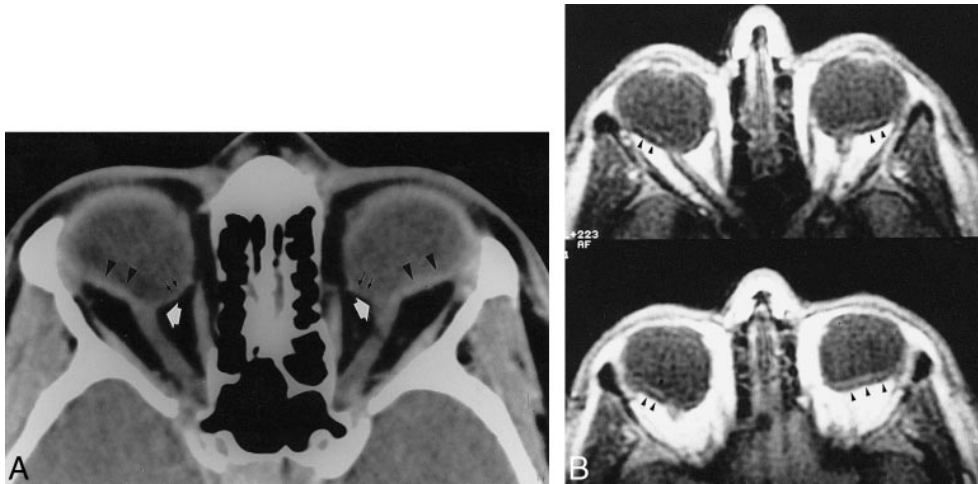


FIG 3. Axial CT (A) and T1-weighted MR (B) scans at level of optic nerve. Oblique insertion of optic nerve head can be appreciated (white arrows). Note ectasia of nasal sector of globes with posterior nasal wall thinning (double arrows) and flattened temporal aspect (arrowheads).

of the primitive hyaloid vascular system. In TD syndrome, moderate-to-severe hypoplasia and thinning of the retinal, choroidal, and scleral layers exist, with focal hypopigmentation and ectasia of the inferonasal posterior wall of the globe, and an oblique insertion of the optic nerve (7) and retinal arteries (8).

Because of focal retinal nasal dysplasia, there are bitemporal hemianopic field defects that mimic TD syndrome, and therefore mimic other more common diseases that cause bitemporal hemianopsia (ie, pituitary adenoma, suprasellar masses). Because of the oblique insertion of the papilla into the globe, the edge of the field defect crosses the midline of the visual field, whereas true chiasmal hemianopsias do not. A careful visual-field test and fundoscopic examination can enable diagnosis of this abnormality. MR or CT studies or both may be performed to rule out a lesion at the chiasmal level (9), because an association between TD syndrome and CNS disease-like tumors such as glioma or craniopharyngioma (10), craniosynostosis (11), and Ehlers-Danlos disease (12) has been described. In addition, in those instances where corneal, lens, or vitreous-body opacities exist, CT or MR studies can depict the imaging features of TD syndrome.

References

1. Pyhtinen J, Lindholm EL. **Imaging in optic nerve coloboma.** *Neuroradiology* 1996;38:171-174
2. Gardner TW, Zaparackas ZG, Naidich TP. **Congenital optic nerve colobomas: CT demonstration.** *J Comput Assist Tomogr* 1984; 8:95-102
3. Mafee MF, Jampol LM, Langer BG, Tso M. **Computed tomography of optic nerve colobomas, morning glory anomaly, and colobomatous cyst.** *Radiol Clin North Am* 1987;25:639-699
4. Hopper KD, Sherman JL, Boal DKB. **Abnormalities of the orbit and contents in children: CT and MR findings.** *AJNR Am J Neuroradiol* 1991;156:1219-1224
5. Bilaniuk LT, Farber M. **Imaging of development anomalies of the eye and the orbit.** *AJNR Am J Neuroradiol* 1992;13:793-803
6. Fuchs E. **Britage zu den angeborenen: anomalien des sehnerven.** *Arch Ophthalmol* 1882;28:139-169
7. Bonamour MG. **A propos des "double papille".** *Bull Soc Ophthalmol Fr* 1964;64:802-805
8. Riise D. **The nasal fundus ectasia.** *Acta Ophthalmologica* (1975); Suppl 126
9. Mimura O, Siraki K, Shimo-oku M. **Fundus controlled perimetry in the tilted disc syndrome.** *Jpn J Ophthalmol* 1980;24:105-111
10. Osher RH, Shatz NJ. **A sinister association of the congenital tilted disc syndrome with chiasmal compression.** In: Smith JL, ed. *Neurophthalmology Focus* New York: Masson;1979;112-123
11. Margolis S, Siegel IM. **The tilted disc syndrome in craniofacial disease.** In: Smith JL, ed. *Neurophthalmology Focus*, New York: Masson;1979;97-116
12. Forman AR. **Situs inversus of the disc in Ehlers-Danlos syndrome type III.** *Ophthalmology* 1979;86:844-846