

Are your **MRI contrast agents** cost-effective?

Learn more about generic **Gadolinium-Based Contrast Agents**.



FRESENIUS  
KABI

caring for life

**AJNR**

**Thermally Induced Transient Trigeminal Sensory Neuropathy: Imaging Findings**

Ling-Ling Chan, Franco DeMonte and Lawrence E Ginsberg

*AJNR Am J Neuroradiol* 2000, 21 (1) 201-202

<http://www.ajnr.org/content/21/1/201>

This information is current as  
of April 18, 2024.

# Thermally Induced Transient Trigeminal Sensory Neuropathy: Imaging Findings

Ling-Ling Chan, Franco DeMonte, and Lawrence E Ginsberg

**Summary:** We report the clinical and imaging features of a patient with transient partial trigeminal sensory neuropathy thought to have been induced by thermal injury to the tongue. Abnormal thickening and enhancement of the mandibular division of the trigeminal nerve was revealed by MR imaging. The diagnostic considerations for mass-like enlargement of the trigeminal nerve should include transient/inflammatory processes, as well as more common and sinister conditions, such as tumor.

Isolated sensory neuropathies of the trigeminal nerve are rare. Clinically, the syndrome consists of isolated numbness in the anatomic distribution of the maxillary and mandibular divisions (1). Imaging is indicated to exclude the commonly associated underlying causes, such as tumor, and to define the extent of disease (2). In the absence of an underlying cause, this condition is termed *idiopathic* and is thought to be viral in origin (1). We present a case of trigeminal sensory neuropathy in which MR imaging revealed transient abnormal enhancement along the proximal course of the mandibular division of the trigeminal nerve. The imaging appearance was similar to that of other disease entities, such as perineural tumor spread and schwannoma. This case is presented to remind radiologists that trigeminal sensory neuropathy, although uncommon, should be considered in a complete differential diagnosis when the appropriate imaging and clinical findings are present.

## Case Report

A 38-year-old man first noticed focal numbness at the tip of the right side of his tongue 2 days after burning his tongue in the same area with hot scalding food. The numbness progressed during the next few days to involve the entire right hemitongue and the right mandibular gingiva and teeth. The patient also experienced a tingling sensation in his right lower lip. This subsequently extended to the chin and entire angle of the jaw. There was no history of cold sores, preceding viral illnesses, or previous head and neck cancer.

Received April 1, 1999; accepted after revision August 5.

From the Departments of Diagnostic Radiology (L.-L.C., L.E.G.), and Neurosurgery (F.D.), The University of Texas M.D. Anderson Cancer Center, Houston, TX.

Address reprint requests to Lawrence E. Ginsberg, MD, Diagnostic Radiology, Box 57, University of Texas M.D. Anderson Cancer Center, 1515 Holcombe Boulevard, Houston, TX 77030.

© American Society of Neuroradiology

A physical examination performed 10 days after the onset of symptoms showed a resolving burn on the right side of the tongue. There were no dental infections, skin vesicles, or cervical lymphadenopathy. Sensory examination revealed blunting of appreciation to pin prick and light touch and impaired temperature discrimination confined to the anatomic distribution of the mandibular nerve. The corneal reflex was intact. There was no facial weakness or weakness of the muscles of mastication.

MR images obtained at the time of the physical examination (Fig 1) showed enlargement and excessive enhancement of the right mandibular nerve in the foramen ovale and upper masticator space, relative to the normal contralateral side. The cavernous sinus, Meckel's cave, and the intracranial space were normal. There was no evidence of a primary malignancy in the head and neck. Initial diagnostic considerations included schwannoma, perineural spread from an occult malignancy, and neuritis.

Shortly after the MR examination, the symptoms began to recede. The right lower facial numbness resolved over 1 week, and the dense sensory loss of the tongue also improved. Because the mandibular nerve enhancement was thought clinically to represent a thermally induced injury rather than a neoplastic process, the patient was managed conservatively. At the 4-month follow-up examination, there was only minimal residual numbness and tingling in the right hemitongue. Repeat MR imaging performed at that time (Fig 2) revealed complete resolution of previous abnormalities, and no new lesion had developed in the interim. The association of imaging abnormality with the clinical symptoms in the same anatomic distribution, and simultaneous resolution of both, strongly suggested the diagnosis of thermally induced transient mandibular nerve neuritis. At the 10-month follow-up examination, the patient remained asymptomatic and the results of further repeat MR imaging were normal.

## Discussion

The differential diagnosis of trigeminal neuropathy is long and incorporates a wide range of conditions, including neoplastic, inflammatory, infectious, toxic, traumatic, iatrogenic (dental), and collagen vascular causes (3). The most worrisome is tumor, either extrinsic or intrinsic to the nerve, including perineural infiltration of head and neck malignancy. Most cases of trigeminal neuropathy have underlying causes (4). Hence, new onset of trigeminal neuropathy, with or without pain, requires a careful clinical and radiologic evaluation to exclude serious underlying disease (2).

The case presented herein represents a transient trigeminal sensory neuropathy of the mandibular division, in which an inciting event, a thermal injury, could be identified. In our search of the literature, we could find no other cases of thermally

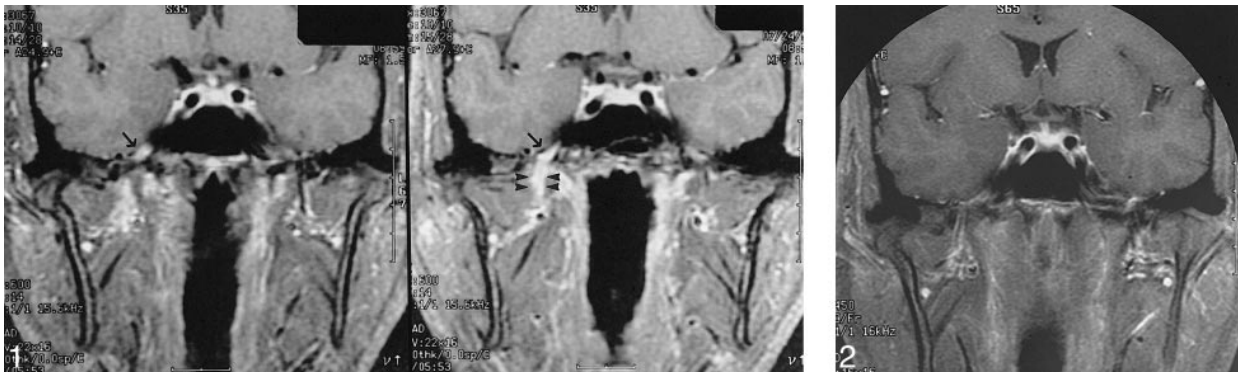


FIG 1. MR images of a 38-year-old man with numbness in the distribution of the mandibular division of the right trigeminal nerve, which occurred after a scalding injury to his tongue. Coronal high-resolution fat-suppressed, contrast-enhanced T1-weighted (600/15/2 [TR/TE/excitations]) MR images, obtained at the time of presentation, show striking enhancement and thickening of the mandibular nerve (V3) at the foramen ovale (arrow) and upper masticator space (arrowheads) on the right.

FIG 2. Follow-up image, obtained 4 months later after the spontaneous and almost total resolution of the patient's symptoms. Coronal fat-suppressed, contrast-enhanced T1-weighted (450/9/2) MR image shows complete resolution of the enhancement.

or traumatically induced trigeminal neuropathy. We did, however, find a well-described, albeit not widely known, entity called *idiopathic trigeminal sensory neuropathy* (1, 5–7). Acute, chronic, and recurrent forms have been reported. The painless and purely sensory form is limited to the mandibular and maxillary divisions, and the patients generally report that they feel as if they just had dental anesthesia with rapid onset. A viral origin is generally postulated for trigeminal sensory neuropathy, and it has been suggested that a diagnosis of idiopathic trigeminal sensory neuropathy be made only if underlying conditions are excluded. Parallels have been made to the transient dysfunction more commonly affecting the sixth and seventh cranial nerves (1). Two cases have been reported in the literature by Rorick et al (6) with MR imaging findings of thickening and excessive enhancement of the trigeminal nerve, albeit in the cisternal segment and gasserian ganglion.

In our case, tumor could not be excluded based on the initial imaging but could be excluded when the lesion resolved without therapy, as revealed by follow-up imaging. The direct temporal relationship of the scalding injury to the sensory neuropathy, combined with the simultaneous resolution of both the imaging findings and symptoms, argued strongly for a direct causal relationship between the two. To our knowledge, thermally induced transient trigeminal sensory neuropathy has not previously been reported in the literature.

There is relatively little literature describing thermal injuries to cranial nerves. We are unaware of any documentation that a distal cranial nerve thermal injury can result in a retrograde inflammation or neuritis. It has been reported that scalding injuries in rat paws result in a marked release of the neuropeptides neurokinin A and Y from peripheral

nerves and that this peptide release may contribute to the edema and inflammation that occurs after burns (8). It is conceivable that this nerve-mediated burn response and the associated inflammation could alter the blood-nerve barrier and result in the abnormal enhancement of the nerve seen on MR images.

We postulate, in this case, that a thermal injury, a burn to the tongue, resulted in an inflammatory reaction of the lingual nerve, which spread in a retrograde manner and resulted in a generalized mandibular nerve sensory neuropathy. We think that the imaging findings were consistent with a transient trigeminal neuropathy/neuritis. When confronted with an enlarged, abnormally enhancing trigeminal nerve, the radiologist should be aware that benign origins, such as transient sensory neuropathies as in the case presented herein, might be the underlying cause.

## References

1. Blau JN, Harris M, Kennett S. **Trigeminal sensory neuropathy.** *N Engl J Med* 1969;281:873–876
2. Hutchins LG, Harnsberger HR, Hardin CW, Dillon WP, Smoker WRK, Osborn AG. **The radiologic assessment of trigeminal neuropathy.** *AJNR Am J Neuroradiol* 1989;10:1031–1038
3. Horowitz SH. **Isolated facial numbness: clinical significance and relation to trigeminal neuropathy.** *Ann Intern Med* 1974; 80:49–53
4. Thrush DC, Small M. **How benign a symptom is facial numbness?** *Lancet* 1970;2:851–853
5. Lecky BRF, Hughes RAC, Murray NMF. **Trigeminal sensory neuropathy: a study of 22 cases.** *Brain* 1987;110:1463–1485
6. Rorick MB, Chandar K, Colombi BJ. **Inflammatory trigeminal sensory neuropathy mimicking trigeminal neurinoma.** *Neurology* 1996;46:1455–1457
7. Peñarocha M, Alfaro A, Bagán JV. **Recurrent idiopathic trigeminal sensory neuropathy.** *Oral Surg Oral Med Oral Pathol* 1993; 75:712–715
8. Lofgren O, Palmer B, Theodorsson E, et al. **Contribution of the sensory and sympathetic nervous system to scalding-induced edema in the rat paw.** *Burns* 1998;24:188–195