

The **next generation** GBCA
from Guerbet is here

Explore new possibilities >

Guerbet | 

© Guerbet 2024 GUOB220151-A

AJNR

Efficacy of Trisacryl Gelatin Microspheres versus Polyvinyl Alcohol Particles in the Preoperative Embolization of Meningiomas

Martin Bendszus, Rüdiger Klein, Ralf Burger, Monika Warmuth-Metz, Erich Hofmann and Laszlo Solymosi

This information is current as
of March 20, 2024.

AJNR Am J Neuroradiol 2000, 21 (2) 255-261
<http://www.ajnr.org/content/21/2/255>

Efficacy of Trisacryl Gelatin Microspheres versus Polyvinyl Alcohol Particles in the Preoperative Embolization of Meningiomas

Martin Bendszus, Rüdiger Klein, Ralf Burger, Monika Warmuth-Metz, Erich Hofmann, and Laszlo Solymosi

BACKGROUND AND PURPOSE: Trisacryl gelatin microspheres are a new, commercially available nonabsorbable embolic agent. The purpose of this study was to evaluate their efficacy in the preoperative embolization of meningiomas as compared with polyvinyl alcohol (PVA) particles of various sizes.

METHODS: In 30 consecutive patients, trisacryl gelatin microspheres (150–300 μm) were used for the preoperative superselective embolization of meningiomas (group 1). Thirty other consecutive patients had embolization with PVA particles of 45 to 150 μm ($n = 15$, group 2) and of 150 to 250 μm ($n = 15$, group 3). Extent of devascularization, intraoperative blood loss, blood transfusion, and hemostasis at the time of surgery were recorded for every patient. The inflammatory reaction, the extent of necrotic areas, and the most distal intravascular location of the embolic agent (arterial, arteriolar, precapillary, capillary) were recorded.

RESULTS: There was no significant difference in the extent of angiographic devascularization among the groups. Intraoperative blood loss differed significantly between groups 1 and 2 and groups 1 and 3, but not between groups 2 and 3. The trisacryl gelatin microspheres were located more distally in tumor vessels than were the PVA particles of either size. The extent of intratumoral necrosis was not significantly different between the two embolic agents. In all groups there was a mild inflammatory tissue reaction in the vicinity of the embolic agent.

CONCLUSION: Trisacryl gelatin microspheres may be effective in the preoperative embolization of meningiomas, producing significantly less blood loss at surgery than seen with PVA particles of either size, possibly because of the significantly more distal vascular penetration of the microspheres.

Preoperative embolization of meningiomas is commonly used to reduce intraoperative blood loss (1–3). To date, many different embolic materials have been used, with PVA particles probably the most common. In one recent study (4), the smaller PVA particles (45–150 μm) were shown to be more effective in reducing intraoperative blood loss than were the larger particles (150–250 μm). Trisacryl gelatin microspheres (Embospheres, Guerbet Biomedical, Louvres, France) are a new, commercially available, hydrophilic, nonabsorbable collagen-coated embolic agent (5). In vivo and in vitro stud-

ies have shown that these particles are precisely calibrated, deformable, and tend not to aggregate (5–7). The purpose of our study was to evaluate the efficacy of trisacryl gelatin microspheres in the preoperative embolization of meningiomas as compared with PVA particles of different sizes.

Methods

Sixty patients (45 women and 15 men; mean age, 58 years; range, 29–76 years) with intracranial meningiomas were included in this study. For every patient, tumor size, histologic subtype, and location were recorded. For a statistical comparison between the groups, tumor location was categorized as superficial (falx, convexity), skull base (frontobasal, sphenoid wing), or posterior fossa. In all patients, a transfemoral approach was used under local anesthesia. After diagnostic angiography, a microcatheter system (FasTracker 10 or 18, Target Therapeutics, Fremont, CA) was placed in the feeding branches of the external carotid artery. None of the patients underwent embolization of branches of the internal carotid artery (ICA).

Prior to injection, the particles were poured into a porcelain cup and mixed with a nonionic contrast medium (Imeron 250, Bracco-Byk Gulden, Konstanz, Germany). Embolization was

Received March 2, 1999; accepted after revision August 24.

From the Departments of Neuroradiology (M.B., M.W.-M., E.H., L.S.), Neuropathology (R.K.), and Neurosurgery (R.B.), University of Würzburg, Germany.

Presented at the annual meeting of the American Society of Neuroradiology, Philadelphia, May 1998.

Address reprint requests to Dr. M. Bendszus, Department of Neuroradiology, University of Würzburg, Josef-Schneider-Str. 11, 97080 Würzburg, Germany.

© American Society of Neuroradiology

TABLE 1: Data for patients treated with trisacryl gelatin microspheres

Case	Age (yr)/Sex	Tumor Site	Meningioma Subtype	ECA/ICA Supply (%)	Extent of Devascularization (%)
1	52/M	Parietal convexity	Microcystic	90/10	Complete
2	73/F	Frontal convexity	Endotheliomatous	100/0	Complete
3	59/F	Frontal convexity	Fibromatous	95/5	Complete
4	59/M	Temporal convexity	Fibromatous	100/0	Complete
5	45/M	Petroclinoidal	Endotheliomatous	50/50	Complete
6	43/F	Sphenoid wing	Endotheliomatous	40/60	Complete
7	44/F	Sphenoid wing	Endotheliomatous	100/0	Complete
8	46/M	Frontal convexity	Clearcell	80/20	Complete
9	71/M	Parietal convexity	Fibromatous	100/0	Complete
10	47/F	Falx	Endotheliomatous	70/30	Complete
11	60/M	Sphenoid wing	Endotheliomatous	20/80	Complete
12	53/F	Temporal convexity	Fibromatous	100/0	Complete
13	68/F	Parietal convexity	Clearcell	100/0	Complete
14	35/M	Falx	Endotheliomatous	100/0	Complete
15	49/M	Parietal convexity	Endotheliomatous	100/0	Complete
16	63/F	Frontobasal	Atypical	90/10	Complete
17	57/F	Frontobasal	Endotheliomatous	50/50	Complete
18	73/M	Frontal convexity	Atypical	70/30	50%
19	63/F	Sphenoid wing	Endotheliomatous	70/30	Complete
20	58/M	Sphenoid wing	Secretory	60/40	80%
21	59/M	Frontal convexity	Transitional	80/20	Complete
22	66/F	Tentorium	Endotheliomatous	70/30	Complete
23	74/F	Tentorium	Transitional	20/80	Complete
24	59/F	Temporal convexity	Transitional	80/20	Complete
25	71/F	Temporal convexity	Microcystic	70/30	Complete
26	51/M	Frontal convexity	Endotheliomatous	40/60	60%
27	46/F	Parietal convexity	Fibromatous	70/30	Complete
28	63/M	Frontal convexity	Transitional	70/30	Complete
29	73/F	Parietal convexity	Transitional	95/5	Complete
30	46/F	Falx	Transitional	80/20	Complete

Note.—ECA/ICA indicates external/internal carotid arteries.

performed by slowly injecting the embolic agent through the microcatheter under fluoroscopic control until the intratumoral perfusion became stagnant. If technically feasible, this was repeated for all tumor-supplying vessels. After embolization, the extent of devascularization was graded as complete (>95%), extensive (>60% to 95%), moderate (30% to 60%), or slight (<30%) by external carotid artery angiography. The grading was done by the neurointerventionalist and by two neuroradiologists blinded to the patient data. Moreover, the extent of ICA and external carotid artery (ECA) blood supply was recorded and, in case of an incomplete ECA embolization, the reasons (eg, vasospasm, dangerous anastomoses) were noted.

In a prospective study, 30 consecutive patients underwent embolization with trisacryl gelatin microspheres of 100 to 300 μm (group 1). Additionally, in 30 consecutive patients, PVA particles (Contour, Target Therapeutics) of 45 to 150 μm ($n = 15$, group 2) and of 150 to 250 μm ($n = 15$, group 3) were used. The median period between embolization and surgery was 6 days in group 1 (range, 1–72 days), 5 days in group 2 (range, 1–19 days), and 7 days in group 3 (range, 2–22 days). At surgery, blood loss (mL) and units of blood transfusion were recorded. Blood loss was measured as the amount of fluid in the reservoir of the sucking device minus the lavage fluid plus the net weight gain of the bloody compresses. Hemostasis was assessed by the neurosurgeon semiquantitatively as dry, moderate, or bloody. For histopathologic examination, specimens were fixed by immersion in 4% buffered formalin. In cases of smaller meningiomas, all tissue available was taken for histopathologic examination; in cases of larger tumors, representative tumor blocks from the center of the tumor, the periphery, and the adjacent dura mater were selected. After fix-

ation, specimens were embedded in paraffin. Sections were prepared for histopathologic examination with hematoxylin-eosin and van Gieson stains.

Blinded to the patient data, we assessed all available archived sections to determine the distribution of the embolic agent and the extent of necrosis. The extent of necrosis was graded according to guidelines established by Ng et al (8) as absent (0), rare and involving less than 0.5 high-power field (HPF) (+), frequent and involving 0.5 to 1.0 HPF (++), and confluent, involving more than 1.0 HPF. Similarly, the most distal intravascular location of the embolic agent was registered in every available section (arterial, arteriolar, precapillary, capillary, or absent). Furthermore, the presence and type of inflammatory tissue reaction were recorded for every section.

Results

Patient data are shown in Tables 1 through 3. There was no significant difference in patients' ages ($P > .5$, Student's t -test), tumor location ($P > .1$, χ^2 test), or ECA/ICA blood supply ($P > .1$, Mann-Whitney test). There was no significant difference between the groups in the extent of preoperative angiographic devascularization ($P > .1$, Mann-Whitney test) (Fig 1). In six patients, the ECA feeders could not be embolized completely owing to technical considerations (vasospasm, dangerous anastomoses, etc; see Tables 1–3). Tumor

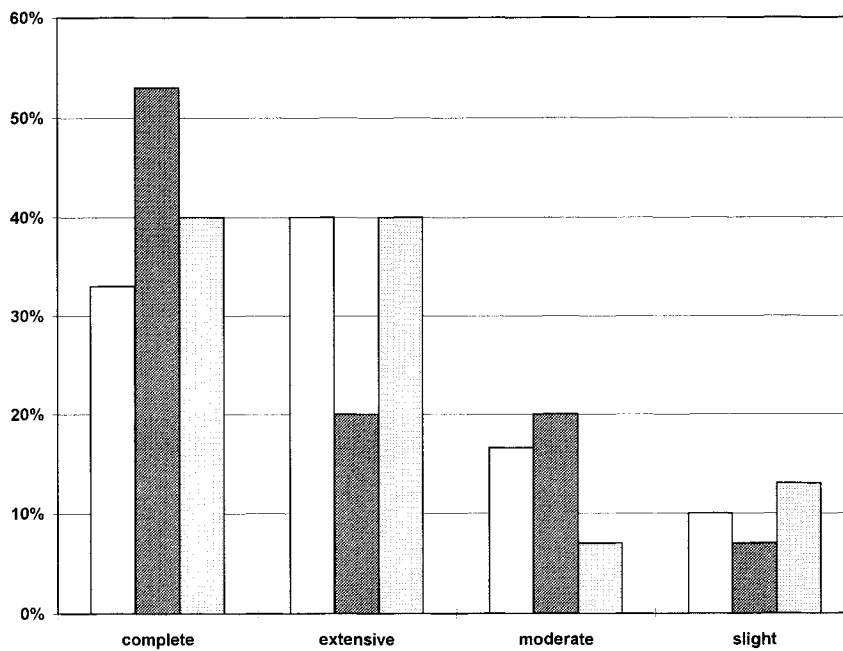


FIG 1. Extent of angiographic preoperative devascularization in groups 1 through 3 (proportional representation for every group). White bars indicate trisacryl gelatin microspheres; dark gray bars, PVA particles 45 to 150 μm ; light gray bars, PVA particles 150 to 250 μm .

size did not differ significantly (23.8 ± 12.2 mL in group 1 versus 25.5 ± 14.1 mL in group 2 versus 26.5 ± 18.5 in group 3; $P > .5$, Mann-Whitney test). The mean intraoperative blood loss was 621 mL in group 1 (range, 160–2050 mL), 886 mL in group 2 (range, 250–1800 mL), and 917 mL in group 3 (range, 250–2550 mL) (Fig 2). It was significantly lower in group 1 than in group 2 ($P < .05$, t -test for independent samples) or group 3 ($P < .05$, t -test for independent samples). Blood loss in groups 2 and 3 did not differ significantly ($P > .1$, t -test for independent samples). The mean number of blood units was lower in group 1 (1.0 U) than in group 2 (1.2 U) or group 3 (1.7 U); however, the difference was insignificant ($P > .1$, χ^2 test). The intraoperative assessment of hemostasis by the neurosurgeon did not show significant differences be-

tween trisacryl gelatin microspheres and PVA particles ($P > .05$, Mann-Whitney test). For every group, a linear regression analysis was performed to investigate the effect of time between embolization and surgery and the extent of blood loss. This analysis showed no significant relationship for any of the groups ($P < .1$).

Histologically, trisacryl gelatin microspheres were located highly significantly more distally in tumor vessels than were PVA particles of 45 to 150 μm ($P < .005$, χ^2 test) or those of 150 to 250 μm ($P < .0001$, χ^2 test, Figs 3–6, 4, 5, 6). Furthermore, PVA particles of 45 to 50 μm showed a more distal location than PVA particles of 150 to 250 μm ($P < .05$, χ^2 test). The extent of intratumoral necrotic areas revealed a tendency toward more extensive necrosis in patients in whom embolization was per-

TABLE 2: Data for patients treated with polyvinyl alcohol particles (45–150 μm)

Case	Age (yr)/Sex	Tumor Site	Meningioma Subtype	ECA/ICA Supply (%)	Extent of Devascularization (%)
1	43/F	Petroclinoidal	Endotheliomatous	70/30	Complete
2	51/M	Parietal convexity	Endotheliomatous	95/5	Complete
3	63/M	Frontal convexity	Endotheliomatous	100/0	Complete
4	75/F	Falx	Fibromatous	100/0	Complete
5	60/F	Frontal convexity	Endotheliomatous	100/0	80%
6	46/M	Frontal convexity	Endotheliomatous	100/0	Complete
7	29/F	Sphenoid wing	Transitional	60/40	Complete
8	76/F	Parietal convexity	Atypical	40/60	Complete
9	71/F	Occipital convexity	Transitional	50/50	Complete
10	48/M	Parietal convexity	Fibromatous	100/0	Complete
11	45/M	Temporal convexity	Endotheliomatous	50/50	Complete
12	48/F	Frontobasal	Endotheliomatous	30/70	80%
13	45/F	Tentorium	Fibromatous	100/0	Complete
14	66/F	Occipital convexity	Endotheliomatous	100/0	Complete
15	55/F	Tentorium	Transitional	100/0	Complete

Note.—ECA/ICA indicates external/internal carotid arteries.

TABLE 3: Data for patients treated with polyvinyl alcohol particles (150–250 μm)

Case	Age (yr)/Sex	Tumor Site	Meningioma Subtype	ECA/ICA Supply (%)	Extent of Devascularization (%)
1	55/M	Parietal convexity	Endotheliomatous	100/0	Complete
2	56/F	Tentorium	Fibromatous	80/20	Complete
3	65/F	Falx	Secretory	20/80	Complete
4	66/F	Petroclinoidal	Endotheliomatous	50/50	50%
5	72/F	Frontotemporal conve	Secretory	100/0	Complete
6	74/M	Occipital convexity	Microcystic	80/20	Complete
7	59/F	Frontal convexity	Microcystic	100/0	Complete
8	72/F	Parietal convexity	Endotheliomatous	90/10	Complete
9	31/F	Frontal convexity	Endotheliomatous	100/0	Complete
10	68/F	Occipital convexity	Transitional	100/0	Complete
11	74/F	Temporal convexity	Fibromatous	80/20	Complete
12	34/F	Sphenoid wing	Transitional	80/20	Complete
13	58/F	Falx	Endotheliomatous	100/0	Complete
14	31/F	Frontotoparietal convex	Endotheliomatous	40/60	Complete
15	41/F	Frontal convexity	Transitional	80/20	Complete

Note.—ECA/ICA indicates external/internal carotid arteries.

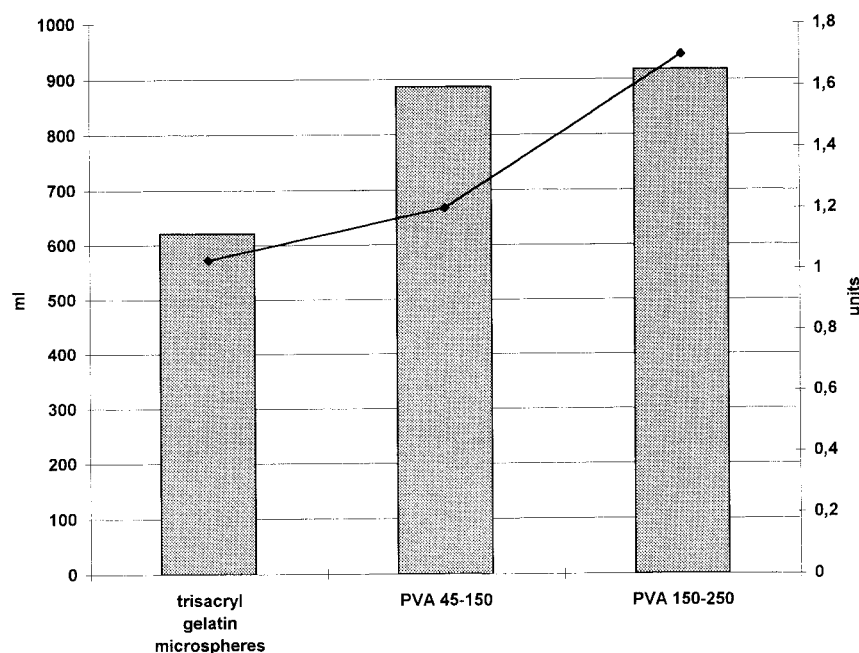


FIG 2. Mean intraoperative blood loss (mL) and mean number of blood units in groups 1 through 3. Shaded bars indicate blood loss; black line, blood units.

formed with trisacryl gelatin microspheres, although this trend was not significant ($P > .05$, Mann-Whitney test).

An inflammatory tissue reaction was observed in 25 patients, without marked differences between the embolic agents (13 patients in group 1, 12 patients in groups 2 and 3). The pattern of inflammatory response consisted of a moderate perivascular lymphocytic reaction, which was observed as early as the first day after embolization (Fig 5B). Moreover, a granulocytic inflammatory reaction was observed in the vicinity of necrotic areas, and there were few foreign-body giant cells close to the embolic material. Neither finding was related to the amount of time elapsed between surgery and embolization or to the kind of embolic agent used.

Discussion

Since the first report by Manelfe et al in 1973 (9), preoperative embolization of meningiomas has been widely performed with a variety of embolic materials, such as Gelfoam (1–3), lyophilized dura (2, 3), *n*-butyl cyanoacrylate (10), ethanol (11), Ethibloc (11), and PVA particles (4), the latter being perhaps the most widely used agent at present. A perfect devascularization would cause a very distal and permanent vessel occlusion in order to achieve tumor necrosis. In cases of proximal vessel occlusion, reperfusion may occur at surgery despite angiographic devascularization (1, 2, 12). To achieve a very distal penetration, an ideal embolic material should be deformable, homogeneous in

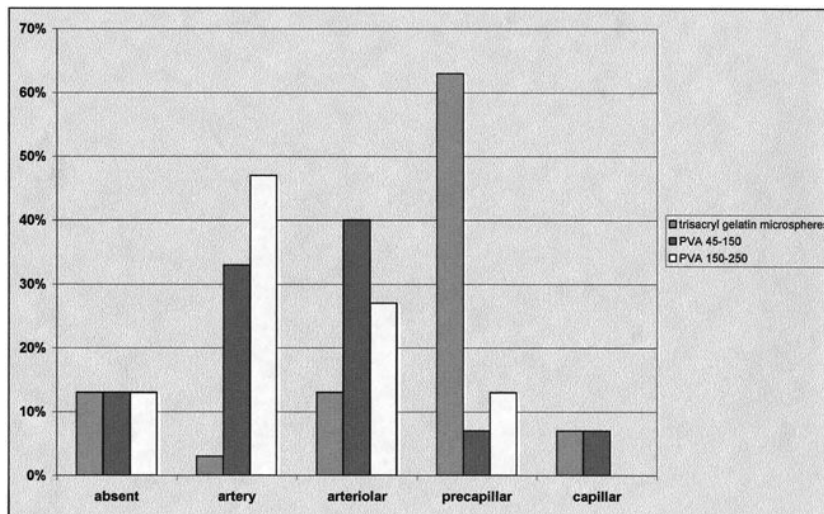


FIG 3. Most distal intravascular location of the embolic agent in groups 1 through 3 (proportional representation for every group). *White bars* indicate trisacryl gelatin microspheres; *light gray bars*, PVA particles, 45 to 150 μm ; *dark gray bars*, PVA particles 150 to 250 μm .

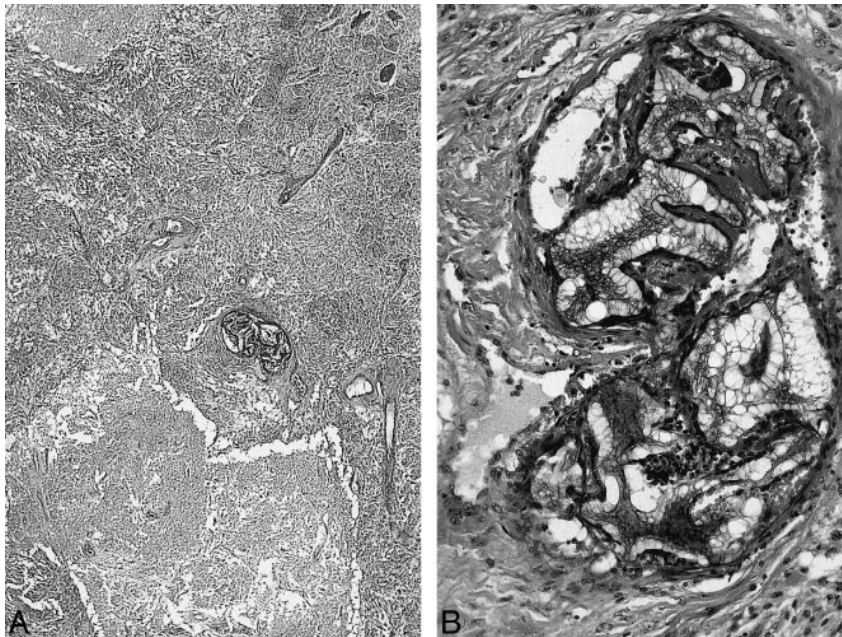


FIG 4. A, Low-power magnification of large PVA particles (150–250 μm) seen in arterial vessels of a meningioma. Note the particles in a small arterial vessel and large extent of necrosis next to the embolized vessel (original magnification $\times 60$).

B, High-power view shows the irregularly shaped large PVA particles that obliterate the lumen and lead to additional thrombosis (original magnification $\times 240$).

size, and regularly shaped. PVA particles vary in size and have an irregular surface (13, 14), which may lead to clumping or aggregation of particles, causing catheter obstruction or large vessel occlusion with recanalization of the capillary bed (14). One recent study (4) found that very small PVA particles (45–150 μm) are more effective in preoperative devascularization than are larger particles (150–250 μm), and these authors suggested that this result was the effect of a more distal penetration of smaller particles. However, others have reported the occurrence of facial nerve palsies after ECA embolization with very small particles that were attributed to the penetration of small particles through ICA/ECA anastomoses (15, 16) or to occlusion of the vasa nervorum of cranial nerves (17). Therefore, some authors generally do not recommend the use of particles smaller than 100 μm (1, 18).

Recently, trisacryl gelatin microspheres have been introduced as nonresorbable and deformable embolic agents with calibrated sizes and uniform shapes (5). In preliminary clinical studies, these particles proved to be effective and safe in the embolization of highly vascularized tumors and vascular malformations (6). In animal studies, it has been shown that for a given vessel and particle size, Embospheres significantly penetrate deeper into the blood vessel system than do PVA particles (7). The purpose of our study was to evaluate the efficacy of Embospheres in the preoperative devascularization of meningiomas as compared with the use of different-sized PVA particles. Perhaps the most important finding was the significantly more distal penetration achieved by Embospheres as compared with PVA particles of either size. PVA particles tended to aggregate and thus occlude larger vessels (Figs 4 and 5), whereas Embospheres never clus-

FIG 5. A, Small PVA particles (45–150 μm) are found in arterial vessel, in which they nearly completely obliterate the lumen, as well as in vessels in which they do not fully obliterate the lumen but lead to intravascular thrombosis (original magnification $\times 60$).

B, High-power view of small PVA particles in a precapillary vessel, with thrombosis surrounding the irregularly shaped PVA particle. A slight lymphocytic inflammatory reaction surrounds the vessel (original magnification $\times 480$).

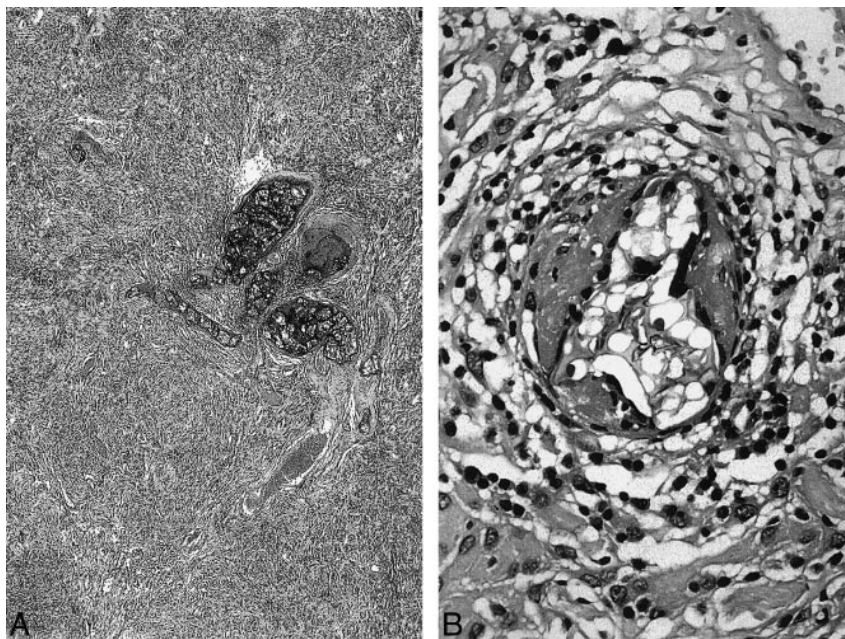
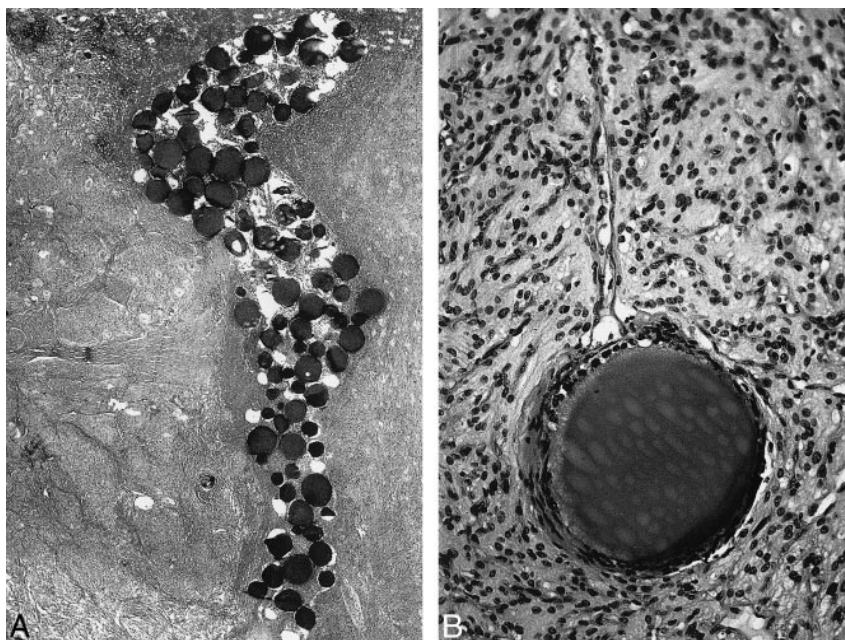


FIG 6. A, Embospheres (100–300 μm) form rolls and aggregations but do not lead to thrombosis in larger vessels (original magnification $\times 60$).

B, High-power view of a single trisacryl gelatin microsphere that completely obliterates a precapillary vessel. A small capillary without blood particles branches from this embolized vessel (original magnification $\times 480$).



tered but rather formed chains in smaller vessels (Fig 6). This difference is probably caused by the different biomechanical properties of the two materials in terms of surface structure, deformability, and regularity of shape. Moreover, we found a significantly lower blood loss at surgery in patients who underwent embolization with Embospheres, even though the angiographic extent of preoperative devascularization was not significantly different between the two groups. Intraoperative blood loss appears to be a more realistic measure of the efficacy of embolization than is the extent of devascularization on the postembolization angiogram (1, 2, 12).

The mean period between embolization and surgery was 5 to 7 days among the groups. To examine whether time affected the degree of devascularization, especially in the PVA group, we performed a regression analysis between time and intraoperative blood loss, which showed no significant relationship. Tumor revascularization may be caused not only by a recanalization of formerly obliterated vessels but also by a rapid opening of intratumoral anastomoses.

The histologic extent of necrosis did not reveal significant differences between the embolic agents, possibly because of intraoperative aspiration of the necrotic areas and thus an incomplete neuropatho-

logic examination. Both trisacryl gelatin microspheres and PVA particles caused a mild inflammatory reaction, similar to that reported in previously published animal studies (7). Even though we have no long-term follow-up data, a more extensive and distal vascular occlusion in patients with meningioma might even lower the recurrence rate owing to necrosis at the site of dural attachment (19). Moreover, in selected patients, a palliative embolization without subsequent surgery has been suggested (4). In these patients in particular, permanent devascularization needs to be achieved in order to obtain tumor necrosis and prevent regrowth.

Conclusion

Trisacryl gelatin microspheres have proved to be safe and effective in the preoperative devascularization of meningiomas. In this first comparative clinical study, trisacryl gelatin microspheres significantly penetrated the intratumoral vascular bed deeper than PVA particles of 45 to 150 μm and those of 150 to 250 μm , thus yielding a significant reduction in intraoperative blood loss relative to PVA particles.

References

- Manelfe C, Lasjaunias P, Ruscalleda J. **Preoperative embolization of intracranial meningiomas.** *AJNR Am J Neuroradiol* 1986;7:963-972
- Teasdale E, Patterson J, McLellan D, McPherson P. **Subselective preoperative embolization for meningiomas: a radiological and pathological assessment.** *J Neurosurg* 1984;60:506-511
- Richter HP, Schachenmayer W. **Preoperative embolization of intracranial meningiomas.** *Neurosurgery* 1983;13:261-268
- Wakhloo AK, Juengling FD, Van velthoven V, Schumacher M, Henning J, Schwechheimer K. **Extended preoperative polyvinyl alcohol microembolization of intracranial meningiomas: assessment of two embolization techniques.** *AJNR Am J Neuroradiol* 1993;14:571-581
- Laurent A, Beaujeux R, Wassef M, Rüfenacht D, Boschetti E, Merland JJ. **Trisacryl gelatin microspheres for therapeutic embolization, I: development and in vitro evaluation.** *AJNR Am J Neuroradiol* 1996;17:533-540
- Beaujeux R, Laurent A, Wassef M, et al. **Trisacryl gelatin microspheres for therapeutic embolization, II: preliminary clinical evaluation in tumors and arteriovenous malformations.** *AJNR Am J Neuroradiol* 1996;17:541-548
- Derdeyn CP, Graves VB, Salamant MS, Rappe A. **Collagen-coated acrylic microspheres for embolotherapy: in vivo and in vitro characteristics.** *AJNR Am J Neuroradiol* 1997;18:647-653
- Ng HK, Poon WS, Goh K, Chan MSY. **Histopathology of post-embolized meningiomas.** *Am J Surg Pathol* 1996;20:1224-1230
- Manelfe C, Guiraud B, David J. **Embolisation par catheterisme des meningiomes intracraniens.** *Rev Neurol Paris* 1973;128:339-351
- Mironov A. **Meningeomembolisation mit flüssigen Embolisanten.** *Rofo Fortschr Geb Rontgenstr Neuen Bildgeb Verfahr* 1990;153:327-334
- Jungreis CA. **Skull-base tumors: ethanol embolization of the cavernous carotid artery.** *Radiology* 1991;181:741-743
- Hieshima GB, Everhart FR, Mehringer CM, et al. **Preoperative embolization of meningiomas.** *Surg Neurol* 1980;14:119-127
- Jack CR, Forbes G, Dewanjee MK, Brown ML, Earnest F. **Polyvinyl alcohol sponge for embolotherapy: particle size and morphology.** *AJNR Am J Neuroradiol* 1985;6:595-597
- Derdeyn CP, Moran CJ, Cross T, Dietrich HH, Dacey RG. **Polyvinyl alcohol particle size and suspension characteristics.** *AJNR Am J Neuroradiol* 1995;16:1335-1443
- Lasjaunias P. **Nasopharyngeal angiofibromas: hazards of embolization.** *Radiology* 1981;136:119-123
- Handa J, Nakasu S, Matsuda I. **Facial nerve palsy following therapeutic embolization.** *Surg Neurol* 1980;14:377-380
- Lasjaunias P. **Craniofacial and Upper Cervical Arteries: Functional, Clinical and Angiographic Aspects.** Baltimore: Williams & Wilkins; 1981
- Halbach VV, Hieshima GB, Higashida RT, David CF. **Endovascular therapy for head and neck tumors.** In: Vinuela F, Halbach VV, Dion JE, eds. *Interventional Neuroradiology: Endovascular Therapy of the Central Nervous System.* New York: Raven; 1992
- Berenstein A, Kricheff II. **Microembolization technique of vascular occlusion: radiologic, pathologic and clinical correlation.** *AJNR Am J Neuroradiol* 1981;2:261-267