

Are your **MRI contrast agents** cost-effective?

Learn more about generic **Gadolinium-Based Contrast Agents**.



**FRESENIUS
KABI**

caring for life

AJNR

CT-revealed Choroidal Effusions as a Sign of Carotid Cavernous Fistula

Seema Kumbhat, Suzanne D. LeBlang and Steven Falcone

AJNR Am J Neuroradiol 2000, 21 (4) 779-780

<http://www.ajnr.org/content/21/4/779>

This information is current as
of April 17, 2024.

CT-revealed Choroidal Effusions as a Sign of Carotid Cavernous Fistula

Seema Kumbhat, Suzanne D. LeBlang, and Steven Falcone

Summary: Choroidal effusions may appear as subtle abnormalities on CT scans. Recognition of choroidal effusions, however, is critical because they may be an early sign of ocular pathologic abnormality. After detection, the various causes of choroidal effusions, such as carotid cavernous fistulas, ocular hypotony, tumors, and inflammatory conditions, should be considered.

In a patient who presented with markedly decreased visual acuity, contrast-enhanced CT revealed a choroidal effusion and a minimally prominent superior ophthalmic vein, leading to the diagnosis of a carotid cavernous fistula. Although other diagnostic techniques, such as ocular sonography, angiography, and MR imaging, can be used in the evaluation of carotid cavernous fistulas, CT is a readily available method of examination that allows for a more rapid evaluation and can reveal associated findings, such as choroidal effusions.

Case Report

An 83-year-old Latino man presented with left eye pain, loss of vision, decreased eye motility, and progressive proptosis. The patient had a history of hypertension and tachyarrhythmias but no history of glaucoma. An ophthalmologic examination revealed decreased vision in the left eye; when using only the left eye, the patient could only count fingers from a distance of 2 feet. Although the patient's right eye vision was better than that of his left eye, right eye evaluation using the standard E chart showed an impaired visual acuity of 20/200. The left eye contained a large amount of fluid in the anterior chamber, with a 4+ chemosis. The patient had documented mild increased intraocular pressures. CT scans (Figs 1A and 1B) showed preseptal soft-tissue swelling, mild prominence of the superior ophthalmic vein, mild proptosis, and choroidal effusions in the left eye. The choroidal effusions appeared as enhancing, elevated choroidal layers along the medial and lateral aspects of the left globe. The cavernous sinuses were normal. Ophthalmologic sonography confirmed the choroidal effusions in the left eye, no orbital mass lesion, and superior orbital vein dilation. An angiogram (Fig 1C) confirmed the presence of a carotid cavernous fistula on the left side, with drainage into both cavernous sinuses. The patient underwent embolization of the carotid cavernous fistula, performed via direct superior ophthalmic vein puncture.

Received June 29, 1999; accepted after revision October 14.

From the Department of Radiology, University of Miami School of Medicine, Miami.

Address reprint requests to Steven Falcone, MD, University of Miami School of Medicine, Department of Diagnostic Radiology, 1115 NW 14th Street, Miami, FL 33136.

© American Society of Neuroradiology

Improved results were obtained at the follow-up ophthalmologic examination, with only 1-2+ chemosis in the left eye, decreased edema, and increased motility.

Discussion

In this patient, contrast-enhanced CT revealed choroidal effusions and a mildly prominent superior ophthalmic vein, suggestive of a carotid cavernous fistula. Choroidal effusions can be associated with carotid cavernous fistulas (1) but are usually seen with other disease processes, including ocular hypotony, tumor, and inflammatory choroidal disorders (2). Only one previous report has described the association of a carotid cavernous fistula with choroidal effusion on contrast-enhanced CT scans and MR images, initially presenting as closed-angle glaucoma (3). Choroidal effusions are an accumulation of fluid in the suprachoroidal space, between the choroid and sclera. They differ from retinal detachments in their clinical presentation and radiologic appearance. On cross-sectional images, choroidal detachments appear as semilunar elevations with the anterior margins at the ciliary bodies and the posterior extensions at the entry points of the vortex veins or posterior ciliary arteries. Retinal detachments appear as V-shaped elevations with the apex at the optic nerve, because the retina is a neural structure continuous with the optic nerve (4). Plain CT scans have revealed choroidal tears, such as effusions, detachments, and hemorrhage (2). Serous choroidal effusions are hypodense with a thick, elevated, choroidal layer. The hypodense effusion is similar in density to the vitreous and can thus be obscured. A hemorrhagic choroidal detachment is easily identified because of the hyperdense characteristics shown on a CT scan (5).

Once choroidal effusions are detected, causes can be narrowed down by careful evaluation of the CT scans. For example, ocular hypotony is the determined cause when there is visualization of a small globe with a characteristic umbrella sign or scleral infolding (2). Tumors can be identified by a focal mass. Inflammatory processes are associated with fat stranding. More characteristically enlarged superior ophthalmic veins and enlarged cavernous sinuses are associated with carotid cavernous fistulas. Because carotid cavernous fistulas result in increased pressure within the orbital veins, causing increased intraocular pressure, the vortex veins feeding the choroid would also become engorged.

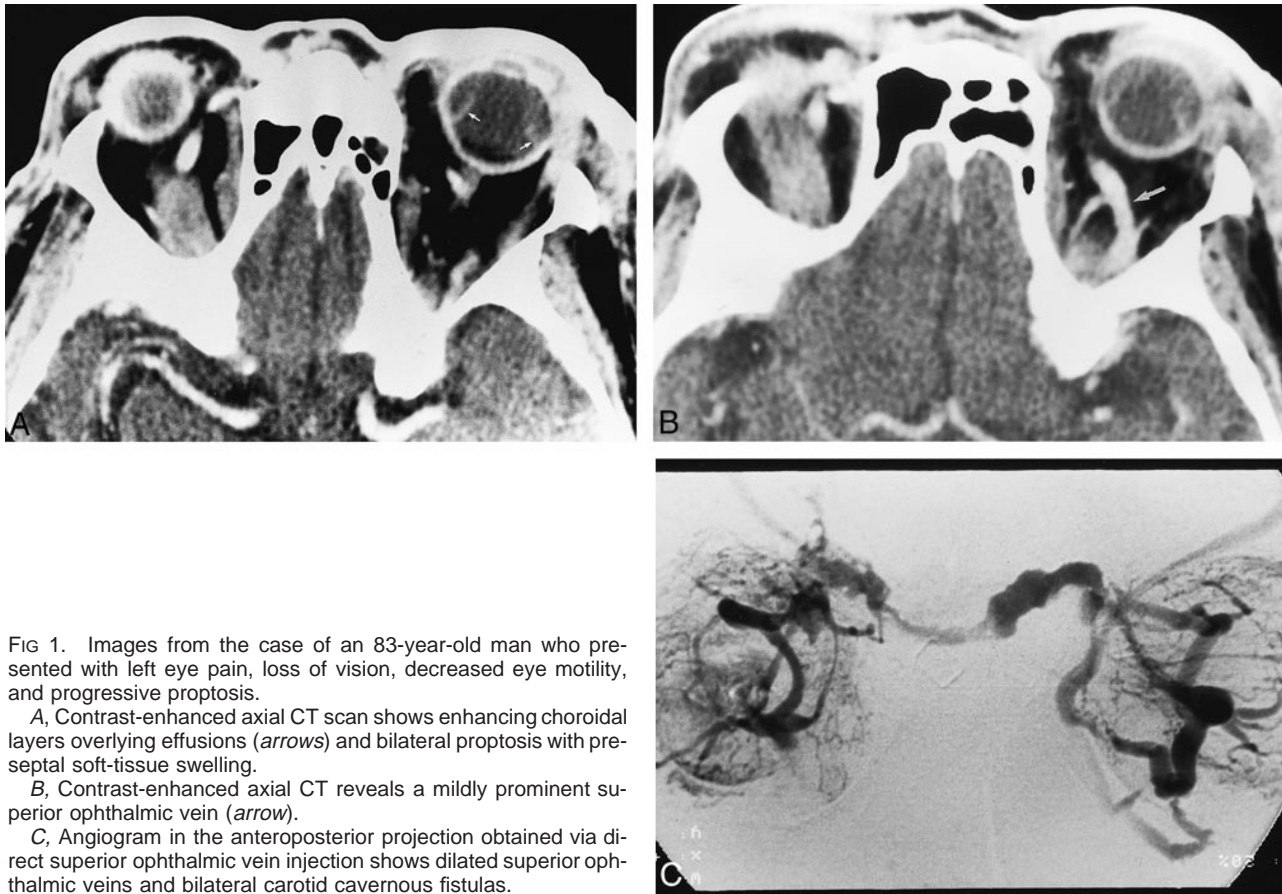


FIG 1. Images from the case of an 83-year-old man who presented with left eye pain, loss of vision, decreased eye motility, and progressive proptosis.

A, Contrast-enhanced axial CT scan shows enhancing choroidal layers overlying effusions (arrows) and bilateral proptosis with preseptal soft-tissue swelling.

B, Contrast-enhanced axial CT reveals a mildly prominent superior ophthalmic vein (arrow).

C, Angiogram in the anteroposterior projection obtained via direct superior ophthalmic vein injection shows dilated superior ophthalmic veins and bilateral carotid cavernous fistulas.

The increased pressure in the choroidal vasculature could lead to increased permeability and leakage of fluid into the suprachoroidal space, creating an effusion (6). Thus, the identification of choroidal effusions on cross-sectional images can be a subtle and useful sign of a carotid cavernous fistula.

References

1. Phelps CD, Thompson HS, Ossining KC. **The diagnosis and prognosis of atypical carotid cavernous fistula (red-eye shunt syndrome).** *Am J Ophthalmol* 1982;92:423-436
2. Peyman GA, Mafee MF, Schulman J. **Computed tomography in choroidal detachment.** *Ophthalmology* 1984;91:156-162
3. Buus DR, Tse DT, Parrish II RK. **Spontaneous carotid cavernous fistula presenting with acute angle closure glaucoma.** *Arch Ophthalmol* 1989;107:596-597
4. Mafee MF. *Ocular Imaging. Videocassette of the American Society of Neuroradiology.* SVT-2.
5. Mafee MF. **Orbital space-occupying lesions: role of computed tomography and magnetic resonance imaging: an analysis of 145 cases.** *Radiol Clin North Am* 1987;25:529-559
6. Tasman W. **Ciliochoroidal effusion.** In: Tasman W, ed. *Duane's Clinical Ophthalmology.* vol 4. Philadelphia: Lippincott Williams & Wilkins; 1998:13-16