

Case Report

Fenestration Surgery for Otosclerosis: CT Findings of an Old Surgical Procedure

Dmitriy Niyazov, Alexandra Borges, Akira Ishiyama, Edward Zaragoza, and Robert Lufkin

Summary: Numerous attempts to deal surgically with otosclerosis were made before the current method of stapedectomy with stapes prosthesis was established. We report a case with unique CT findings of a patient who underwent fenestration surgery for otosclerosis in the early 1940s. Recognition of this old surgical procedure on the imaging scans may avoid misdiagnosis of labyrinthine fistulae or middle and inner ear malformations.

Otosclerosis is an osseous dysplasia of the temporal bone. In the fenestral form, fixation of the stapes occurs when the otosclerotic lesion involves the annular ligament or footplate, thus resulting in conductive hearing loss. Otosclerosis may also involve the cochlea, causing sensorineural hearing loss. Numerous attempts to deal surgically with fenestral otosclerosis were made before the current method of stapedectomy with stapes prosthesis was introduced in 1957. We report the CT findings of a patient who underwent fenestration surgery for otosclerosis in the early 1940s.

Case Report

An 87-year-old woman with a history of fenestration surgery for otosclerosis performed in the early 1940s presented with chronic right-sided ear pain, drainage, and hearing loss. Thin-section (1.0-mm) high-resolution coronal CT scans of the temporal bone revealed bony dehiscence of the right lateral semicircular canal and a linear soft-tissue density closely applied to the membranous portion of the canal (Fig 1A and B). The right mastoidectomy defect and absence of ossicles were also noted. In comparison, the sections through the left temporal bone show a normal bony wall of the labyrinth, with well-aerated and pneumatized mastoid air cells and ossicles present (Fig 1C and D). The CT findings of the right temporal bone are consistent with fenestration surgery with creation of a labyrinthine window in the lateral semicircular canal and placement of the tympanocutaneous flap over the membranous canal to allow for transmission of mechanical vibration.

Received December 13, 1999; accepted after revision March 14, 2000.

From the Departments of Radiological Sciences (D.N., E.Z., R.L.) and Head and Neck Surgery (A.I.), University of California Los Angeles School of Medicine, Los Angeles, CA, and the Department of Radiology (A.B.), Portuguese Institute of Oncology, Porto, Portugal.

Address reprint requests to Dmitriy Niyazov, University of California Los Angeles School of Medicine, Department of Radiological Sciences, Center for the Health Sciences, 10833 Le Conte Avenue, Box 951721, Los Angeles, CA 90095-1721.

© American Society of Neuroradiology

Discussion

Early attempts to correct the conductive hearing loss associated with fenestral otosclerosis date to the late 19th century. The first stapedial operations were performed in 1875 by Kessel (1), who attempted stapedial mobilization. Boucheron (2) reported 60 stapes mobilizations in 1888, and Miot (3) reported 200 such procedures. The first stapedectomies were performed in 1892 by Blake (4), who removed the stapes to improve hearing, and in 1893 by Jack (5), who reported a series of cases of the stapes extraction. Although Miot did not report major labyrinthine complications or death, many patients who underwent stapes mobilization procedure or stapedectomy developed gruesome postoperative complications, including complete deafness, meningitis, and death. Therefore, this early stapes surgery was abandoned.

In 1913, Jenkins (6) first described an innovative type of surgery, which he called *fenestration*. This surgery consisted of the creation of a window in the vestibule or in the lateral semicircular canal, allowing the transmission of sound waves from the middle ear to the perilymph. Sourdille (7), in 1938, described improvements in the procedures for two-stage fenestration of the horizontal semicircular canal. This surgical procedure was further improved by Lempert (8), who, in the same year, described a new technique for fenestration surgery using the endaural approach and a practical one-stage technique, thereby initiating the fenestration era of otosclerosis surgery. To close a defect in the tympanic membrane and decrease the incidence of postoperative otitis media and labyrinthitis, he used a tympanocutaneous flap extending from the temporal bone proximally to the skin of the external auditory canal distally.

Continuous improvements in surgical technique and instrumentation led to the later rehabilitation of stapedial mobilization surgery in 1952 by Rosen (9). In 1957, Shea (10) introduced the stapedial prosthesis, which is now the standard treatment of fenestral otosclerosis (10).

The fenestration operation has been completely replaced by the stapedial prosthesis procedure and is no longer performed. However, patients who underwent fenestration surgery for otosclerosis during the first half of the century may still present for CT evaluation of the temporal bone. We present such a case, in which the condition of a patient with ear

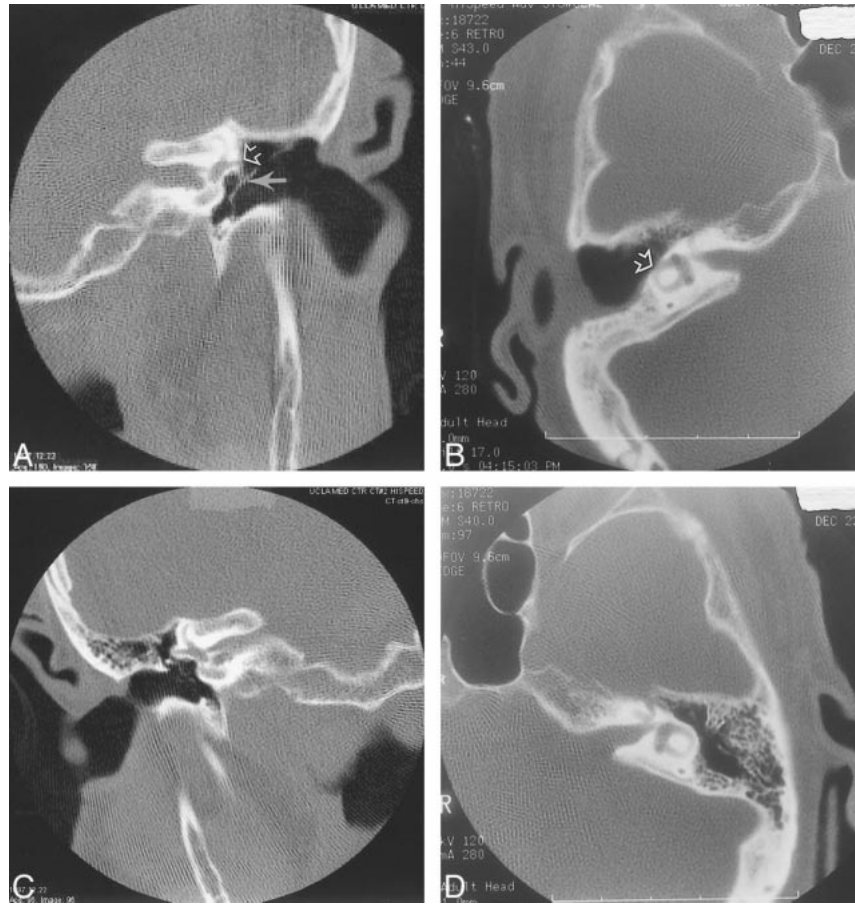
FIG 1. CT scans of the temporal bones in an 87-year-old woman with a history of temporal bone surgery performed in the early 1940s.

A, Coronal-view scan obtained through the vestibule shows bony dehiscence of the lateral semicircular canal (*open arrow*) and a linear soft-tissue density closely applied to this defect. This is because of the fenestration surgery with creation of a labyrinthine window in the lateral semicircular canal and apposition of a tympanocutaneous flap (*closed arrow*).

B, Axial view.

C, Coronal-view scan obtained through the contralateral side shows the normal appearance of the lateral semicircular canals.

D, Axial view.



symptoms and a history of fenestration surgery was examined by CT of the temporal bone.

Cases of imaging findings in patients with previous fenestration surgery for otosclerosis have not been described in the scientific literature. Although numerous authors have described in detail CT findings in cases of otosclerosis (11–18), depicting different types of otosclerosis (11) and surgically altered anatomy and disease of the temporal bone (12), imaging findings showing the postoperative changes and defects of fenestration surgery are not well known.

It is important to be familiar with these findings to avoid misdiagnosis of similar-appearing ear abnormalities, such as perilymphatic fistulae. Such lesions can be seen in association with cholesteatoma and as a postoperative complication for a number of indications, including stapedectomy (19). Other bony abnormalities of the temporal bone, such as congenital and normal anatomic variations including dehiscent jugular fossa and enlarged orifice of the cochlear aqueduct, are less likely to be confused with this entity by the experienced reader (20).

In summary, this case of a patient with a history of fenestration surgery for otosclerosis shows particular CT findings that can be confused with other ear pathologic abnormalities. Recognition of this

condition is important to avoid misdiagnosis of temporal bone abnormalities.

References

1. Kessel J. Ueber das Mobilisieren des Steigbugels durch Ausschneiden des Trommelfelles, Hammers und Ambosses bei Undurchgängigkeit der Tuba. *Arch Ohrenh* 1878;13:69–73
2. Boucheron. La mobilisation de l'étrier et son procédé opératoire. *Union Med* 1888;46:412–416
3. Miot C. Da la mobilisation de l'étrier. *Rev Laryngol* 1890;10:49–52
4. Blake CJ. Middle ear operations. *Tr Am Otol Soc* 1892;5(2):306–312
5. Jack FL. Further observations on removal of the stapes. *Tr Am Otol Soc* 1893;5(3):474–476
6. Jenkins GJ. Otosclerosis: certain clinical features and experimental operative procedures. *Trans 17th Int Congr Med (Lond)* 1913;16:609–611
7. Sourdille M. New technique in the surgical treatment of severe and progressive deafness from otosclerosis. *Bull N Y Acad Med* 1938;13:673–677
8. Lempert J. Improvement of hearing in cases of otosclerosis: a new, one stage surgical technique. *Arch Otolaryngol* 1938;28:42–97
9. Rosen S. Restoration of hearing in otosclerosis by mobilization of the fixed stapedial footplate: an analysis of results. *Laryngoscope* 1955;65:224–269
10. Shea JJ Jr. Fenestration of the oval window. *Ann Otol Rhinol Laryngol* 1958;67:932–951
11. Røvsing H. Otosclerosis: fenestral and cochlear. *Radiol Clin North Am* 1974;12(3):505–515
12. Swartz JD, Goodman RS, Russell KB, Ladenheim SE, Wolfson RJ. High-resolution computed tomography of the middle ear

- and mastoid: part III: surgically altered anatomy and pathology.** *Radiology* 1983;148:461-464
13. Swartz JD, Faerber EN, Wolfson RJ, Marlowe FI. **Fenestral otosclerosis: significance of preoperative CT evaluation.** *Radiology* 1984;151:703-707
 14. Valvassori GE. **Tomographic findings in cochlear otosclerosis.** *Arch Otolaryngol* 1969;89:377-380
 15. Kuznetsov SV. **Effectiveness of computed tomography in the diagnosis of otosclerosis.** *Vestn Rentgenol Radiol* 1993 Jan-Feb; (1):24-27
 16. Swartz JD, Russell KB, Wolfson RJ, Marlowe FI. **High resolution computed tomography in evaluation of the temporal bone.** *Head Neck Surg* 1984;6:921-931
 17. Shchurovskii VV, Rozenfel'd LG. **Effect of surgical therapy of hearing disorders in patients with fenestral and retrofenestral manifestations of otosclerosis.** *Zh Ushn Nos Gorl Bolezn* 1970; 30(4):29-37
 18. Swartz JD, Lansman AK, Berger AS, et al. **Stapes prosthesis: evaluation with CT.** *Radiology* 1986;158:179-182
 19. Meyerhoff WL, Marple BF. **Perilymphatic fistula.** *Otolaryngol Clin North Am* 1994;27(2):411-426
 20. Swartz JD. **High-resolution computed tomography of the middle ear and mastoid: part I: normal radioanatomy including normal variations.** *Radiology* 1983;148:449-454