Are your MRI contrast agents cost-effective?
Learn more about generic Gadolinium-Based Contrast Agents.
FRESENIUS KABI
caring for life

AJNR

MR Imaging in Two Cases of Subacute Denervation Change in the Muscles of Facial Expression

Nancy J. Fischbein, Michael J. Kaplan, Robert K. Jackler and William P. Dillon

This information is current as of April 18, 2024.

AJNR Am J Neuroradiol 2001, 22 (5) 880-884
http://www.ajnr.org/content/22/5/880

AJNR Am J Neuroradiol 22:880–884, May 2001

MR Imaging in Two Cases of Subacute Denervation Change in the Muscles of Facial Expression

Nancy J. Fischbein, Michael J. Kaplan, Robert K. Jackler, and William P. Dillon

Summary: Denervation changes in muscle following damage to cranial and peripheral nerves can be observed on both CT and MR imaging studies. These findings are well described for cranial nerves (CN) V, X, XI, and XII. The CT findings of denervation atrophy due to CN VII dysfunction have been reported. We describe the MR imaging findings in two patients with perineural spread of tumor along CN VII. Both patients showed T2 prolongation and postcontrast enhancement in muscles of facial expression, suggestive of subacute denervation changes.

Damage to a lower motor nerve has profound effects on the muscle(s) it innervates, typically leading to flaccid paresis or paralysis and atrophy. The effects of denervation on muscles can be assessed directly with cross-sectional imaging. CT demonstrates well the changes of motor atrophy, including asymmetrical decrease in affected muscle volume, fatty infiltration of the involved muscle group, and involvement of multiple commonly innervated muscles (1). CT is, however, only sensitive to this end-stage appearance of denervation change. MR imaging has the advantage of providing some earlier insight into the pathophysiological changes that accompany muscle denervation, and also sensitivity to the time course of the process. Denervated muscles undergo a characteristic pattern of changes on MR images as the denervation evolves from an acute phase through a subacute and then chronic phase (2–4). The MR appearance of trigeminal, vagal, spinal accessory, and hypoglossal motor denervation has been well described (2–6). We present two patients with neoplastic invasion of the facial nerve who developed changes on MR consistent with subacute denervation of the muscles of facial expression.

Case Reports

Patient 1

A 67-year-old man was evaluated for neuropathy involving the facial nerve (CN VII) and the third division of the trigeminal nerve (V3). His past history was significant for a renal transplant at the age of 56 years and was he maintained on chronic immunosuppression thereafter. He had a history of multiple prior resections of squamous cell carcinomas of the skin of the arms and legs. In July 1998, he developed a 2.5-cm cystic mass in the right cheek for which he underwent excisional biopsy at an outside facility. The lesion was diagnosed as squamous cell carcinoma, and surgical margins were positive. Postoperatively, the superior branches of the facial nerve were not functioning, affecting his forehead and eye. He then underwent external beam radiation therapy with 6 MeV electrons to a dose of 61.6 Gy from September to November of 1998. Soon thereafter, he was noted to have a complete facial palsy. An MR scan was reported as negative. In March 1999, he developed right facial dysesthesia and severe pain over his lower lip. Repeat MR imaging findings in April were also reported as negative. In May 1999, he developed drooling, and dysfunction of motor V was noted on examination. He was referred to our institution. Clinical examination confirmed a complete right CN VII palsy, as well as dysfunction of V2 and V3. MR imaging demonstrated abnormal enhancement consistent with perineural spread of tumor along right CNs V and VII (Fig 1). In addition, T2 prolongation and postcontrast enhancement were identified in the right-sided muscles of mastication and muscles of facial expression, consistent with denervation change. Retrospective review of prior MR images showed progressive abnormal enhancement along CNs V and VII. In June 1999, the patient underwent palliative gamma knife radiosurgery to Meckel's cave, the cisternal segment of CN V, and the cisternal and intracanalicular segments of CN VII, with considerable improvement in his pain.

Patient 2

An 86-year-old man presented in October 1997 with trigeminal neuralgia involving the third division of the trigeminal nerve. His past medical history was notable only for a prostatectomy in 1989 for prostate cancer. MR imaging was performed and findings were reported to be negative. In February 1998, he underwent a right suboccipital craniectomy and microvascular decompression of the trigeminal root. Intraoperatively, a branch of the superior cerebellar artery was found to be compressing the trigeminal nerve, and this was elevated from the nerve with a Teflon pad. Postoperatively, the patient's symptoms persisted, and in June 1998, he underwent repeat surgery with partial selective sensory trigeminal rhizotomy. He obtained some relief of symptoms and was briefly lost to follow-up. In March 1999, he noted drooling, and a Bell's palsy was diagnosed. Soon thereafter, he developed increasing facial pain, as well as numbness in the distribution of V2 and V3 on the right. He also began stumbling, and when he presented for neurologic evaluation, he was found to be ataxic. A repeat MR scan was obtained (Fig 2A–C), which demonstrated a large right cerebellopontine angle mass, as well as abnormal enlargement and/or enhancement of V2, V3, the vidian nerve, the greater superficial petrosal nerve, and the facial nerve. In addition, enhancement consistent with denervation changes in the

Received August 15, 2000; accepted October 6 2000.

From the Departments of Radiology (N.F., W.D.) and Otolaryngology-Head and Neck Surgery (M.K., R.J.) University of California, San Francisco, San Francisco, CA.

Address reprint requests to Nancy J. Fischbein, MD, Department of Radiology, Room L-358, Box 0628, University of California, San Francisco, 505 Parnassus Avenue, San Francisco, CA 94143-0628.

© American Society of Neuroradiology

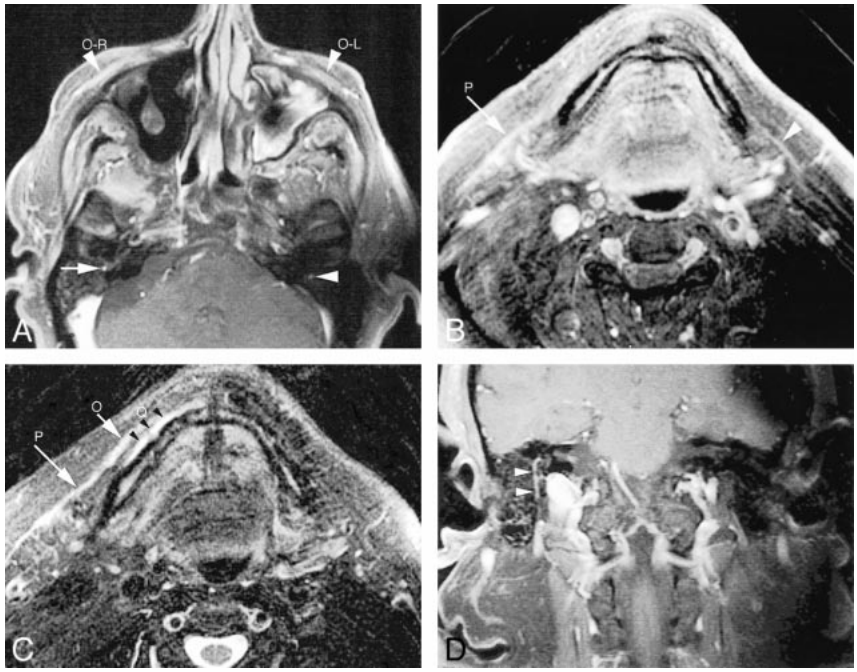

FIG 1. Patient 1.

A, An axial T1-weighted postcontrast image with fat saturation (600/13/2 [TR/TE/excitations]) demonstrates asymmetrical enhancement in the right orbicularis oculi muscle (O-R, *arrowhead*) as compared with the contralateral side (O-L). In addition, asymmetrical, abnormally intense enhancement along the descending mastoid segment of the right facial nerve (*white arrow*) as compared with the left (white arrowhead) is noted, consistent with perineural spread of neoplasm. Mildly asymmetrical enhancement of right-sided muscles of mastication is related to perineural spread of tumor along V3 (not shown).

B, A more inferior motion-degraded axial T1-weighted postcontrast image with fat saturation demonstrates intense enhancement in the right platysma (P, *arrow*) as compared with the left (*arrowhead*).

C, An axial fast spin-echo T2-weighted image with fat saturation (4000/102/1) slightly superior to the level shown in (*B*) demonstrates markedly increased signal intensity in the right platysma (P, *long stemmed arrow*), orbicularis oris (O, *short stemmed arrow*), and quadratus labii inferioris (Q, *small black arrowheads*). The contralateral muscles are poorly seen on this fat-saturated image, but clearly are not bright.

D, A coronal T1-weighted postcontrast image with fat saturation (650/13/2) demonstrates abnormally intense, continuous enhancement along the descending mastoid segment of the right facial nerve (*arrowhead*). The contralateral descending mastoid segment of the facial nerve is slightly posterior to this imaging plane and is not seen here.

muscles of facial expression was present. T2 prolongation in the muscles could not be assessed well owing to motion artifact on the T2-weighted images. No history of head and neck cancer or skin cancer could be obtained from the patient. On retrospective review, the prior MR of October 1997 demonstrated abnormal enlargement of V3 (Fig 2D). As there was no history of any local primary tumor, a CT-guided biopsy of foramen ovale was performed. This yielded a diagnosis of poorly differentiated carcinoma, with metastatic prostatic cancer favored, and the patient was treated with palliative external beam radiation therapy.

Discussion

The MR changes that accompany cranial and peripheral motor denervation are well described and include asymmetrical decrease in affected muscle volume, fatty infiltration of the involved muscle group, and variable signal intensity changes, including both T2 prolongation and postcontrast enhancement (2, 3, 5, 7–9). While CT is able to demonstrate only the chronic changes of atrophy and fatty replacement (1), the superior soft tissue contrast of MR facilitates the depiction of the progressive evolution from an acute phase to a subacute and then to a chronic phase that denervated muscle may undergo. In some patients with peripheral neuropathy and either spontaneous resolution of paralysis or surgical nerve grafting, acute or subacute changes have been shown to be reversible on MR imaging, corroborating clinical evidence of reinnervation (7, 9). To our knowledge, this reversibility has not been demonstrated in the setting of cranial neuropathy, presumably because the processes that lead to MR evaluation of denervation changes are generally not reversible, or because imaging is not indicated for the patient's condition. Patients with reversible cranial nerve dysfunction in the setting of Bell's palsy, for example, would generally not come to MR imaging. Even if these patients are imaged, the examination is generally targeted to the course of the facial nerve from the brain stem to the parotid, and the muscles of facial expression are not typically included in the imaging field of view, particularly if surface coils are used. Furthermore, the changes associated with denervation may be difficult to detect if particular MR imaging sequences are not acquired. Volume loss is best appreciated on relatively thin (3–4 mm) precontrast T1-weighted images, whereas signal change in the

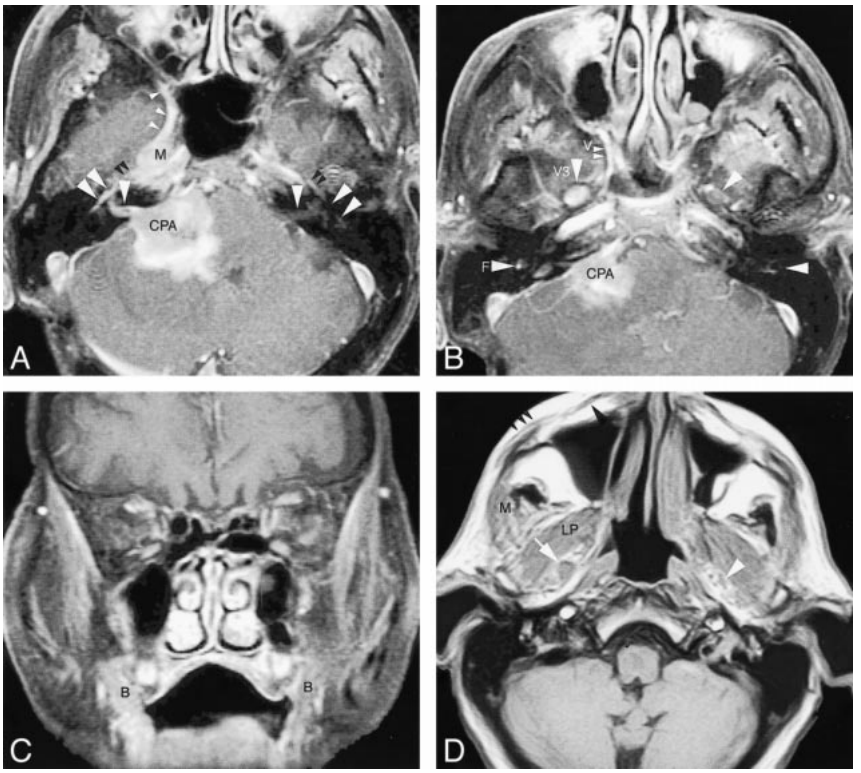

FIG 2. Patient 2.

A, An axial T1-weighted postcontrast image with fat saturation (600/13/2) demonstrates an irregular mass centered at the right cerebellopontine angle (CPA). Enhancement extends into the right internal auditory canal (*vertical white arrowhead*) and along the tympanic segment of the right facial nerve (*oblique white arrowheads*). Contralateral IAC and tympanic segment are shown for comparison (*vertical* and *oblique left-sided white arrowheads*). A mass is also seen in Meckel's cave on the right (M), with abnormal enhancement extending anteriorly along foramen rotundum (*small white arrowheads*) and posterolaterally along the greater superficial petrosal nerve (*small black arrowheads*). The contralateral greater superficial petrosal nerve is demonstrated to show some mild normal enhancement (*small black arrowheads* on patient's left side).

B, A more inferior axial T1-weighted image postcontrast with fat saturation again demonstrates the right CPA mass. There is abnormal enlargement and enhancement of right V3 (*vertical white arrowhead*) compared with the normal left side (*oblique white arrowhead*), as well as abnormal asymmetrical enhancement along the descending mastoid segment of CN VII (F, *horizontal arrowhead*) compared with the left side (*horizontal arrowhead*). There is also marked enhancement of the right vidian nerve (*double small arrowheads,* V). The abnormal and asymmetrical enhancement and enlargement of V2 and V3, the facial nerve, the vidian nerve, and the greater superficial petrosal nerve are due to perineural extension of neoplasm.

C, A coronal T1-weighted image postcontrast with fat saturation (650/13/2) demonstrates marked asymmetrical enhancement of the right buccinator muscle (*B*) as compared with the left buccinator muscle (*B*).

D, An axial T1-weighted image (600/15/2) obtained 2 years earlier demonstrates marked enlargement of the third division of the trigeminal nerve on the right (*white arrow*) as compared with the left (*white arrowhead*). In addition, there is already subtle volume loss in the right muscles of mastication (M masseter, LP lateral pterygoid). The orbicularis oculi (*small black arrowheads*) and quadratus labii superioris (*black arrowhead*) appear symmetrical at this time.

muscles is best appreciated on fast spin-echo T2-weighted images with fat saturation and postcontrast T1-weighted images with fat saturation. Lack of fat saturation can make these changes difficult or even impossible to assess in small muscles such as the muscles of facial expression.

The time course of denervation changes is somewhat arbitrarily defined. To most authors, acute changes are those that occur within a month following denervation, subacute changes are those that follow up to 12 to 20 months, and chronic changes occur after 12 to 20 months (2, 9). On clinical imaging studies of patients with V3 denervation (2), MR images were categorized into four patterns that correlated with the duration of neuropathy. Acute denervation was characterized by abnormal muscle enhancement, T2 prolongation, an increase in muscle volume, and no fatty infiltration. Acute changes usually do not become visible on MR images until after two weeks of symptoms (2, 9, 10), though ex vivo MR spectroscopy has demonstrated metabolic changes in denervated muscles as early as 1 week after denervation (11). Subacute denervation was characterized by continued abnormal enhancement and T2 prolongation, and an increase in signal on T1-weighted images, consistent with variable fatty replacement of the denervated muscles without increase in muscle volume. Early or mild chronic denervation was characterized by mild fatty change of the affected musculature without evidence of appreciable volume loss, T2 prolongation, or abnormal enhancement. Long-standing chronic denervation was characterized by extensive fatty infiltration and volume loss

of denervated musculature, without evidence of abnormal muscle enhancement or T2 prolongation. Findings were similar in hypoglossal denervation, though no distinct early/mild chronic hypoglossal denervation pattern was identified, and acute and subacute hypoglossal denervation exhibited the same imaging pattern (2). Other changes that have been observed in the context of denervation include paradoxical muscle enlargement due either to pseudohypertrophy or true hypertrophy (12). Pathophysiological explanations of MR signal changes following denervation have been discussed extensively in the literature (2, 3, 9, 13). Biopsy of denervated human facial muscles typically shows atrophic myofibers with loss of fiber typability, no correlation between the degree of muscle fiber atrophy and the duration of the paralysis, and variable degrees of fibrosis corresponding to the length of denervation (14).

The facial nerve carries both motor and sensory functions (15). Depending at what level the nerve is damaged, a characteristic pattern of end-organ dysfunction will emerge. The facial nerve traverses the temporal bone and enters the posteromedial surface of the parotid gland within 1 to 2 cm of the stylomastoid foramen. The nerve then divides into temporofacial and cervicofacial divisions. The former subdivides into temporal and zygomatic branches, and the latter into buccal, marginal mandibular, and cervical branches, but anatomy is variable among patients and there are numerous interconnections between divisions and branches in the periphery (15). These branches innervate the numerous muscles of facial expression. A lower motor neuron facial palsy can result from a variety of processes, most commonly Bell's palsy, herpetic neuritis, trauma (typically related to temporal bone fracture or parotid surgery), parotid malignancy, and perineural spread of tumor. Unless nerve involvement is very peripheral (ie, very distal fascicles affected without involvement of the more proximal nerve), because of the multiply interconnecting anatomy, we would not expect to be able to appreciate selective muscular denervation resulting from selective branch involvement.

In the cases presented, the patients had been symptomatic for approximately 6 to 8 months prior to imaging at our institution. In addition to abnormal enhancement along cranial nerves and denervation changes in the muscles of mastication due to V3 disease, MR imaging demonstrated T2 prolongation and enhancement of certain muscles of facial expression (buccinator, quadratus labii inferioris, orbicularis oculi). There was also possible volume loss in some of these muscles (not shown), but given the small size of these muscles, our ability to reliably discern fatty infiltration is somewhat questionable. These clinical and imaging findings are most consistent with subacute denervation changes. Perineural spread of cutaneous malignancy is a well-recognized cause of cranial neuropathy (16), with partial or complete facial palsy, facial hypesthesia and/or pain occurring months to years after excision of a cutaneous malignancy. In some cases, this is the first manifestation of regional metastasis, but the patient may not even recall a history of prior facial skin cancer. Imaging (if performed without careful attention to technique) may be negative, and patients may be misdiagnosed with typical Bell's palsy if the seventh cranial nerve is involved. Perineural spread of tumor may rarely present with classic tic douloureux, though in some cases, facial dysesthesia may be erroneously labeled tic douloureux (17). In our cases, patient 1 had a known history of cutaneous malignancy, but patient 2 had no history of any cutaneous or mucosal lesion. Trigeminal neuropathy has been described in the setting of prostate cancer (18), though the lack of a definite bony mandibular lesion would be somewhat unusual, as the typical access to V3 is via an osseous metastasis that then invades the nerve. In both our patients, there was pathologic involvement of cranial nerve V as well as VII, and spread of tumor along the greater superficial petrosal nerve, an important connecting pathway between these two nerves, likely played a role in this pattern of spread.

There are some potential pitfalls in the MR imaging diagnosis of denervation. Traumatized muscles may appear similar to denervated muscle with T2 prolongation and enhancement, but there will often be associated subcutaneous edema and, of course, a history of trauma. Radiation therapy may also result in myositis, though muscles generally are quite radioresistant. In patient 1, prior radiation therapy with 6 MeV electrons had been given; these typically penetrate into tissue only 2 cm or so, and as an offset bolus had been used, only 1 cm of tissue penetration would have been expected. In the peripheral nervous system, specific muscles within presumed single-nerve territories have been shown to vary in the time necessary to develop signal intensity alteration (9), which can complicate the imaging diagnosis of denervation. Two explanations offered for this phenomenon are collateral nerve supply, which retards the evolution of MR imaging changes after denervation, or that fiber atrophy may occur at different rates in different muscles after denervation.

It should be recalled that normal facial nerves frequently show enhancement (19, 20). Martin-Duverneuil et al (20) suggested three criteria for pathologic enhancement of the facial nerve: enhancement outside the facial canal, extension of enhancement to the eighth nerve, and intense enhancement in the labyrinthine and/or mastoid segments. Both our patients meet criteria for pathologic enhancement, and the diagnosis of perineural spread of neoplasm was consistent with clinical and imaging features. Some cases may be far more subtle, though, and it may be that the combined finding of questionable asymmetrical facial nerve enhancement with denervation changes in the muscles of facial expression may be more compelling for invasion of the nerve than sim-

ply the questionably asymmetrical enhancement along the course of the nerve. Additionally, further investigation of signal alteration of mimetic muscles in facial nerve dysfunction may be of interest because the presence of this change could conceivably have prognostic significance. Clinicians spend considerable effort on neurophysiological testing (nerve excitability testing, evoked electromyography, and spontaneous electromyography) to help stratify patients with favorable prognoses from those likely to suffer long-term cosmetically and functionally significant deformity. Imaging both CN VII and facial musculature in a sizeable cohort of patients with total paralysis due to Bell's palsy (mononeuritis) might demonstrate that signal change in target muscles correlates with adverse outcome due to a more severe degree of neural injury. If this proves to be valid, then routine imaging of facial palsy, including both nerve pathway and target musculature, could provide both diagnostic and prognostic benefit.

It is of interest that the MR imaging correlates of denervation change in the muscles of facial expression have not been previously reported, since the imaging pattern is so well described in other cranial nerve motor neuropathies. An obvious explanation would be the small size of these muscles, which makes them much more difficult to assess than the muscles of mastication or the tongue. Additionally, when patients with a lower motor neuropathy of CN VII are imaged, the focus is generally on covering the nerve from its nuclear origin in the brain stem to its branching in the parotid gland, and the more anteriorly located muscles of facial expression may not always be included in the field of view. Finally, a patient with a lower motor neuron lesion of CN VII is usually clinically obvious and imaging is directed at establishing the etiology of this palsy rather than the end-organ appearance. This is in contrast to lesions of V3 and XII, which may be relatively occult in terms of clinical symptomatology or overlooked on clinical examination. Therefore, the motor atrophic patterns on imaging may be very helpful in directing the clinician to a head and neck neoplasm or brain stem lesion, or confirming a lesion in a questionable case (1).

Conclusion

The identification of characteristic patterns of denervation atrophy on cross-sectional imaging examinations of the head and neck is a useful indication of dysfunction of motor cranial nerves. Atrophy of the muscles of facial expression has been previously noted on CT scans obtained from patients with facial palsy. We report two patients with facial nerve dysfunction secondary to perineural spread of tumor who developed subacute denervation changes in the muscles of facial expression, which were disclosed by MR imaging.

References

1. Harnsberger HR, Dillon WP. **Major motor atrophic patterns in the face and neck: CT evaluation.** *Radiology* 1985;155:665–670
2. Russo CP, Smoker WRK, Weissman JL. **MR appearance of trigeminal and hypoglossal motor denervation.** *AJNR Am J Neuroradiol* 1997;18:1375–1383
3. Davis SB, Mathews VP, Williams DW. **Masticator muscle enhancement in subacute denervation atrophy.** *AJNR Am J Neuroradiol* 1995;16:1292–1294
4. Murakami R, Baba Y, Nishimura R, et al. **MR of denervated tongue: temporal changes after radical neck dissection.** *AJNR Am J Neuroradiol* 1998;19:515–518
5. Jacobs CJ, Harnsberger HR, Lufkin RB, Osborn AG, Smoker WR, Parkin JL. **Vagal neuropathy: evaluation with CT and MR imaging.** *Radiology* 1987;164:97–102
6. Romo LV, Curtin HD. **Atrophy of the posterior cricoarytenoid muscle as an indicator of recurrent laryngeal nerve palsy.** *AJNR Am J Neuroradiol* 1999;20:467–471
7. Uetani M, Hayashi K, Matsunaga N, Imamura K, Ito N. **Denervated skeletal muscle: MR imaging.** *Radiology* 1993;189: 511–515
8. Uetani M, Hayashi K, Hashmi R, Nakahara N, Aso N, Ito N. **Traction injuries of the brachial plexus: signal intensity changes of the posterior cervical paraspinal muscles on MRI.** *J Comput Assist Tomogr* 1997;21:790–795
9. Fleckenstein JL, Watumull D, Conner KE, et al. **Denervated human skeletal muscle: MR imaging evaluation.** *Radiology* 1993; 187:213–218
10. Kullmer K, Sievers KW, Reimers CD, et al. **Changes of sonographic, magnetic resonance tomographic, electromyographic, and histopathologic findings within a 2-month period of examinations after experimental muscle denervation.** *Arch Orthop Trauma Surg* 1998;117:228–234
11. Dort JC, Zochodne D, Fan Y, Prychitko J, Peeling J. **Biochemical changes in denervated muscle identified by magnetic resonance spectroscopy.** *J Otolaryngol* 1997;26:368–373
12. Petersilge CA, Pathria MN, Gentili A, Recht MP, Resnick D. **Denervation hypertrophy of muscle: MR features.** *J Comput Assist Tomogr* 1995;19:596–600
13. Polak JF, Jolesz FA, Adams DF. **Magnetic resonance imaging of skeletal muscle. Prolongation of T1 and T2 subsequent to denervation.** *Invest Radiol* 1988;23:365–369
14. Schwarting S, Schroder M, Stennert E, Goebel HH. **Morphology of denervated human facial muscles.** *ORL J OtorhinolLaryngol Relat Spec* 1984;46:248–256
15. May M. **Anatomy for the clinician.** In: May M, Schaitkin BM, eds. *The Facial Nerve.* New York: Thieme; 2000:43–48
16. Catalano PJ, Sen C, Biller HF. **Cranial neuropathy secondary to perineural spread of cutaneous malignancies.** *Am J Otol* 1995; 16:772–777
17. Trobe JD, Hood CI, Parsons JT, Quisling RG. **Intracranial spread of squamous carcinoma along the trigeminal nerve.** *Arch Ophthalmol* 1982;100:608–611
18. Penaroccha Diago M, Bagan Sebastian JV, Alfaro Giner A, Escrig Orenga V. **Mental nerve neuropathy in systemic cancer. Report of three cases.** *Oral Surg Oral Med Oral Pathol* 1990;69:48–51
19. Gebarski SS, Telian SA, Niparko JK. **Enhancement along the normal facial nerve in the facial canal: MR imaging and anatomic correlation.** *Radiology* 1992;183:391–394
20. Martin-Duverneuil N, Sola-Martinez MT, Miaux Y, et al. **Contrast enhancement of the facial nerve on MRI: normal or pathological?** *Neuroradiology* 1997;39:207–212