

Are your **MRI contrast agents** cost-effective?

Learn more about generic **Gadolinium-Based Contrast Agents**.



FRESENIUS
KABI

caring for life

AJNR

Recanalization Results after Carotid Stent Placement

Joachim Berkefeld, Bernd Turowski, Andreas Dietz, Heinrich Lanfermann, Matthias Sitzer, Thomas Schmitz-Rixen, Helmuth Steinmetz and Friedhelm E. Zanella

This information is current as of April 19, 2024.

AJNR Am J Neuroradiol 2002, 23 (1) 113-120
<http://www.ajnr.org/content/23/1/113>

Recanalization Results after Carotid Stent Placement

Joachim Berkefeld, Bernd Turowski, Andreas Dietz, Heinrich Lanfermann, Matthias Sitzer, Thomas Schmitz-Rixen, Helmuth Steinmetz, and Friedhelm E. Zanella

BACKGROUND AND PURPOSE: The details of stent reconstruction in the vascular lumen and of the adaptation of carotid stents, the vessel wall, and the vascular anatomy are only occasionally reported. The purpose of this study was to determine the immediate and longer-term anatomic results after implantation of self-expanding carotid stents.

METHODS: In a retrospective study, pre- and postprocedural angiograms and duplex sonograms from 40 consecutive carotid stent procedures in 39 patients (22 men, 17 women; mean age, 67 years; age range, 53–84 years) with high-grade ($\geq 70\%$) internal carotid artery (ICA) stenoses were evaluated to assess the expansion of the vascular lumen, apposition of the stent, and geometric changes in the ICA after the implantation of rolling-membrane and carotid Wallstents ($n = 22$) or Easy Wallstents ($n = 18$).

RESULTS: Optimal widening of the lumen and apposition of the stent were achieved in 11 (28%) of 40 arteries. Residual stenoses ($n = 16$), free stent filaments not attached to the vessel wall ($n = 21$), and stent-induced kinking of the ICA ($n = 6$) were minor shortcomings of stent reconstruction. Because of one death, peri-interventional morbidity and mortality rates were 3%. During follow-up (median, 24 months), one high-grade restenosis, one ipsilateral stroke, and two ipsilateral transient ischemic attacks were observed.

CONCLUSION: Suboptimal anatomic results frequently occur after endovascular treatment of atherosclerotic carotid artery stenosis with self-expanding Wallstents. With the exception of one symptomatic restenosis, no major complications or longer-term sequelae were clearly related to these findings, but further controlled follow-up studies of larger samples are required.

Endovascular treatment of carotid artery stenosis with the implantation of self-expanding stents is increasingly proposed as an alternative to carotid endarterectomy. High technical success rates with carotid stent placement have been documented (1–4), and angiographic recanalization results are commonly described in terms of resolution of the stenosis or luminal gain (5). However, details of stent reconstruction in the vascular lumen and of the adaptation of carotid stents, the vessel wall, and the vascular anatomy are only occasionally mentioned (6, 7). Carotid stents have to comply with changing diameters of the common carotid artery (CCA), the carotid bulb, and the

internal carotid artery (ICA), as well as with tortuosity of the vessel. Furthermore, they should reestablish a wide, smooth lumen in a stenotic artery with an irregular surface and with the rigid calcified material of the atherosclerotic plaque.

After our initial experiences, we surmised that the mechanical properties of the currently and most frequently implanted self-expanding Wallstents might not support each of these demands. Therefore, the purpose of this retrospective study was to systematically analyze stent reconstructions of stenotic carotid arteries, with a focus on the adaptation between the Wallstents and vascular anatomy and pathologic characteristics. The first set of data from a prospective follow-up study are provided to help in the identification of potential risk factors that influence the long-term patency of the stents and the prevention of stroke.

Methods

Patient Selection

Between 1997 and 2000, 52 extracranial carotid stent procedures were performed in 51 patients in whom high-grade carotid artery stenoses had been diagnosed at clinical neurologic examination and Doppler and duplex sonography. Prior to

Received February 27, 2001; accepted after revision July 19, 2001.

From the Institute of Neuroradiology (J.B., B.T., H.L., F.E.Z.), the Neurology Clinic (A.D., M.S., H.S.), and the Department of Vascular Surgery (T.S.-R.), Johann Wolfgang Goethe-University of Frankfurt am Main, Germany.

Address reprint requests to Dr Joachim Berkefeld, Institute of Neuroradiology, Klinikum der Johann Wolfgang Goethe-Universität Frankfurt am Main, Schleusenweg 2–16, 60528 Frankfurt am Main, Germany.

therapeutic decisions, all patients underwent diagnostic angiography and CT or MR imaging of the brain. The carotid stent was approved by our local ethics committee. Our institutional review board approved the study protocol, and all patients provided written informed consent.

The indication for endovascular treatment was determined by means of an interdisciplinary conference between neurologists (A.D., M.S., H.S.), vascular surgeons (T.S.-R.), and neuroradiologists (J.B., B.T.). We selected digital subtraction angiographic (DSA) and Doppler sonographic studies of 40 consecutive interventions performed in 39 patients with high-grade atherosclerotic stenoses for retrospective imaging analysis of the vascular anatomy before and after stent placement. Patients with restenoses after carotid endarterectomy ($n = 7$) and other nonatheromatous lesions ($n = 5$) were excluded. The mean age of the selected patients (22 men, 17 women) was 67 years (range, 53–84 years). All stenoses chosen for review were 70% or greater, as measured angiographically according to the North American Symptomatic Carotid Endarterectomy Trial (NASCET) criteria (8). In addition to the 34 symptomatic lesions, we treated six asymptomatic plaques that caused progressive stenosis of luminal narrowing of 80% or greater. Because of obstructions in several cerebral vessels, concomitant diseases, or old age, the patients scheduled for endovascular treatment were supposed to be high-risk candidates for carotid endarterectomy. For these reasons, 27 (69%) of them would not have met the NASCET inclusion criteria (8).

Interventional Technique

All stent procedures were performed with anesthesiologic monitoring and neurologic control. The patients received antiplatelet therapy, with a combination of 100 mg acetylsalicylic acid and 75 mg clopidogrel, which was started 3 days before the intervention and continued for 3 months. A bolus of heparin, 150 IU/kg, was given only during the stent procedure. After 3 months, monotherapy with acetylsalicylic acid, 100 mg, was administered permanently.

All stents were implanted via a transfemoral approach through an 8F or 9F guiding catheter with balloon protection, according to the technique initiated by Théron et al (2). Angioplasty was performed and the stent deployed with temporary balloon occlusion of the distal ICA. Blood flow was not restored until potential emboli had been aspirated or flushed into the external carotid artery (ECA) territory. In the first 24 procedures, we used a 3-mm-long custom-made microcatheter (Cordis, Miami, FL) with a hand-mounted latex balloon (Nycomed, Paris, France) at its tip for protection. A steerable guidewire with an integrated balloon (Guard Wire; Percu-Surge, Sunnyvale, CA) was used to replace the handmade catheter during the last 16 stent procedures. The stenosis was predilated with a percutaneous transluminal angioplastic (PTA) balloon catheter (3-mm diameter, 20-mm length) if the caliber of the stent delivery system exceeded the diameter of the residual lumen.

Self-expanding Easy Wallstents (Schneider-Boston-Scientific, Galway, Ireland) ($n = 18$); rolling membrane Wallstents ($n = 6$); and carotid Wallstents ($n = 18$) with nominal sizes of 8-mm diameter, 20-mm length ($n = 4$); 8-mm diameter, 30-mm length ($n = 21$); 10-mm diameter, 30-mm length ($n = 9$); and 10-mm diameter, 40-mm length ($n = 8$) were implanted to cover the entire plaque. Two patients received two stents. After stent deployment, all stenoses were postdilated with 5-mm to 2-cm PTA balloons. Preinterventional high-resolution color-coded duplex sonography (Elegra; Siemens, Erlangen, Germany) with a 7.5-MHz linear probe was performed to determine the diameters of the CCA, ICA, and residual lumen, as well as the length of the stenosis for correct sizing of the stents and PTA balloons. All stent diameters were adapted to the diameter of the CCA or carotid bulb and oversized in relation to the ICA diameter.

Anatomic Results of Treatment

Two neuroradiologists (J.B., H.L.) without knowledge of the corresponding sonographic findings reviewed the pre- and postinterventional angiograms. Two certified operators (B.T., A.D.) performed high-resolution sonography. The same operator (J.B.), who had knowledge of all angiographic findings and who collected the data from the sonographers after the evaluation of the angiograms, implanted all stents. Angiographic images were discussed with a second angiographic evaluator (H.L.) who was not involved in the interventional procedures.

All pre- and postinterventional angiograms of the carotid bifurcation were obtained in three projection planes: posteroanterior, lateral, and 45° ipsilateral anterior oblique. The percentage of stenosis before and after treatment was measured at the site of maximal luminal narrowing, according to the NASCET criteria, with a reference diameter of the healthy distal ICA above the lesion, carotid bulb, or upper end of the stent (8).

Angiographic plaque morphology was used to distinguish between concentric and eccentric lesions and between smooth and irregular plaque surfaces and to determine the presence of typical ulceration or calcification (seen as irregular hyperopacities on DSA images).

The adaptation between stent and vascular anatomy were evaluated by using the following criteria: 1) the degree of residual stenosis was measured and compared with the preinterventional percentage of luminal narrowing; 2) whether the stent covered the total extent of the plaque was determined; 3) lack of apposition between stent filaments and vessel wall was described within healthy arterial segments, especially in the carotid bulb and in regions of former plaque ulcerations; and 4) stent-induced kinking of the ICA above the distal end of the stent was noted.

Angiographic criteria for the description of plaque and stent morphology were also applied to the evaluation of high-resolution duplex sonograms. Additionally, sonographic plaque morphology was used to distinguish echolucent, echodense, and mixed echogenic material. The perfused endovascular space was imaged by using the power Doppler mode (Fig 1).

The degree of residual stenosis and the plaque and stent morphologic findings were compared with Wallstents and/or carotid Wallstents and with Easy Wallstents. For statistical evaluation of quantitative data, nonparametric rank sum tests (Wilcoxon test, U test) were used. The frequencies of plaque morphologic findings were analyzed with χ^2 statistics.

Follow-up

Neurologic and Doppler sonographic examinations were performed before and immediately after stent placement, as well as at 1, 3, 6, and 12 months after stent placement; thereafter, they were performed at yearly intervals. In the first seven patients, repeat angiography was performed after 6 months, and these findings compared with Doppler and duplex sonographic findings. A team of experienced neurologists (A.D., M.S.) determined the peri-interventional complication rate (ipsilateral stroke and death rate) during the first 30 days and the neurologic event rate during follow-up. The restenosis rate and neointimal coverage of the stent was recorded at sonographic follow-up examinations. Patients with sonographic findings suggestive of a high-grade (>50%) restenosis were scheduled for repeat angiography. The completeness of the neointimal layer was evaluated with high-resolution sonography at the 6-month follow-up examination in all 39 patients by using the categories complete or partial visualization of the stent and complete or incomplete neointimal coverage (with the exception of the ECA origin).

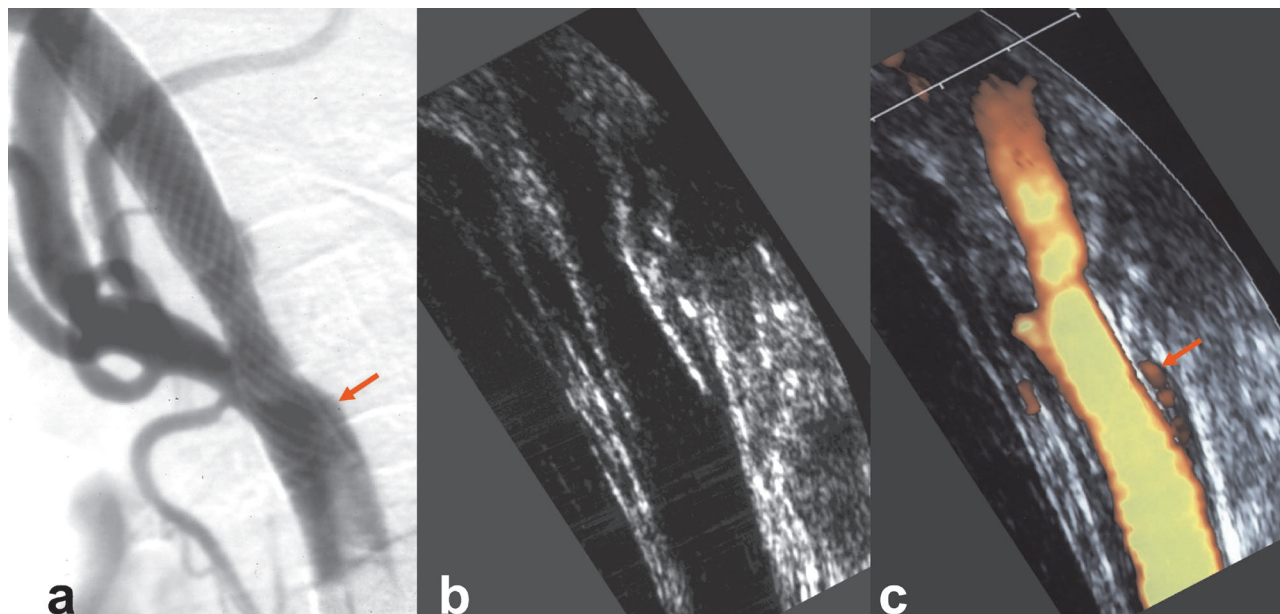


FIG 1. Suboptimal recanalization results after the placement of a self-expanding Easy Wallstent in the carotid artery. Images demonstrate a lack of apposition between the stent filaments and vessel wall at the bulging of the carotid bulb (arrow).

A, Angiogram shows residual stenosis resulting from stent recoil and gap between stent and arterial wall.

B and C, High-resolution duplex sonogram shows stent recoil after adequate postdilatation of the hyperechoic plaque and residual flow in the space between stent filaments and vessel wall.

Results

Angiographic Characteristics Before and After Stent Placement

All stenoses were close to the bifurcation, not exceeding a level of 2 cm below and 3 cm above the origin of the ECA. The bifurcation and the distal CCA were involved in 23 of 40 atheromatous lesions. Angiographic morphology indicated 32 concentric lesions that involved the whole circumference of the ICA and eight eccentric plaques. The lengths of the stenoses were 7–36 mm (mean, 15 mm). A smooth surface of the residual lumen was detectable in 18 cases, and 18 of 22 plaques with irregular residual lumen showed the typical niches of ulcerations. Calcification, shown as irregular hyperintensity on DSA images, was seen in 25 stenoses.

With two exceptions involving stenoses high above the carotid bulb, all stents bridged the bifurcation and the origin of the ECA. In two cases, misplacement of an Easy Wallstent occurred because of foreshortening that was other than that calculated, and a second stent had to be implanted to cover the entire plaque. Stent coverage of the entire atheromatous lesion was demonstrated angiographically in 37 of 40 cases. Three postprocedural angiograms showed further nonstenotic plaques in the distal CCA below the proximal end of the stent.

Stent implantation reduced the mean percentage of stenosis (according to the NASCET criteria) from 83.8% (SD, 8.7) to 6.3% (SD, 9.5), which is highly significant ($P < .001$, Wilcoxon test). Residual narrowings of 5–30% due to recoil of the stent after adequate postdilatation were observed in 16 rigid plaques. Calcification could be demonstrated angio-

graphically in 13 of these lesions. In none of the patients with residual stenoses did the angiograms show evidence of a hemodynamically relevant stenosis. Differences between rolling membrane or carotid Wallstents and the less shortening Easy Wallstents were not statistically significant (U test).

Carotid stent placement reduced the depth of ulcerations, and 11 of 18 angiographically proved ulcers were not detectable on angiograms obtained after stent placement. However, residuals of the remaining seven ulcerations were still visible as small niches. Outside of the ulcerations, a lack of apposition between the stent filaments and endothelial surface were demonstrated within the bulging of the carotid bulb, especially at the edge of eccentric plaques, in 14 cases (Fig 1). The diameter of the ECA origin decreased after stent placement in nine of 40 cases, and ECA occlusions did not occur.

Wallstent implantation induced kinking of the ICA above the distal end of the stent in six cases. The kinks were associated with moderate (30–50%) stenoses and had not been depicted on preinterventional angiograms. The stents tended to straighten curved ICA segments and upset the distal ICA above the prosthesis (Fig 2). All kinking occurred in patients with severe generalized atherosclerotic disease in whom stents were implanted into curved ICA segments. In two cases, the kinks released spontaneously after the guiding catheter was retrieved.

Moderate vasospasms occurred at the upper end of the stent or within the distal ICA where the protective balloon was located. None of the spasms were hemodynamically relevant, none persisted, and none required medical treatment. In three patients, angiograms obtained after stent placement showed

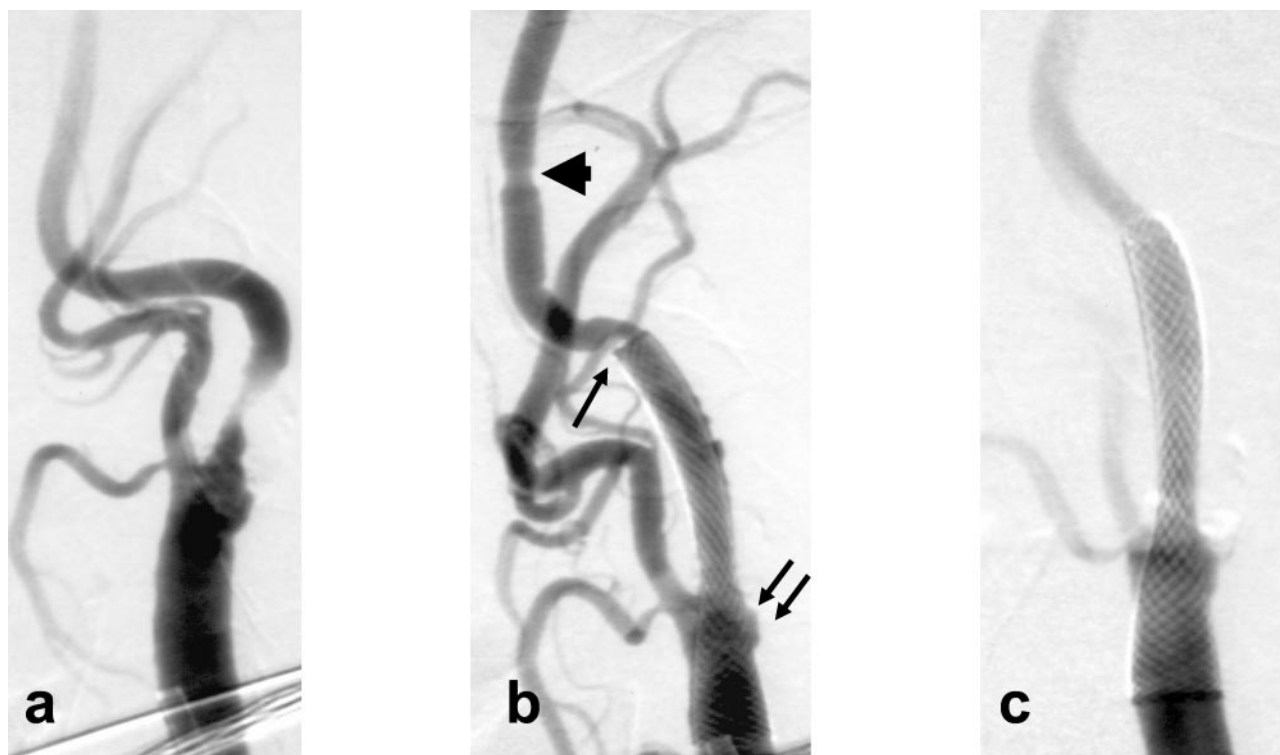


FIG 2. Geometric effects of a self-expanding carotid Wallstent in a 78-year-old woman with severe generalized atherosclerotic disease. A, High-grade stenosis close to the origin of the left ICA with calcified plaque material and an elongated tortuous course distal to the stenosis.

B, The stenosis, including the adjacent curve and carotid bifurcation, was covered with the stent, which was implanted with balloon protection. Note the straightening of the treated segment, with associated kinking and moderate stenosis above the distal end of the stent (arrow); the slight concentric vasospasm at the site of the inflated protective balloon (arrowhead); and stent recoiling and malapposition between the stent filaments and carotid bulb (double arrows).

C, The kinking resolved after rotation of the head to the opposite side.

moderate dilatation of the distal ICA at the site of the inflated protective balloon (Fig 3), but they showed no evidence of dissection or pseudoaneurysm. Table 1 contains an overview of the angiographic recanalization results.

Sonographic Characteristics Before and After Stent Placement

All stenoses were 70% or greater, according to Doppler criteria (acoustic evaluation, peak systolic velocity, and duplex measurement of local luminal narrowing). Sonographic plaque morphology confirmed eight echolucent lesions in eight, six echodense plaques, and 26 lesions of mixed echodensity. All 25 calcified plaques that were visible on DSA images had areas of increased echodensity. Duplex sonograms depicted an irregular surface in 16 plaques and showed coincident findings in 15 of 22 angiographically proved irregularities. Typical ulcer niches were detected with both imaging techniques in 10 cases, whereas sonograms caused eight further ulcerations to be missed; these were visible on angiograms. Immediately after the end of the stent placement procedure, color-coded duplex sonograms (power mode) showed residual stenosis in 18 of 40 cases (Table 2). All residual narrowings were located at the former maximum of the stenosis. According to Doppler and duplex crite-

ria, none of the residual stenoses exceeded 50%, and no evidence of hemodynamic relevance was present. In 15 patients, residual narrowings were associated with echodense plaques ($n = 5$) or areas of mixed echodensity ($n = 10$) due to plaque calcification. In addition to the angiographic findings, sonograms depicted three further plaques that were incompletely covered by the proximal end of the stent. High-resolution sonograms (obtained in power mode) depicted five of the seven angiographically proved residual ulcer niches that persisted after stent placement. Corresponding with angiographic findings, sonographic findings showed a lack of apposition between the stent filaments and vessel wall in 11 of 14 cases.

Sonograms failed to depict stent-induced kinking in two of six cases. In none of these patients did evidence of kinks or associated stenoses persist on postinterventional duplex sonograms obtained after 1 month. Results of the comparison of angiographic and sonographic findings proved the described, but statistically insignificant, differences in the detection rates of morphologic findings.

Clinical Outcome and Follow-up

Clinical evaluation revealed no procedure-related strokes. Three patients lacked collaterals and could not tolerate ICA occlusion (median time, 12 minutes;

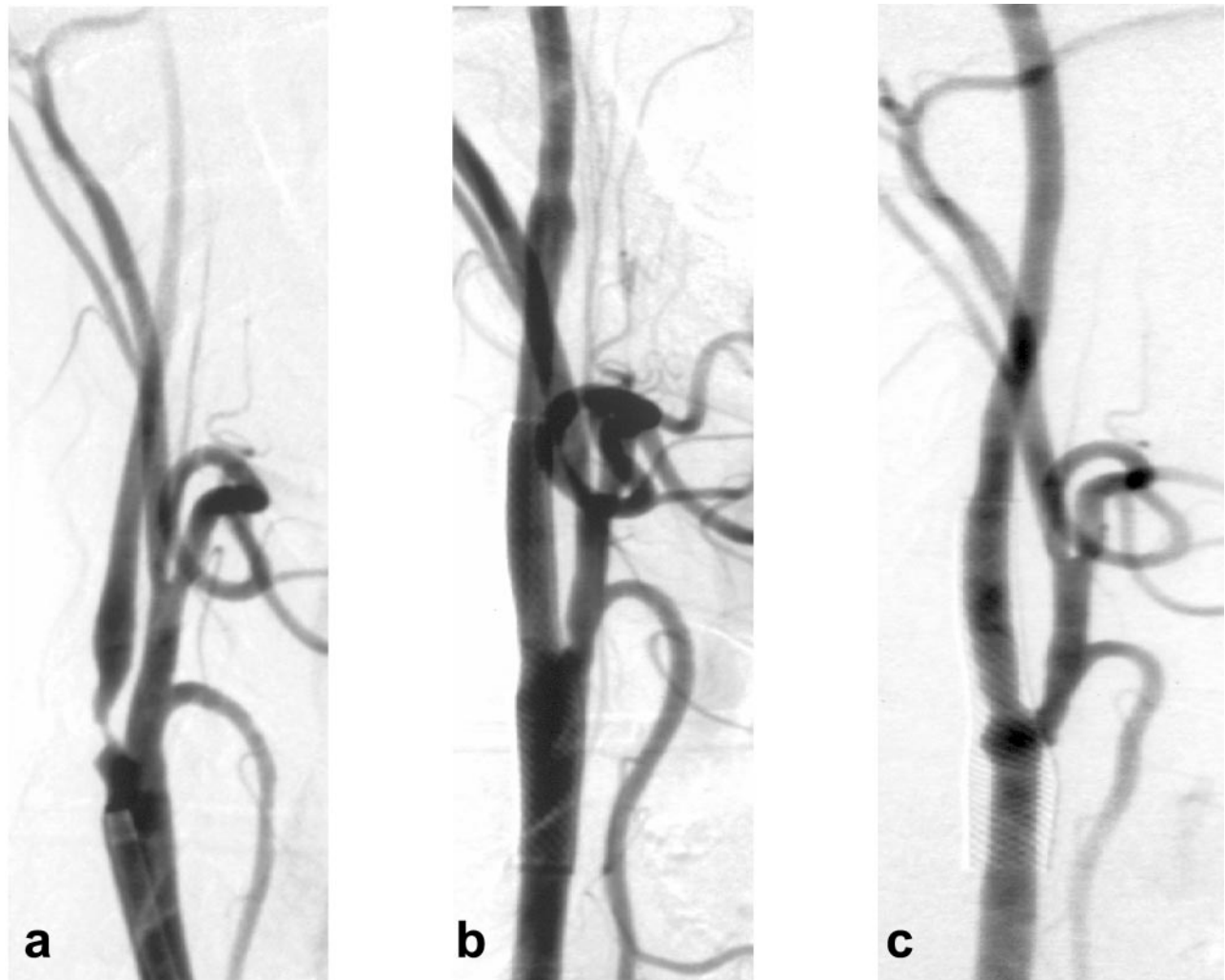


FIG 3. Follow-up angiograms obtained after stent placement.

A, High-grade stenosis at the origin of the ICA is seen.

B, Implantation of a Wallstent completely restored the vascular lumen. Note the slight narrowing at the origin of the ECA and minimal fusiform dilatation above the distal end of the stent at the site of the protective balloon.

C, After 6 mo, the stent is covered by a smooth layer of neointima, which is prominent within the distal CCA. At the flow divider at the bifurcation, a bulblike bulging is seen. The ECA remained patent. Dilatation at the former site of the protective balloon is no longer visible.

TABLE 1: Quality of vessel reconstruction after carotid stent placement

Angiographic Finding	Cases (%)		
	All (N = 40)	Wallstent and/or Carotid Wallstent (n = 22)	Easy Wallstent (n = 18)
Optimal widening of lumen and adaptation of stent	11 (28)	6 (27)	5 (28)
Residual stenosis	16 (40)	9 (41)	7 (39)
Stenosis of ECA origin	9 (23)	5 (23)	4 (22)
Residuals of ulcerations	7 (18)	3 (14)	4 (22)
Dehiscences of stent and vessel wall	14 (35)	6 (27)	8 (44)
Kinking of ICA distal to stent	6 (15)	4 (18)	2 (11)
Temporary spasm	10 (25)	5 (23)	4 (22)
Dilatation at the site of the protective balloon	3 (8)	3 (14)	0 (0)

Note.—Data in parentheses are percentages.

range, 8.5–28 minutes). They presented with symptoms of a hemispheric transient ischemic attack, which resolved completely in each case after immediate aspiration and deflation of the protective bal-

loon. One 72-year-old patient with multiple diseases died from sepsis within the first 30 days; thus, the peri-interventional ipsilateral stroke and death rate was 3%.

TABLE 2: Follow-up findings

Finding	End of	Follow-up				Follow-up			
	Procedure N = 40	1 mo n = 40	3 mo n = 39	6 mo n = 39	Angiography n = 7	Sonography n = 7	12 mo n = 28	24 mo n = 19	36 mo n = 8
Neurologic event									
Any stroke	0 (0)	0 (0)	0 (0)	2 (5)	0 (0)	0 (0)	0 (0)	0 (0)	0 (0)
Ipsilateral stroke	0 (0)	0 (0)	0 (0)	1 (3)	0 (0)	0 (0)	0 (0)	0 (0)	0 (0)
Ipsilateral transient ischemic attack	3 (8)	0 (0)	0 (0)	1 (3)	0 (0)	0 (0)	1 (4)	0 (0)	0 (0)
Any death	0 (0)	1 (3)	0 (0)	0 (0)	0 (0)	0 (0)	0 (0)	0 (0)	0 (0)
Sonographic finding									
Residual stenosis (all cases, <30%)	18 (45)	14 (35)	13 (33)	11 (28)	2 (3)	2 (3)	0 (0)	0 (0)	0 (0)
Restenosis >50%	0 (0)	0 (0)	0 (0)	1 (3)	1 (1)	1 (1)	0 (0)	0 (0)	0 (0)
ECA stenosis	9 (23)	0 (0)	0 (0)	9 (23)	2 (3)	2 (3)	0 (0)	0 (0)	0 (0)
Residual ulcerations	5 (13)	0 (0)	0 (0)	2 (5)	1 (1)	1 (1)	0 (0)	0 (0)	0 (0)
Lack of apposition stent-vessel wall	11 (28)	0 (0)	0 (0)	6 (15)	1 (1)	1 (1)	0 (0)	0 (0)	0 (0)
Incomplete stent coverage of the plaque	6 (15)	0 (0)	0 (0)	—	0 (0)	0 (0)	0 (0)	0 (0)	0 (0)
Incomplete neointimal coverage	0 (0)	0 (0)	0 (0)	11 (28)	2 (3)	2 (3)	0 (0)	0 (0)	0 (0)
Stent-induced kinking	4 (10)	0 (0)	0 (0)	0 (0)	0 (0)	0 (0)	0 (0)	0 (0)	0 (0)

Note.—Data in parentheses are percentages.

In a median follow-up interval of 24 months (range, 6–44 months), one major ipsilateral stroke occurred months after stent placement in a 78-year-old patient who had moderate stent-induced kinking of the ICA. Furthermore, she had generalized atherosclerotic disease and cardiac insufficiency. High-resolution duplex sonograms showed complete neointimal coverage of the stent and normal flow, but they showed no evidence of persistent kinking, endoluminal thrombus, or residual or recurrent stenosis.

One restenosis that exceeded 50% was observed during follow-up. In one of the two patients who received two stents to cover the entire plaque, a 70% restenosis developed within the overlapping zone of the two prostheses, which was located at the former maximum of the stenosis. The lesion was symptomatic months after stent implantation, when amaurosis fugax developed. However, the lesion was successfully dilated, and the symptoms did not recur with continued antiplatelet therapy.

In another case with a residual ulceration, clinical symptoms of an ipsilateral transient ischemic attack occurred 12 months after stent placement. This patient had an additional ulcerated 50% stenosis at the carotid siphon, as well as coronary heart disease. He became free from further transient ischemic attacks after he was treated with a combination of acetylsalicylic acid and clopidogrel, instead of monotherapy with acetylsalicylic acid.

With the exception of the patient with the high-grade restenosis, 6-month follow-up angiograms (obtained in the first seven stent cases) as well as high-resolution duplex sonograms (available for 39 patients) showed thin, smooth, neointimal coverage of the stent. Follow-up sonograms obtained at 6 months demonstrated incomplete neointimal coverage of 11 stents, including those in eight patients with residual ulcerations (n = 2) or other gaps between the stent filaments and endothelium (n = 6). Because of the high position of the distal end of the stent (n = 4) or dense calcification (n = 3), seven endoluminal

stent surfaces were only partially visualized at sonography. At the region of the bifurcation, the thickness of neointima partly increased in six patients, and modeling of a new carotid bulb was observed (Fig 3).

The number of patients with residual stenoses at the former maximum decreased from 18 immediately after stent placement to 11 after 6 months. Postinterventional narrowings of the ECA origin persisted, and progressive ECA stenosis or occlusion was not observed. Sonograms obtained after 6 months depicted no residual stent-induced kinking or stenoses at the distal end of the stent.

Four of the first seven patients who underwent routine follow-up angiography after 6 months had incomplete apposition between the stent and arterial wall (two with residual deep ulcerations and two with other dehiscences of the stent filaments) immediately after stent implantation. Six-month follow-up angiograms confirmed the presence of two small residual stent dehiscences. In these cases, the results of sonographic evaluation were equivalent (Table 2).

Discussion

These findings confirm other data suggesting that self-expanding carotid stents substantially expand the vascular lumen and improve the luminal diameter (5). Self-expanding Wallstents and Easy Wallstents, however, have limited radial forces (9), and moderate recoil of the stent was observed despite adequate postdilatation in 40% of the patients, especially in those with heavily calcified plaques. Easy Wallstents with lesser expansion forces had a slight tendency to cause more prominent recoil, compared with rolling membrane or carotid Wallstents. However, the small difference was not statistically significant. To date, these residual stenoses had no serious consequences at midterm follow-up, and, contradicting findings in the literature (6), an increased incidence of restenoses was not observed. In only one patient in our series with a high-grade restenosis did stent recoil occur

after adequate postdilatation in the overlapping zone of two Easy Wallstents. Aside from the residual stenosis, an increased amount of foreign material might be another risk factor for increased intimal proliferation in this case (10, 11). Wallstents and other self-expanding prostheses continue to expand after implantation, and better expansion of the lumen might be achieved with time (12); this factor might explain the observation that the number of cases with residual narrowings decreased within the first months.

The diameter of self-expanding stents that bridge the bifurcation is chosen according to the diameter of the CCA. The stent portion that extends into the ICA is oversized in relation to the smaller diameter of this vessel and has a denser mesh because of incomplete expansion. Generally, the adaptation of the Wallstents to the two diameters was acceptable, and similar to Piamsomboon et al (5), we observed no negative adverse effects related to this implantation technique. Restenoses in the region distal to the upper end of the stent have not been observed during follow-up, despite the different biomechanical properties at the transition zone between the segment with the stent and the healthy part of the vessel.

Compliance between the stent and changing vessel wall diameters, however, was limited in the region of the carotid bulb. Especially in cases with eccentric plaques, a lack of apposition between the stent filaments and the arterial wall occurred frequently, and delayed neointimal coverage was proven angiographically and sonographically. Until now, free stent filaments in the region of stent dehiscences and at the patent ECA origin were not associated with an increased rate of thromboembolic events. Only one patient with a residual deep ulcer had a transient ischemic attack during follow-up; however, whether a tandem intracranial stenosis or cardiac embolus was responsible for the symptoms was unclear. Despite this questionable complication of uncovered stent filaments, repeated postdilatation with the aim of increasing attachment of the stent filaments to the vessel wall cannot be recommended. Each balloon inflation prolongs the procedure and increases the risk of thromboembolic material formation or detachment (4).

Experimental findings have shown that Wallstents bridging the origin of renal arteries do not induce microemboli in the dependant renal parenchyma. According to experimental data (13), free filaments of Wallstents are covered by a layer of endothelial cells that minimize thrombogenicity. However, other materials and stent designs may behave differently in this regard (14).

In addition to the described radial stent effects, we observed limited compliance with curves and tortuosities of the carotid artery; this was probably related to the known longitudinal forces of the self-expanding Wallstent (9). Tortuous vessel segments, as well as angulations at the bifurcation, were straightened, and transferrals of curves associated with kinks and moderate stenoses occurred because of longitudinal compression of the ICA distal to the upper end of the stent. This phenomenon was especially observed in

older patients with severe generalized atherosclerotic disease, in whom almost complete loss of elastic components might be one explanation for the kinking. Removal of the guiding catheter and further foreshortening of the stent after implantation seem to be factors that support spontaneous resolution of kinking during follow-up. One major stroke occurred during follow-up in a case with stent-induced kinking, but sonograms showed no persistence of this kink. The vessel was widely patent, and no source of emboli was detected. Cardiac embolism was considered the most probable cause of this severe ipsilateral event. Théron et al (6) described the complication of a stent that ended in a curved ICA segment and suggested covering the entire curve to increase the length of the stent. With this technique, stents must be placed in large portions of the carotid artery outside the atheromatous plaque. More flexible prostheses, such as segmented nitinol stents, might provide a better adaptation between the stent filaments and vascular curves. Because of minimal foreshortening during deployment, exact placement is possible, and shorter stents that just cover the entire plaque can be used to minimize the longitudinal effects on vascular geometry (15).

No major complications of balloon protection were detected during this study. Moderate vasospasm without hemodynamic relevance and circumscribed dilatation at the site where the protective balloon was inflated appeared to be benign. No evidence of dissection was found on angiographic or sonographic images. Angiographic and high-resolution duplex sonographic findings were nearly equivalent in the evaluation of plaque and stent morphology. Angiograms were superior in the detection of small ulcers and gaps between stent filaments and vessel wall, whereas sonograms depicted more echodensities as correlates of plaque calcifications, but these differences were not significant. In nine of 39 cases, sonographic evaluation of the stented carotid artery was impeded by the partial visibility of the prosthesis. Intravascular sonography could have been used to overcome this limitation, and its use has been proposed for the assessment of the deployed stent during intervention (16). Invasiveness and high cost render routine use of this tool difficult. External high-resolution sonography is useful to detect the majority of morphologic details in patients with carotid stents, and it should be the first imaging tool chosen for follow-up examinations (17).

After endovascular treatment of carotid stenoses with self-expanding Wallstents, postprocedural angiograms and high-resolution sonograms frequently depict incomplete expansion of the vascular lumen and a lack of compliance between stent geometry and vascular anatomy. Despite these suboptimal anatomic results, peri-interventional complication rates and midterm follow-up results reveal an acceptable clinical and vascular outcome and confirm the results of other nonrandomized studies (1-3, 5, 18, 19). No clear correlation between the quality of stent reconstruction and the occurrence of ipsilateral neurologic

events was proved in this study, but minimization of potential procedure-related risks requires further improvement of the compliance between self-expanding stents and the vascular anatomy.

Acknowledgment

The authors thank Professor J. Théron for introducing the technique of balloon-protected stent placement in carotid artery stenoses and for his help in establishing the use of this method in our center.

References

1. Yadav JS, Roubin GS, Iyer S, et al. **Elective stenting of the extracranial carotid arteries.** *Circulation* 1997;95:376–381
2. Théron J, Payelle GG, Coskun O, Huet HF, Guimaraens L. **Carotid artery stenosis: treatment with protected balloon angioplasty and stent placement.** *Radiology* 1996;201:627–636
3. Mathias K. **Stent placement in arteriosclerotic disease of the internal carotid artery.** *J Intervent Cardiol* 1997;10:469–477
4. Henry M, Amor M, Masson I, et al. **Angioplasty and stenting of extracranial carotid arteries.** *J Endovasc Surg* 1998;5:293–304
5. Piamsomboon C, Roubin GS, Liu MW, et al. **Relationship between oversizing of self-expanding stents and late loss index in carotid stenting.** *Cathet Cardiovasc Diagn* 1998;45:139–143
6. Théron J, Guimaraens L, Coskun O, Sola T, Martin JB, Rüfenacht DA. **Complications of carotid angioplasty and stenting.** *Neurosurg Focus* 1998;5:article 4 [on-line publication]
7. Phatouros C, Higashida RT, Malek AM, et al. **Carotid artery stent placement for atherosclerotic disease: rationale, technique and current status.** *Radiology* 2000;217:26–41
8. **Beneficial effect of carotid endarterectomy in symptomatic patients with high grade stenosis: North American Symptomatic Carotid Endarterectomy Trial collaborators.** *N Engl J Med* 1991;325:445–453
9. Barth KH, Vimani R, Froelich J, et al. **Paired comparison of vascular wall reactions to Palmaz stents, Strecker tantalum stents, and Wallstents in canine iliac and femoral arteries.** *Circulation* 1996;93:2161–2169
10. Harnek J, Zoukas E, Carlemalm E, Cwikiel W. **Differences in endothelial injury after balloon angioplasty, insertion of balloon-expanded stents or release of self-expanding stents: an electron microscopic experimental study.** *Cardiovasc Intervent Radiol* 1999;22:56–61
11. Rogers C, Edelman ER. **Endovascular stent design dictates experimental restenosis and thrombosis.** *Circulation* 1995;91:2995–3001
12. Ozaki Y, Keane D, Ruygrok P, van der Giessen WJ, de Feyter P, Serruys PW. **Six month clinical and angiographic outcome of the new, less shortening Wallstent in native coronary arteries.** *Circulation* 1996;93:2114–2120
13. Consigny PM. **Endothelial cell seeding on prosthetic surfaces.** *J Long Term Effects Med Implants* 2000;10:79–95
14. Birch PC, Start RD, Whitbread T, Palmer I, Gaines PA, Beard JD. **The effects of crossing porcine renal artery ostia with various endovascular stents.** *Eur J Vasc Endovasc Surg* 1999;17:185–190
15. Phatouros CC, Higashida RT, Malek AM, et al. **Endovascular stenting for carotid artery stenosis: preliminary experience using the shape-memory-alloy-recoverable-technology (SMART) stent.** *AJNR Am J Neuroradiol* 2000;21:732–738
16. Satler LF, Hoffmann R, Lansky A, et al. **Carotid stent-assisted angioplasty: preliminary technique, angiography, and intravascular ultrasound observations.** *J Invasive Cardiol* 1996;8:23–30
17. Robbin ML, Lockhart ME, Weber TM, et al. **Carotid artery stents: early and intermediate follow-up with Doppler US.** *Radiology* 1997;205:749–756
18. Vitek JJ, Roubin GS, Al-Mubarak N, New G, Iyer SS. **Carotid artery stenting: technical considerations.** *AJNR Am J Neuroradiol* 2000;21:1736–1743
19. Wholey MH, Wholey M, Mathias K, et al. **Global experience in cervical carotid artery stent placement.** *Catheter Cardiovasc Intervent* 2000;50:168–169