

Are your MRI contrast agents cost-effective?

Learn more about generic Gadolinium-Based Contrast Agents.



FRESENIUS
KABI

caring for life

AJNR

Diffusion-Weighted MR Imaging in the Acute Phase of Transient Ischemic Attacks

Alex Rovira, Antoni Rovira-Gols, Salvador Pedraza, Elisenda Grivé, Carlos Molina and José Alvarez-Sabín

AJNR Am J Neuroradiol 2002, 23 (1) 77-83

<http://www.ajnr.org/content/23/1/77>

This information is current as of April 18, 2024.

Diffusion-Weighted MR Imaging in the Acute Phase of Transient Ischemic Attacks

Alex Rovira, Antoni Rovira-Gols, Salvador Pedraza, Elisenda Grivé, Carlos Molina, and José Alvarez-Sabín

BACKGROUND AND PURPOSE: Radiologic assessment of acute transient ischemic attacks (TIAs) has been handicapped by the low sensitivity of CT and conventional MR imaging for acute small-vessel infarction and the difficulty in differentiating between acute and chronic lesions by use of these methods. Our purpose was to evaluate the incidence of TIA-related infarction by using diffusion-weighted MR imaging to determine whether the presence of a diffusion imaging abnormality correlates with the duration of symptoms or cause of TIA.

METHODS: We prospectively studied 58 consecutive patients with acute TIA by use of diffusion-weighted imaging. All MR imaging was performed with a 1.5-T whole-body system with 24-mT/m gradient strength and an echo-planar-capable receiver. All patients were imaged within 10 days of stroke onset.

RESULTS: Thirty-nine patients (67%) manifested a diffusion imaging abnormality consistent with acute ischemia. Cortical lesions were identified in 54% of these patients; most of them associated with other acute ischemic lesions. Subcortical lesions were identified in 46%; most of them were isolated from other lesions.

The mean duration of symptoms in patients with no TIA-related diffusion imaging abnormalities was 0.96 hours (median, 0.33 hours) compared with a mean of 6.85 hours (median, 1.53 hours) in patients with diffusion imaging abnormalities ($P = .025$, Mann-Whitney U test). This significant correlation between the duration of TIA symptoms and the presence of TIA-related abnormalities was lost when we excluded from the analysis patients whose symptoms lasted longer than 6 hours ($P = .513$, Mann-Whitney U test).

No significant correlation was observed between the size of TIA-related lesions and the duration of symptoms or cause of TIA.

CONCLUSION: Two thirds of our TIA patients showed focal abnormalities indicative of acute ischemic lesions on diffusion-weighted images. This incidence is higher than that previously reported in the literature. The presence of such abnormalities increased with increasing total symptom duration, but this relation was not observed when only patients whose symptoms lasted less than 6 hours were considered. No significant correlation was observed between the cause and presence of TIA-related lesions on diffusion-weighted MR images. These TIA-related lesions are probably irreversible and may lead to subsequent infarct.

Transient ischemic attacks (TIAs) are neurologic deficits caused by vascular disease that clear completely in less than 24 hours (1), although most of them have a much shorter duration of less than 1 hour (2). Patients who have had a TIA have a 24–29% estimated risk of stroke in the first 5 years after the event

(3). The risk is higher in the first month, especially in patients with hemispheric TIA and carotid stenosis (4) and probably increases in patients with a TIA-related infarct revealed on CT or MR images (5). Therefore, a TIA should be evaluated promptly so that therapy to decrease the risk of stroke can be established as soon as possible. The goals of imaging procedures are to identify candidates for specific surgical or pharmacologic therapy, determine prognosis, and exclude rare nonvascular causes (6).

Data on the frequency and type of TIA-related infarcts have been almost exclusively drawn from CT (5, 7–9) and conventional MR imaging (10) investigations. However, these studies have been handicapped by the low sensitivity of these radiologic tech-

Received May 11, 2001; accepted after revision August 13.

From the Departments of Radiology (A.R., A.R.-G., S.P., E.G.) and Neurology (C.M., J.A.-S.), Hospital Universitari Vall d'Hebron, Barcelona, Spain.

Address reprint requests to Alex Rovira, MD, Magnetic Resonance Unit (Department of Radiology), Hospital Universitari Vall d'Hebron, Passeig Vall d'Hebron 119–129 08035 Barcelona, Spain.

niques for detecting acute small-vessel infarction and differentiating acute from chronic lesions. Recent studies have shown diffusion-weighted MR imaging to be a highly sensitive and specific diagnostic technique for acute small-vessel infarction (11–15) by demonstrating neuroanatomically relevant focal abnormalities in nearly half of clinically defined TIA patients (16–18). The presence of TIA-related lesions becomes more and more likely as the duration of clinical symptoms advance, although it is not known whether the presence and number of TIA-related lesions correlate with etiologic factors.

Our purpose was to analyze the incidence of neuroanatomically relevant focal abnormalities in TIA patients that were revealed by diffusion-weighted MR imaging and to correlate the presence, number, and size of these focal lesions with the total duration of symptoms and causes of the attack.

Methods

Patients Selection

We studied 58 consecutive patients with TIA. Fifty-three of the patients were men and five women with an age range of 17–79 years (mean, 60 years). TIA was defined as an acute transient focal neurologic deficit caused by vascular disease that reversed totally within the first 24 hours of symptom onset (1). Patients with brain stem or hemispheric symptoms or both were included in the study, but patients with isolated amaurosis fugax were excluded. The following clinical data were collected from all patients: age, sex, symptom(s) of TIA, date and time of symptom onset, and date and time of symptom resolution. Thus, an estimation of TIA duration was available in all patients included in the study.

The pathogenesis of TIA was established in all patients according to the TOAST classification (19) on the basis of imaging and laboratory studies and from past clinical history and present clinical examination. This classification established five stroke subtype diagnoses: large-vessel disease with significant stenosis; large-vessel disease without significant stenosis; cardioembolic disease; small-vessel disease; more than one likely cause or unknown cause.

MR Imaging

All patients were examined with MR imaging within 10 days of stroke onset. Five patients (9%) were imaged within the first 2 days after symptom onset, 35 patients (60%) between the second and fifth day, and the remaining 18 (31%) after the sixth day. Before MR imaging, all cases had been studied with non-contrast-enhanced CT, and patients with nonischemic brain lesions were excluded from the study.

All MR imaging was performed with a 1.5-T whole-body system with a 24-mT/m gradient strength, 300-ms rise time, and echo-planar-capable receiver equipped with a gradient overdrive (Magnetom Vision Plus; Siemens Medical Systems, Erlangen, Germany).

Axial T2-weighted turbo spin-echo (3700/90/2 [TR/TE/excitations]), T1-weighted spin-echo (550/14/2), turbo fluid-attenuated inversion recovery (FLAIR) (9000/110/2), and echo-planar diffusion-weighted sequences were performed. The diffusion-weighted images were obtained with a single-shot spin-echo echo-planar pulse sequence with diffusion gradient b values of 0 and 1000 s/mm² along all three orthogonal axes over 15 axial sections, 5-mm-thick sections, intersection gap of 1.5 mm, 240-mm field of view, and 96 × 128 matrix. The acquisition time for the diffusion-weighted images was 25

seconds. To minimize the effects of diffusion anisotropy, the diffusion-weighted data were automatically processed to yield standard isotropic diffusion-weighted images.

Three of the authors (A.R., A.R.G., E.G.) retrospectively reviewed images, and findings were determined by consensus. Conventional T1- and T2-weighted images were assessed apart from diffusion-weighted images.

Initially, readers were blinded to the pattern of TIA symptoms and to any other clinical information. Subsequently, with knowledge of the TIA symptoms, the following items were recorded: 1) presence of a focal lesion (ie, index lesion) related to the TIA on a diffusion-weighted image; for example, a lesion located in a territory corresponding to the patient's symptoms and with acute ischemic characteristics such as hyperintensity in the isotropic diffusion-weighted images; 2) size of the index lesion on a diffusion-weighted image; and 3) presence of an acute or subacute ischemic lesion other than the index lesion (subsidiary infarcts). In a subgroup of nine patients who initially showed an index lesion, a follow-up MR investigation that included T1- and T2-weighted (fast spin-echo and fast-FLAIR) imaging was performed 2 to 6 months after the initial MR examination. In these patients, the follow-up MR examination was used to define the presence or absence of a subsequent infarct at the location of the index lesion. This analysis was performed without blinding the readers to the results of the initial MR examination.

In our study, we did not attempt to calculate the apparent diffusion coefficient (ADC) values of the ischemic lesions, because many of the lesions were so small that they were beyond the spatial resolution of current ADC detection.

Statistical Analysis

Statistical analysis was performed with the SPSS software package v. 7.5 (SPSS Inc., Chicago, IL). Depending on the behavior of the variables, significant differences were evaluated with one-way analysis of variance (ANOVA) or the Mann-Whitney U test. The χ^2 test was used to assess the correlation between TIA pathogenesis and the presence of an index lesion. A *P* value of <.05 indicated significance.

Results

Diffusion-weighted MR imaging showed an index lesion in 39 (67%) patients. Index lesions were cortical in 21 (54%) and subcortical in the remaining 18 (46%). In two patients, the index lesion was located in the brain stem (paramedial region of the pons) and was considered subcortical. Subsidiary infarctions were seen in 23 (59%) of the 39 patients; all but two were located in the same arterial territory as the index lesion. Most of the patients with a cortical index lesion had subsidiary infarcts (76%) (Fig 1), whereas most of the patients with a subcortical index lesion had no subsidiary infarcts (61%) (Fig 2).

An estimation of TIA duration was available in all patients. The mean duration of TIA symptoms in all patients was 10.70 hours. Mean duration of TIA symptoms in patients with no index lesion on diffusion-weighted images was 0.96 hours (median, 0.33 hours) compared with a mean duration of 6.85 hours (median, 1.53 hours) in patients with an index lesion (*P* = .025, Mann-Whitney U test). However, when we included only those patients whose symptoms lasted less than 6 hours (81% of patients) in the analysis, no significant differences were observed between the duration of symptoms and the presence of TIA-related

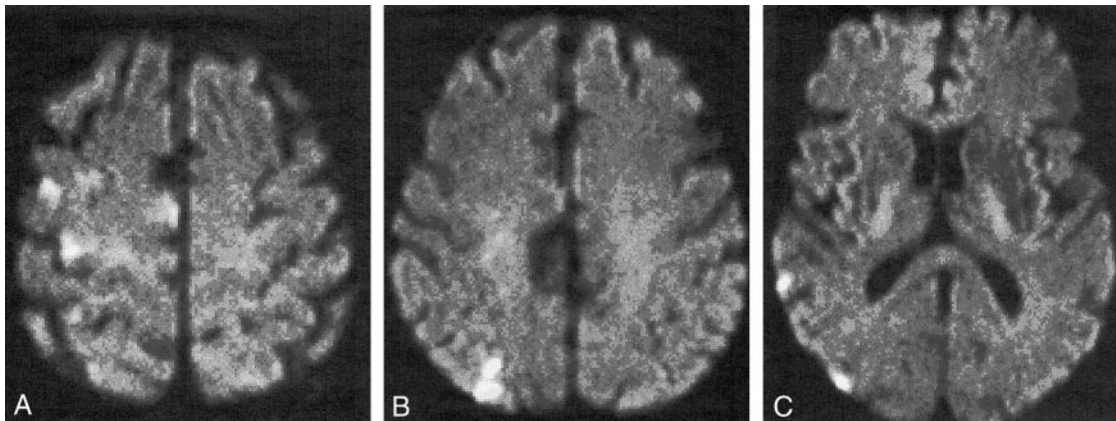


FIG 1. Diffusion-weighted images obtained in a 75-year-old man with transient left paresis.
 A, Axial diffusion-weighted image depicts hyperintense signal indicative of acute infarction in the precentral gyrus of the right frontal lobe.
 B and C, Additional subsidiary lesions in the same arterial territory (middle cerebral artery) are shown at different levels (parietal and temporal cortex).

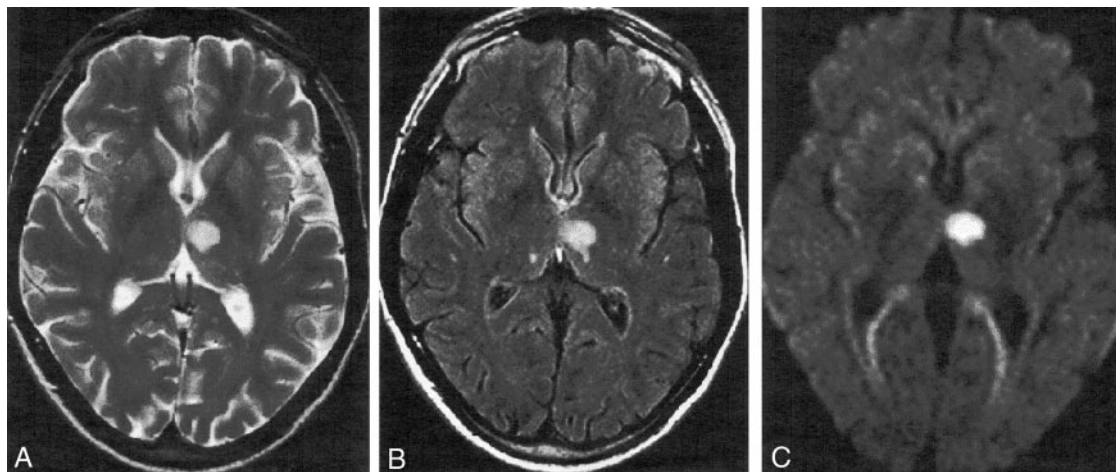


FIG 2. Axial MR images obtained in a 40-year-old man with transient right hemiparesis 5 days after onset of symptoms.
 A-C, T2-weighted (A), fast-FLAIR (B), and diffusion-weighted (C) imaging all reveal a small, acute ischemic lesion in the thalamo-capsular region equally well. Note absence of prior ischemic lesions in A and B that helped identify the TIA-related infarct.

abnormalities ($P = .513$, Mann-Whitney U test). All patients with an attack lasting more than 6 hours (11 patients) had a TIA-related focal abnormality on diffusion-weighted images, whereas only 59% of patients whose symptoms lasted less than 6 hours had a TIA-related lesion (Fig 3).

The mean time from symptom onset to MR imaging was 5 days (range, 1–9 days), and no significant difference existed between patients with and those without TIA-related infarcts. However, the contribution of diffusion-weighted imaging to the detection of TIA-related infarcts in relation to that of conventional MR imaging differed depending on the time from symptom onset to MR imaging. Diffusion-weighted images showed an index lesion not visualized on conventional MR images in 13% of patients (Fig 4), but this percentage increased to 25% when MR imaging was performed within the first 2 days after symptom onset. In 29% of patients, the index lesions visualized on diffusion-weighted images were not initially seen on the T2-weighted images (Fig 5),

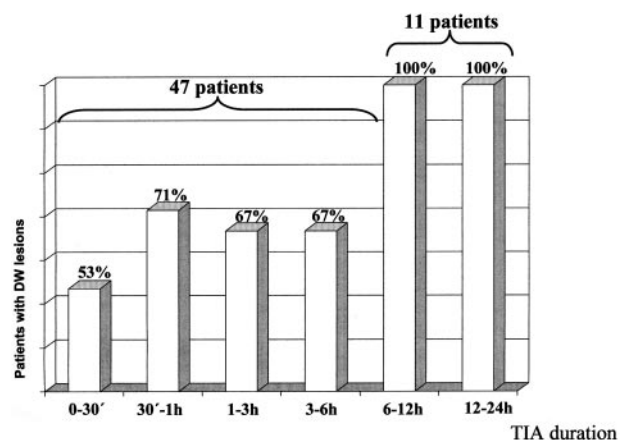


FIG 3. Plot of the relationship between TIA symptom duration and presence of TIA-related lesions on diffusion-weighted images.

A significant statistical correlation existed between symptom duration and presence of TIA-related lesions ($P = .025$); the significance was lost when only patients with symptoms lasting less than 6 hours were included in the analysis ($P = .513$).

FIG 4. Axial MR images obtained 4 hours after onset of symptoms in a 65-year-old woman with sudden-onset left-sided pure motor hemiparesis lasting 6 hours.

A and B, Fast-FLAIR (A) does not show the clinically appropriate small lesion in the right insular cortex, which is well visualized on a diffusion-weighted (B) image.

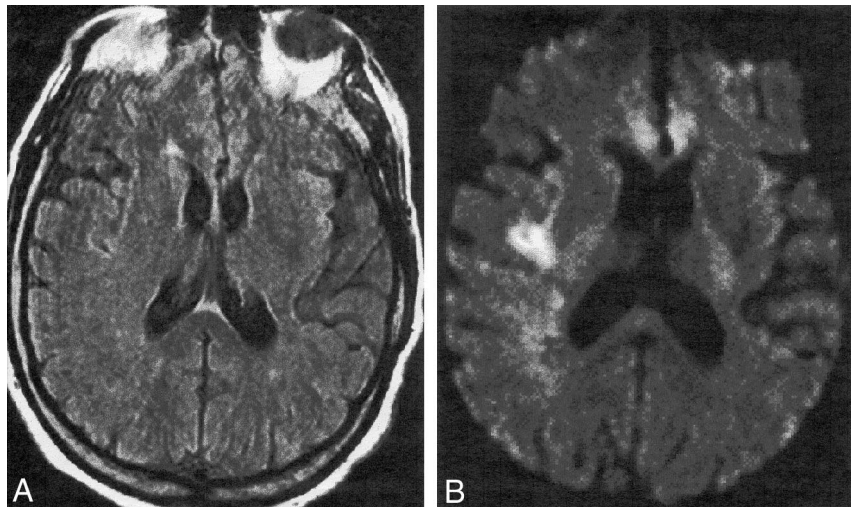
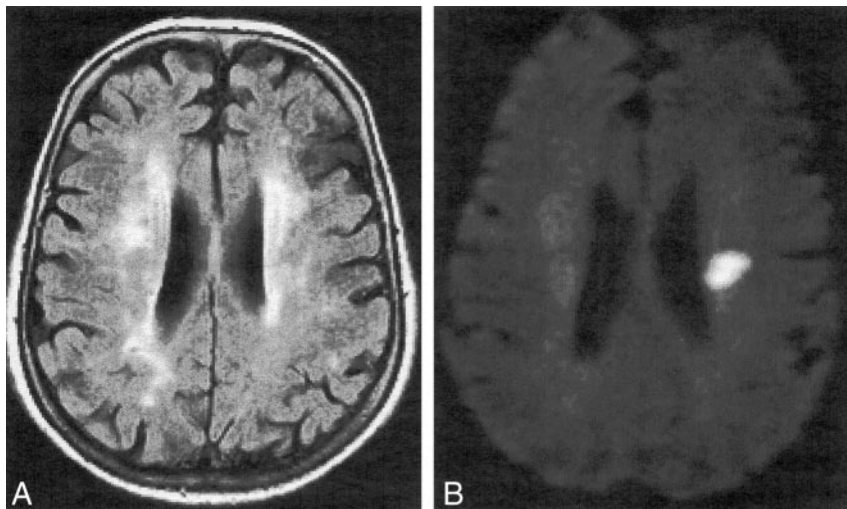


FIG 5. Axial MR images obtained in a 75-year-old man with transient left hemiparesis.

A, Fast-FLAIR T2-weighted MR image shows multiple focal lesions in the subcortical white matter. It is not possible to discern whether any of the lesions are acute.

B, Diffusion-weighted MR section obtained at the same level as A depicts a single focus of high signal intensity in the left centrum semiovale suggestive of acute infarction.



although they could be identified retrospectively. We attribute this to the small size of lesions, slight hyperintensity compared with surrounding brain tissue, to the presence of multiple, old infarcts, or ischemic white matter disease that masked the lesions. In 58% of patients, diffusion-weighted images did not add information to that obtained from conventional MR imaging; identification of the index and subsidiary infarcts was equally achieved with both techniques (Fig 2). In most of these patients, the TIA was their first ischemic event, and no MR imaging evidence of old ischemic lesions within the brain within the brain parenchyma existed.

The vascular territories affected were superficial, middle, or anterior cerebral arteries in 18 patients; deep middle cerebral arteries in 10; brain stem perforators in two; border zone areas in six; and posterior cerebral arteries in three.

In nine of the patients who manifested a positive index lesion, follow-up conventional MR imaging was performed 2 to 6 months after the clinical event. All of these nine patients manifested a subsequent infarct in the region corresponding to the original index lesion, which in most cases could only be recognized

by comparison with the initial diffusion-weighted images (Figs 6 and 7).

The index lesion ranged in size from 2 to 40 mm (mean, 15 mm) on diffusion-weighted images. When patients were grouped according to the duration of symptoms, no significant differences in the size of the index lesions were found among the groups ($P = .368$, ANOVA).

TIA cause in all patients was established according to TOAST classification (19). In seven patients, the cause was attributed to small-vessel disease; in 19, to large-vessel disease with significant stenosis; in three, to large-vessel disease without significant stenosis; in six, to cardioembolic disease; and in 16, to more than one or unknown cause. No significant correlation was observed between the cause of TIA and the presence of an index lesion (χ^2 test). Subsidiary infarcts were most commonly seen in patients with large-vessel disease with significant stenosis (74%), although no significant differences were observed when compared with other groups, because of their small number of patients (Fig 8).

Two patients with positive index lesions had multiple subsidiary lesions distributed in different vascular

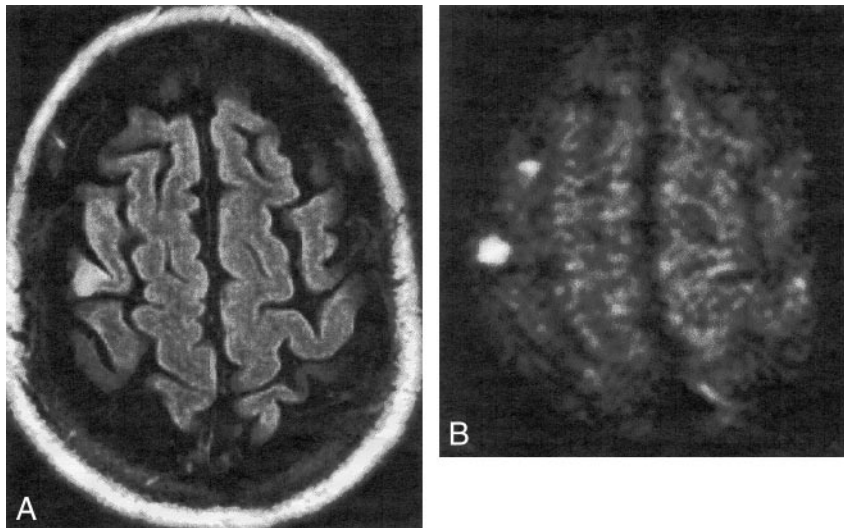


FIG 6. Axial MR images obtained 3 days after symptom onset in a 75-year-old man with left hemiparesis that rapidly resolved within 4 hours of onset.

A and B, Small cortical ischemic lesions in the right middle frontal gyrus are better visualized on a diffusion-weighted image than on a T2-weighted image.

C, A subsequent infarct was overlooked on this follow-up T2-weighted MR image obtained 4 months after A and B.

D, A follow-up fast-FLAIR MR image obtained at the same time as C helps identify a small lesion at the same location as the prior ischemic lesions, indicating a chronic infarct.

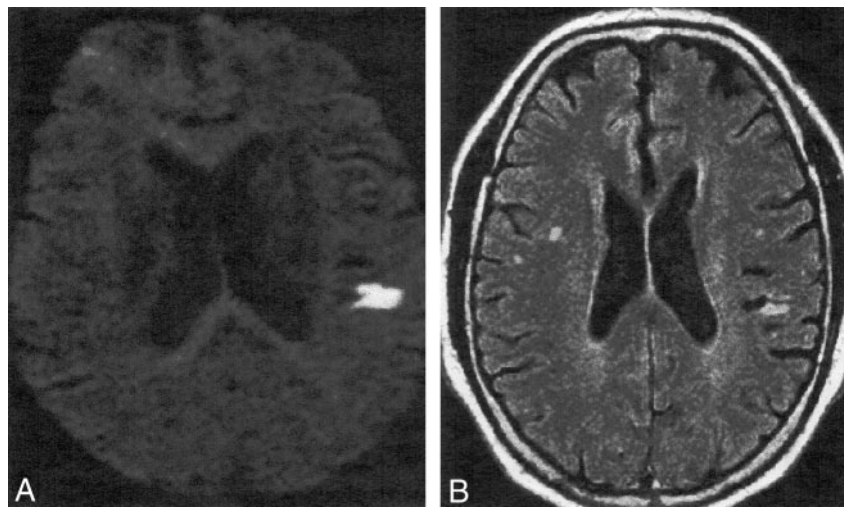
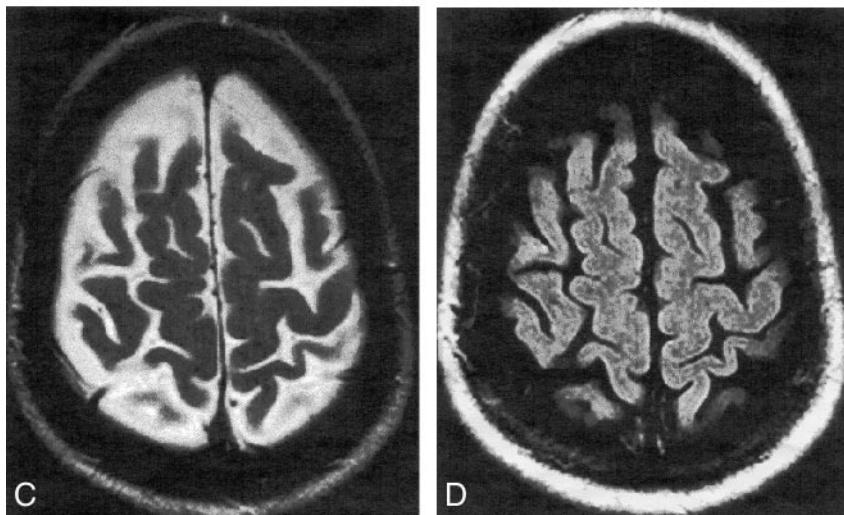


FIG 7. Axial MR images obtained in a 65-year-old man with aphasia that rapidly resolved within 3 hours of onset.

A, A diffusion-weighted image obtained 2 days after symptom onset clearly depicts a small, acute cortical ischemic lesion in the opercula of the left frontal lobe.

B, A follow-up fast-FLAIR MR image obtained 3 months later shows a small cortical lesion with high signal intensity at the same location as the lesion in A, indicating a chronic infarct. This subsequent infarct might have been overlooked had the reader not been aware of the location of the lesion on the initial diffusion-weighted image.

territories, which could not be explained by the presence of arterial anatomic variations. The TIA cause was considered to be atherothrombotic in these two cases because of the presence of large-vessel disease with significant stenosis at the level of several cervical arteries and the exclusion of embolism of cardiac origin.

Discussion

Neuroradiologic investigations with CT and conventional MR imaging have shown that a substantial proportion of patients with TIAs have ischemia-related lesions of the brain parenchyma (5, 7, 9, 10).

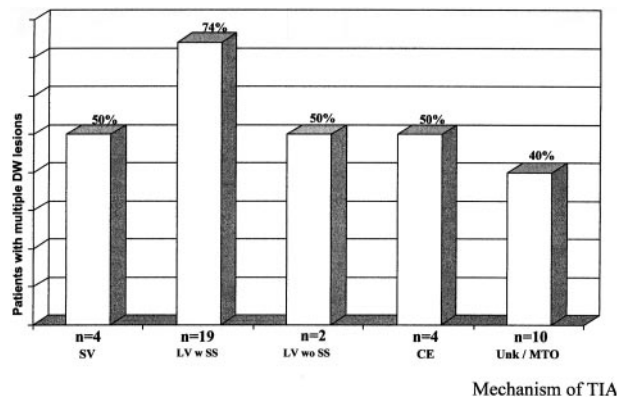


FIG 8. Plot of the relationship between TIA cause and the presence of multiple TIA-related lesions on diffusion-weighted images. Although the small number of patients in some groups impeded correlation analysis, patients with large-vessel disease and significant stenosis showed more multiple lesions.

Note.—SV indicates small-vessel disease; LV w SS, large-vessel disease with significant stenosis; LV wo SS, large-vessel disease without significant stenosis; CE, cardioembolism; and Unk/MTO, unknown or more than one mechanism.

These studies, however, have been handicapped by their low sensitivity in detecting acute and small infarctions and differentiating acute lesions from prior unrelated ischemic events (5, 7–10, 20, 21). Thus, the identification of a particular brain lesion attributable to the actual ischemic event remains difficult with these imaging techniques.

Diffusion-weighted MR imaging has high sensitivity and specificity for early detection of ischemic lesions (22–24). It also provides temporal information, because acute lesions are bright compared with normal brain tissue or old ischemic events in isotropic diffusion-weighted images. This excellent background suppression permits the detection of even very small, acute infarction at almost any anatomic location within the brain hemispheres, brain stem, and cerebellum. Previous reports have shown that the addition of diffusion-weighted imaging to the conventional MR examination in patients with small-vessel infarctions substantially increases the detection of clinically relevant infarcts (11, 13–15). Our prospective analysis of diffusion-weighted MR imaging in patients with TIAs helped detect acute ischemic lesions in approximately two thirds of cases (67%). This incidence is higher than that reported for CT and conventional MR imaging studies, which ranged from 12–48% (5, 10) and is also slightly higher than that recently reported for previous diffusion-weighted MR imaging investigations, which ranged from 35–48%. This higher incidence may have occurred, because we only included patients who were attended by a neurologist in the emergency department. Thus, a bias toward patients with symptoms that were more severe and of a longer duration may have existed.

TIAs can result from intermittent embolic occlusion of a main arterial branch followed by recanalization and upstream transportation of the remaining particles toward the distal branches, which can give rise to cortical and multiple infarcts (Fig 1). This con-

curs with the high frequency of multiple acute ischemic lesions that we found in patients in whom index lesions were located within the hemispheric cortex (16 of 21), whereas index subcortical lesions located were more commonly isolated (11 of 18). Although the presence of subsidiary lesions was more frequent among patients in whom TIA was caused by large-vessel stenosis, the small number of patients included in each pathogenetic category precluded the establishment of statistically significant correlation between presence of more than one lesion and TIA cause.

Previous reports (10, 25–27) evaluating the relationship between the duration of TIA symptoms and the subsequent development of an infarct, as visualized on CT or conventional MR images, have yielded conflicting results, although it seems that longer events are more likely to produce symptom-related infarcts. This type of correlation should be interpreted cautiously, as TIA duration is determined by the patient's estimate and is not a precisely measured period. In our group of patients, we found a significant correlation between duration of TIA symptoms and presence of an index lesion on diffusion-weighted images. Moreover, all patients who had symptoms for more than 6 hours showed an index lesion on diffusion-weighted images, an incidence that lowered to 59% in patients with symptoms for less than 6 hours. However, when we included only patients with symptoms that lasted less than 6 hours in the analysis, no significant correlation existed between the presence of an index lesion and estimated duration of symptoms. These data seem to establish a clear cut-off time of 6 hours between TIA patients who always show a TIA-related infarct on diffusion-weighted images and those who show infarcts only in two thirds of cases. On the basis of these data, we suggest that TIAs of more than 6 hours' duration correspond to a subgroup of patients who manifest an MR imaging pattern similar to that seen in patients with established stroke.

The subset of patients with TIA-related lesions on initial diffusion-weighted images exhibited late evidence of established infarction, at least within the index lesion, on follow-up MR images. This contradicts findings of a previous investigation (16) that did not show post-TIA infarcts in approximately half of the patients studied, suggesting that lesions revealed on initial diffusion-weighted images may be fully reversible.

This discrepancy with our study may be explained by two factors. First, the readers in our work were not blinded to the baseline diffusion-weighted imaging findings, which helped them to know the precise location in which a subsequent infarction might be expected. Second, the use of fast-FLAIR in addition to fast spin-echo sequences as the standard for T2-weighted imaging might have improved our capacity to detect subsequent infarcts, because this technique seems to increase the sensitivity in detecting small chronic ischemic lesions within or close to the cortex (28). This point is particularly relevant in TIA-related

lesions, which are usually small, located within or close to the cortex, and decreased in size as the lesion becomes chronic, which may render them undetectable at MR imaging follow-up. Although our experience indicates that acute TIA-related lesions on diffusion-weighted images correspond to irreversible ischemic tissue, the strength of our observation is limited in that we were not able to perform follow-up MR imaging in most of our patients. Moreover, we did not perform follow-up studies in the patients in whom diffusion-weighted imaging did not reveal acute TIA-related lesions; thus, we do not know whether a relevant infarct would be visible on subsequent images.

The use of diffusion-weighted MR imaging in the acute phase of TIA appears to be clinically useful and does not significantly increase the total examination time. It is more sensitive than is conventional MR imaging in detecting TIA-related lesions and confirms their ischemic origin in most cases. Diffusion-weighted MR imaging also defines the size, number, and location of the lesion(s) as well as the vascular territory involved, all of which may be useful in determining TIA cause, guiding therapy, and initiating long-term secondary stroke preventative therapy differentiated by stroke subtype (29). Moreover, the identification of which patients have a new infarct on images may have important prognostic value (5). However, further studies are required to establish the clinical prognostic significance of TIA-related diffusion-weighted imaging abnormalities.

Acknowledgment

We thank Celine Cavallo for English-language assistance.

References

1. The Ad Hoc Committee on the Classification and Outline of Cerebrovascular Disease, II. *Stroke* 1975;6:566-616
2. Dyken MI, Conneally M, Haerer AF, et al. Cooperative study of hospital frequency and character of transient ischemic attacks, I: background, organization and clinical surgery. *JAMA* 1977;237:882-886
3. Dennis M, Bamford J, Sandercock P, Warlow C. Prognosis of transient ischemic attacks in the Oxfordshire Community Stroke Project. *Stroke* 1990;21:848-853
4. Streiffler JY, Benavente OR, Harbison JW, Eliasziw M, Hachinski VC, Barnett HJM. Prognostic implications of retinal versus hemispheric TIA in patients with high grade carotid stenosis: observations from NASCET (abstract). *Stroke* 1992;23:159
5. Toole JF. The Willis lecture: transient ischemic attacks, scientific method, and new realities. *Stroke* 1983;14:433-437
6. Culebras A, Kase CS, Masdeu JC, et al. Practice guidelines for the use of imaging in transient ischemic attacks and acute stroke: a report of the stroke council, American Heart Association. *Stroke* 1997;28:1480-1497
7. Bogousslavsky J, Hachinski VC, Boughner DR, Fox AJ, Viñuela F, Barnett HJM. Clinical predictors and arterial lesions in carotid transient ischemic attacks. *Arch Neurol* 1986;43:229-233
8. Shuaib A, Hachinski VC, Oczkowski WJ. Transient ischemic attacks and normal cerebral angiograms: a follow-up study. *Stroke* 1988;19:1223-1228
9. Koudstaal PJ van Gijn J, Lodder J, et al for the Dutch Transient Ischemic Attack Study Group. Transient ischemic attacks with and without relevant infarct on computed tomographic scans cannot be distinguished clinically. *Arch Neurol* 1991;48:916-920
10. Fazekas F, Fazekas G, Schmidt R, Kapeller P, Offenbacher H. Magnetic resonance imaging correlates of transient ischemic attacks. *Stroke* 1996;27:607-611
11. Singer MB, Chong J, Lu D, Schonewille WJ, Tuhim S, Atlas SW. Diffusion-weighted MR in acute subcortical infarction. *Stroke* 1998;29:133-136
12. Wardlaw JM, Marshall Y, Dennis MS, Cannon J, Armitage P, Counsell C. Diffusion-weighted MRI is useful for demonstrating small infarcts not visible by other means (abstract). *Cerebrovasc Dis* 1997;7(Suppl 4):S35
13. Schonewille WJ, Tuhim S, Singer MB, Atlas SW. Diffusion-weighted MRI in acute lacunar syndromes: a clinical-radiological correlation study. *Stroke* 1999;30:2066-2069
14. Oliveira-Filho J, Ay H, Schaefer PW, et al. Diffusion-weighted magnetic resonance imaging identifies the "clinically relevant" small-penetrator infarcts. *Arch Neurol* 2000;57:1009-1014
15. Rovira A, Pedraza S, Capellades J, et al. Diffusion-weighted magnetic resonance in the diagnosis of acute subcortical infarcts. *Rev Neurol* 2000;30:914-919
16. Kidwell CS, Alger JR, Di Salle F, et al. Diffusion MRI in patients with transient ischemic attacks. *Stroke* 1999;30:1174-1180
17. Engelter ST, Provenzale JM, Petrella JR, Alberts MJ. Diffusion MR imaging and transient ischemic attacks. *Stroke* 1999;30:2762-2763
18. Ay H, Buonanno FS, Schaefer PW, et al. Clinical and diffusion-weighted imaging characteristics of an identifiable subset of TIA patients with acute infarction (abstract). *Stroke* 1999;30:235
19. Adams HP, Bendixen BH, Kappelle LJ, et al and TOAST investigators. Classification of subtype of acute ischemic stroke: definition for use in a multicenter clinical trial. *Stroke* 1993;24:35-41
20. Awad IA, Modic M, Little JR, Furlan AJ, Weinstein M. Focal parenchymal lesions in transient ischemic attacks: correlation of computed tomography and magnetic resonance imaging. *Stroke* 1986;17:399-403
21. Murros KE, Evans GW, Toole JF, Howard G, Rose LA. Cerebral infarction in patients with transient ischemic attacks. *J Neurol* 1989;236:182-184
22. Moseley ME, Kucharczyk J, Minorovitch J, et al. Diffusion-weighted MR imaging of acute stroke: correlation with T2-weighted and magnetic susceptibility-enhanced MR imaging in cats. *AJNR Am J Neuroradiol* 1990;11:423-429
23. Lövlund KO, Laubach HJ, Baird AE, et al. Clinical experience with diffusion-weighted MR in patients with acute stroke. *AJNR Am J Neuroradiol* 1998;19:1061-1066
24. Gonzalez RG, Schaefer PW, Buonanno FS, et al. Diffusion-weighted MR imaging: diagnostic accuracy in patients imaged within 6 hours of stroke symptom onset. *Radiology* 1999;210:155-162
25. Koudstaal PJ, van Gijn J, Frenken CW, et al. TIA, RIND, minor stroke: a continuum, or different subgroups? Dutch Transient Ischemic Attack Study Group. *J Neurol Neurosurg Psychiatry* 1992;55:95-97
26. Bogousslavsky J, Regli F. Cerebral infarct in apparent transient ischemic attack. *Neurology* 1985;35:1501-1503
27. Davalos A, Matias-Guiu J, Torrent O, et al. Computed tomography in reversible ischaemic attacks: clinical and prognostic correlations in a prospective study. *J Neurol* 1988;234:155-158
28. De Coene B, Hajnal JV, Gatehouse P, et al. MR of the brain using fluid-attenuated inversion recovery (FLAIR) pulse sequences. *AJNR Am J Neuroradiol* 1992;13:1555-1564
29. Lee LJ, Kidwell CS, Alger J, Starkman S, Saver JL. Impact on stroke subtype diagnosis of early diffusion-weighted magnetic resonance imaging and magnetic resonance angiography. *Stroke* 2000;31:1081-1089