

The **next generation** GBCA
from Guerbet is here

Explore new possibilities >

Guerbet | 

© Guerbet 2024 GUOB220151-A

AJNR

Angioplasty and Stent Placement in Intracranial Atherosclerotic Stenoses and Dissections

Pedro Lylyk, José E. Cohen, Rosana Ceratto, Angel Ferrario
and Carlos Miranda

This information is current as
of March 20, 2024.

AJNR Am J Neuroradiol 2002, 23 (3) 430-436
<http://www.ajnr.org/content/23/3/430>

Angioplasty and Stent Placement in Intracranial Atherosclerotic Stenoses and Dissections

Pedro Lylyk, José E. Cohen, Rosana Ceratto, Angel Ferrario, and Carlos Miranda

BACKGROUND AND PURPOSE: Stent placement has been shown to increase the safety and effectiveness of balloon angioplasty in cervical carotid disease. Here, the authors investigated the feasibility, safety, and short-term outcome of stent-assisted angioplasty for the treatment of intracranial stenoses.

METHODS: Thirty-four patients (age range, 12–77 years; mean age, 54 years) with symptomatic intracranial atherosclerotic lesions and dissections that produced stenosis of more than 50% were selected and treated with stents. Eighteen lesions (53%) were located in the anterior circulation, and 16 (47%) were in the vertebrobasilar complex. The mean stenosis was 75%.

RESULTS: At follow up, 21 patients (62%) improved clinically, 11 (32%) remained stable, and the condition of two patients (6%) deteriorated. In all patients, the angiographic degree of stenosis was reduced to less than 30%. In 10 patients (29%), two or more stents were implanted: Two stents were implanted in six patients, and three, in four patients. The transient procedural morbidity rate was 12%, and the transient neurologic morbidity rate was 6%. One patient had hemorrhagic transformation due to reperfusion and died, and another patient had a massive myocardial infarction after 5 months. Twenty patients were followed up with angiography for at least 6 months, and none required repeat angioplasty.

CONCLUSION: Endovascular revascularization of intracranial arteries by means of stent-assisted angioplasty is technically feasible, effective, and safe in selected patients.

Little is known about the natural history of stenosis caused by intracranial atherosclerosis. However, as many as 6–29% of all ischemic strokes are related to stenotic lesions located in intracranial large vessels, and an increased risk for stroke, heart disease, and death has been consistently observed (1–6).

Traditionally, aggressive anticoagulation has been used, but it has notable morbidity and death rates, which prompt a search for additional treatment strategies (7). The benefits of revascularization of stenotic segments in preventing stroke have been unequivocally demonstrated in patients with cervical carotid artery disease (8–10). However, the treatment of patients with intracranial atherosclerosis lesions still is controversial. The results of endovascular revascularization of intracranial vessels with balloon angioplasty have been tempered by the increased risk of stroke, which results from distal embolization, vessel dissec-

tion, and acute vessel occlusion secondary to dissection or platelet aggregation (11, 12). Stent use has been shown to increase the safety and effectiveness of balloon angioplasty in cervical carotid disease (3, 14). Recently, the advent of a new generation of more flexible stents has prompted consideration of stent-assisted angioplasty as an alternative approach in intracranial stenoses (15–19).

The purpose of this study was to investigate the effectiveness, safety, and short-term outcome of stent placement for the treatment of symptomatic intracranial artery disease.

Methods

From June 1996 through November 2000, 36 consecutive patients with symptomatic intracranial atherosclerotic stenotic lesions and dissections that produced significant stenosis were selected for PTA and stent placement as a part of a feasibility protocol approved by our institutional review board. Significant stenosis was defined as 50–99% stenosis, as depicted on angiograms, according to North American Symptomatic Carotid Endarterectomy Trial (NASCET) criteria (8). Inclusion criteria for this study included failure of antithrombotic therapy ($n = 32$)—defined as the occurrence of ischemic events (one or more transient ischemic attacks [TIAs] and/or strokes) while they were using therapeutic doses of aspirin (>81 mg/d), warfarin (international normalized ratio > 2.0), ticlopidine (500 mg/d), clopidogrel (75 mg/d), or heparin (prolongation of partial thromboplastin time of >1.5 times the baseline value)—

Received April 20, 2001; accepted after revision September 19.

From the Department of Neurosurgery and Interventional Neuroradiology, Eneer, Clinica Medica Belgrano, Buenos Aires, Argentina.

Presented in part at the 21th International Congress of Radiology, Buenos Aires, Argentina 2000, and the AANS-CNS Joint Meeting, Hawaii, 2001.

Address reprint requests to Pedro Lylyk, MD, Sanchez de Bustamante 2184, PB Dpto B (1425), Buenos Aires, Argentina.

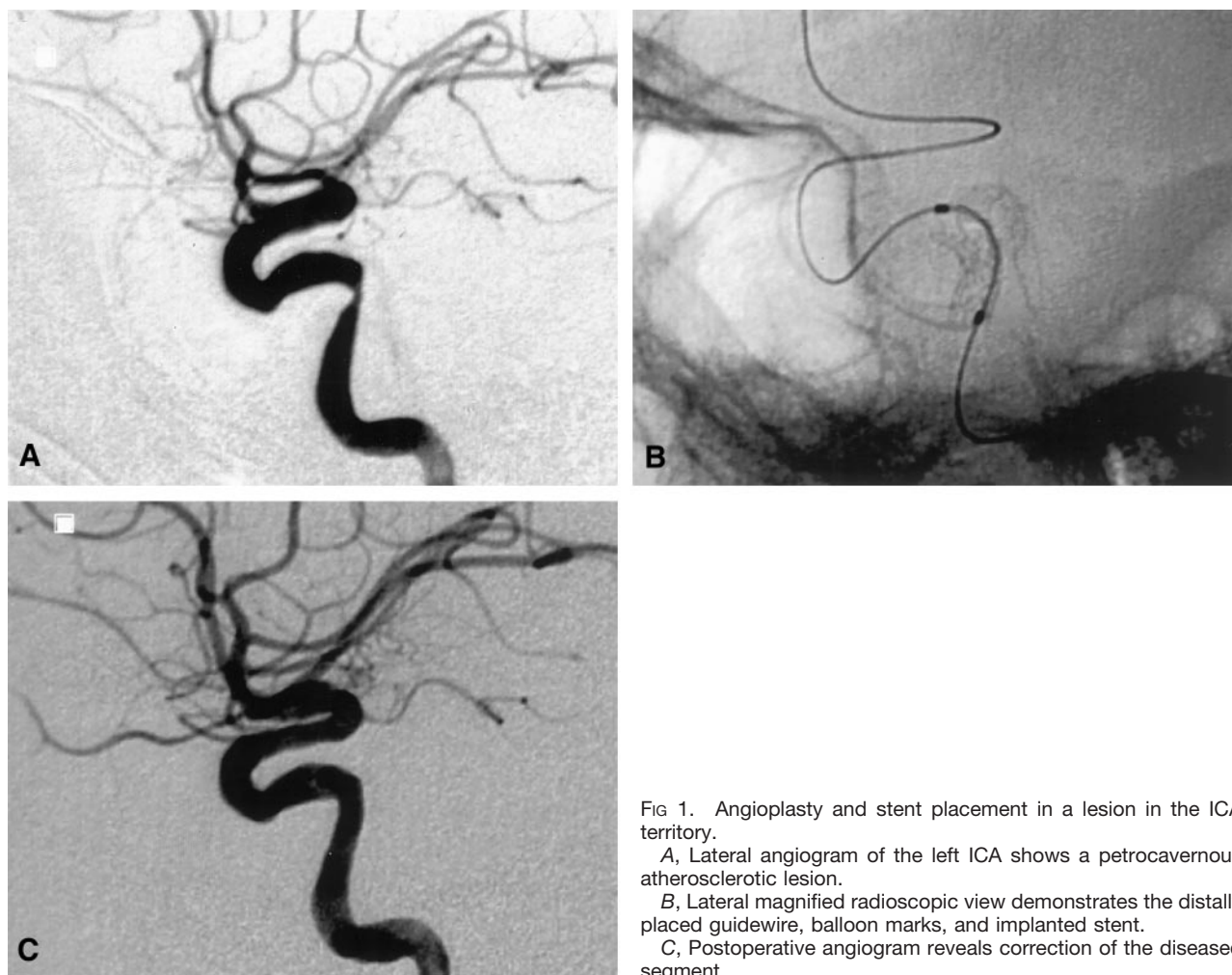


FIG 1. Angioplasty and stent placement in a lesion in the ICA territory.

A, Lateral angiogram of the left ICA shows a petrocavernous atherosclerotic lesion.

B, Lateral magnified radioscopic view demonstrates the distally placed guidewire, balloon marks, and implanted stent.

C, Postoperative angiogram reveals correction of the diseased segment.

and a contraindication to antithrombotic therapy ($n = 4$). In two patients, the selected stent was not able to reach the target because of extreme tortuosity; these patients were excluded from further analysis. The patient population was composed of 29 male and five female subjects (age range, 12–77 years; mean age, 54 years).

All patients had a stenotic lesion that was considered to be directly responsible for the symptoms, and they were selected for stent-assisted angioplasty on the basis of a number of factors, including the following: failure or contraindication for medical therapy; nonfeasibility, failure, or contraindication to surgery; poor neurologic grade; and poor medical status. Eighteen (53%) of the lesions were located in the internal carotid artery (ICA) territory (Fig 1), and 16 (47%) were in the vertebrobasilar complex (Figs 2 and 3). The most common location was the distal vertebral artery (VA) ($n = 11$ [32%]) followed by the petrocavernous ICA ($n = 10$ [29%]), vertebrobasilar junction ($n = 3$ [9%]), basilar artery ($n = 2$ [6%]), supraclinoid ICA ($n = 5$ [15%]), ICA M1 segment ($n = 2$ [6%]), and M3 segment ($n = 1$ [3%]).

All the patients underwent preoperative CT or MR imaging or both and cerebral digital subtraction angiography (DSA). Preprocedural quantitative angiographic measurements (Integrus; Phillips Medical System), were obtained in the target vessel and lesion. The degree of stenosis was calculated according to the NASCET criteria for grading carotid stenosis. The measurements were calibrated by using the guiding catheter as a reference. Atherosclerotic lesions were classified, according to the method of Mori et al (20), into three groups on the basis of lesion morphology. Type A lesions were 5 mm or shorter,

concentric or moderately eccentric, and not totally occlusive. Type B lesions were 5–10 mm in length, extremely eccentric or totally occlusive, and younger than 3 months, and type C lesions were longer than 10 mm, angulated more than 90° , excessively tortuous or totally occluded, and older than 3 months.

Patients received aspirin and ticlopidine (Ticlid; Roche) or clopidogrel (Plavix; Sanofi), 72 hours before the procedure. Combined therapy was continued for 6 months, and aspirin was continued indefinitely. In this series, clinical follow-up was performed at 1, 3, 6, and 12 months. Angiographic follow-up was conducted at 3 and 6 months. No patient was lost to follow-up monitoring.

Evaluation of the Procedure

The primary objective was reduction in degree of stenosis to less than 50% without worsening of the neurologic status. Accordingly, we defined grade I as a reduction in the degree of stenosis to less than 50%, and grade II was any reduction a stenosis of less than 50%.

Postprocedural Clinical Evaluation

To assess the postoperative neurologic status, we defined a five-grade scale as follows: I, neurologic improvement (no recurrent TIAs or ischemic symptoms); II, no changes and no neurologic complications; III, transient neurologic complications; IV, neurologic deterioration and permanent neurologic complication; and V, death associated with the procedure.

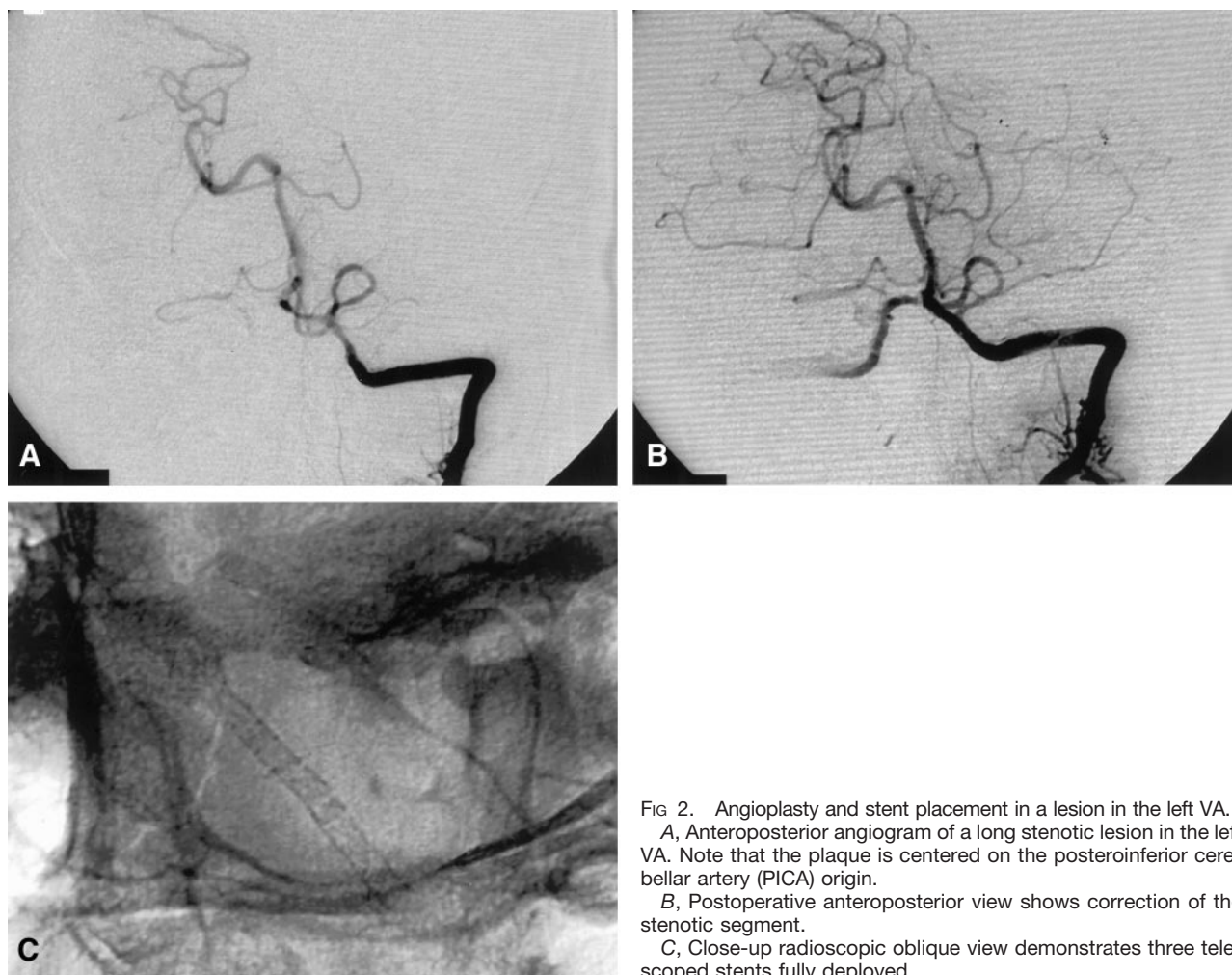


FIG 2. Angioplasty and stent placement in a lesion in the left VA.

A, Anteroposterior angiogram of a long stenotic lesion in the left VA. Note that the plaque is centered on the posteroinferior cerebellar artery (PICA) origin.

B, Postoperative anteroposterior view shows correction of the stenotic segment.

C, Close-up radioscopic oblique view demonstrates three telescoped stents fully deployed.

General Surgical Technique

Every patient was taken to the endovascular suite for subsequent cerebral angiography and endovascular treatment. General anesthesia was routinely indicated. Brainstem-evoked potentials, cerebral oxygen saturation, and invasive arterial pressure were appropriately monitored. A unilateral intraarterial approach was used after a standard Seldinger puncture and catheterization, and an 8F introducer sheath was placed in the right femoral artery with full heparin therapy. Our protocol consisted of the administration of a 10,000 IU bolus dose just before starting the therapeutic procedure, and a maintenance booster of 1500 IU was administered every hour to provide an activated clotting time of longer 250 seconds before stent placement. Abciximab (Reo-pro) was infused intraprocedurally. Patients received uncoated aspirin (500 mg by mouth once a day) and ticlopidine (250 mg by mouth twice a day) for days before stent placement, and both medications were continued for at least 90 days.

Selective DSA was performed, and the target lesion was routinely outlined and measured in multiple projections with rotational D angiography. A 6F Envoy guiding catheter (Cordis, Miami, FL), 6F coaxial catheter attached to an 8F Envoy catheter, was then advanced into the target vessel by using a standard 0.035- or 0.038-inch guidewire. Occasionally, predilation with a balloon may have been required, especially when proximal or distally located atherosclerotic plaques prevent advancement of the stent. In general, dilation was performed by using a balloon diameter–vessel diameter ratio of 1:1. We then advanced a microcatheter—Excel (Boston Scientific), Prowler (Cordis Endovascular Systems), or Rapid transit (Cor-

dis Endovascular Systems)—over a tapered 0.014-inch-diameter 150-cm-long guide wire (Transend-14; Scimed Life Sciences, Maple Grove, MN) and performed microcatheter exchange with the magnetic device (The Magnet, Scimed Life Sciences) for the balloon-premounted stent delivery system (four cases). Alternatively, the microguidewire was replaced by a 0.014-inch-diameter 300-cm-long exchange microguidewire (Choice, Scimed Life Sciences), and the microcatheter was subsequently withdrawn. Adequate support was needed to guide the stent device over the microguidewire, and this was achieved by navigating the wire across the target as far as M2-M3 or P2-P3 segments.

Stent Selection and Description

Careful sizing of stents is very important. In general, the stent size should match the diameter of the reference vessel and correspond with the length of the lesion. In the first cases, we used devices currently used in interventional cardiology, such as the Velocity stent and the AVE gxf steel stent (Arterial Vascular Engineering, Santa Rosa, CA), which is made of stainless steel. More recently, a new generation of stents has been introduced into clinical practice. These stents, such as the AVE inx (Medtronic), are metallic radiopaque stents with a more flexible design and delivery-deployment catheter. The AVE inx stent was positioned across the lesion with enough overlap on each side of the target to properly anchor the device. The device was then deployed by inflating the balloon delivery system for 15–30 seconds at 6 atm of pressure.

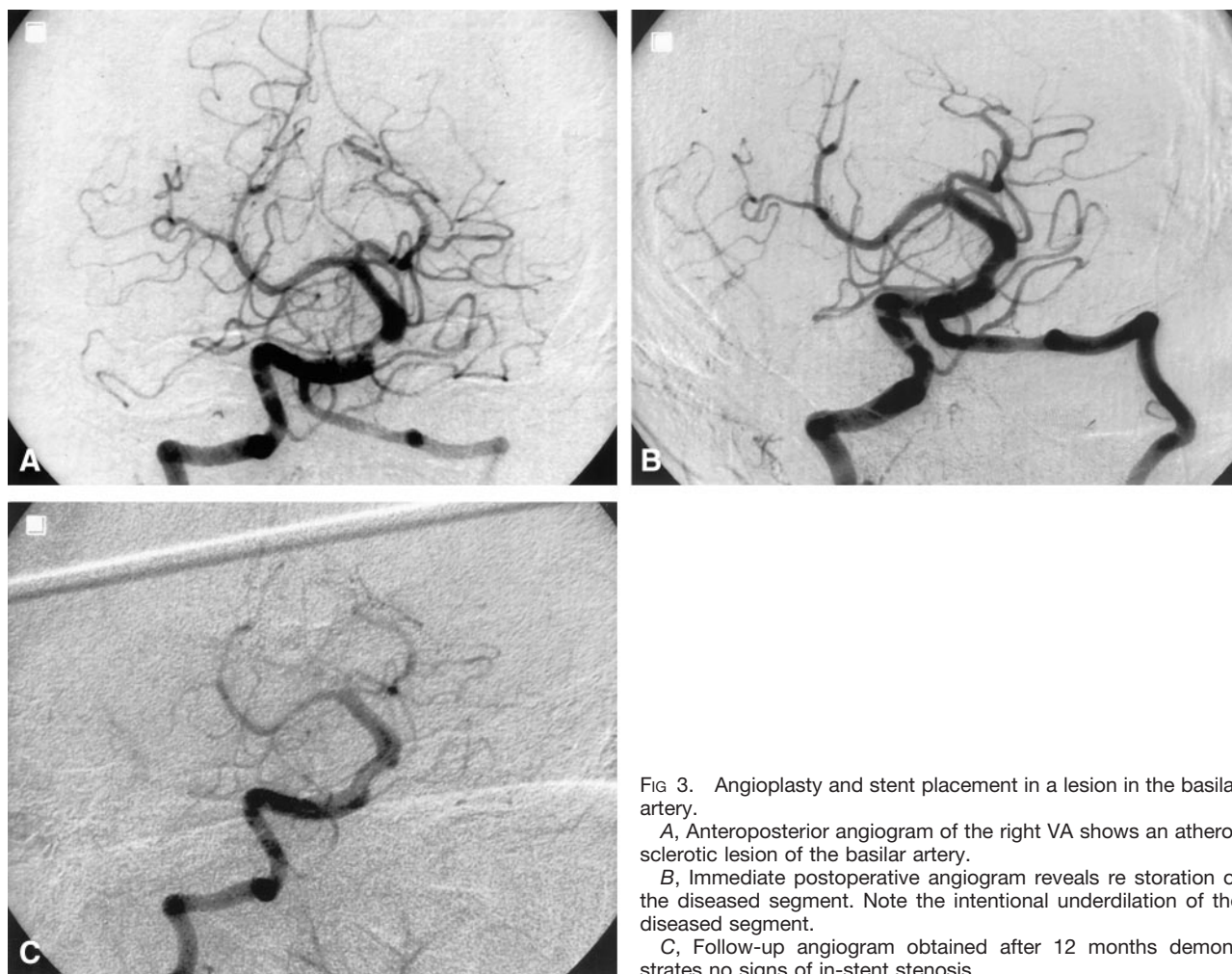


FIG 3. Angioplasty and stent placement in a lesion in the basilar artery.

A, Anteroposterior angiogram of the right VA shows an atherosclerotic lesion of the basilar artery.

B, Immediate postoperative angiogram reveals restoration of the diseased segment. Note the intentional underdilation of the diseased segment.

C, Follow-up angiogram obtained after 12 months demonstrates no signs of in-stent stenosis.

Results

The overall success in reaching the target lesion with stents was 94% (of 36 targets), and two procedures were aborted because of an inability to manipulate the device in tortuous anatomy. In 10 instances (2%), complete coverage of the lesion required the implantation of a second (six cases) or even a third (four cases) abutted stent. The rest of the targets were treated with one stent each (24 cases [71%]). A total of 48 stents were implanted (mean, 1.41 stents per lesion): The AVE inx was implanted in 7% ($n = 34$), followed by AVE gxf ($n = 8$ [17%]), Velocity ($n = 3$ [6%]), and others ($n = 3$ [6%]). Twenty-four patients (71%) received AVE inx stents; four (12%), AVE gxf stents; and six (18%), a combination of stents. Mean lesion length 12.7 mm (range, 3–27 mm). Six lesions (20%) were classified as type A; 16 (53%), as type B; and eight (27%), as type C. Preprocedural stenosis varied from 55% to 95% (mean, 75%), and postoperative residual stenosis varied from 0% to 30% (mean, 18%).

Twenty-one patients had symptomatic relief (clinical grade I, 62%), nine remained neurologically stable (clinical grade II, 26%), two remained stable but had transient neurologic complications (clinical grade III, 6%) and two patients died (clinical grade V, 6%).

Technical Limitations and Procedural Complications

Inability to Reach the Target.—In two patients, we were not able to reach the target with the stent. Both targets were located on the ICA at the cervical segment or the anterior bend of the cavernous segment. This subgroup had no procedure-related morbidity.

Unintended Stent Dislodgement.—Neuronavigation through tortuous vessels induced friction with the ascending mounted stent. With closed angles, tracking friction may have induced stent dislodgement from the delivery catheter. Permanent fluoroscopic control of the ascending mounted stent was essential to detect undesired displacements. Two stents (one AVE gxf and one AVE inx) were unintentionally dislodged from the balloon before the target was reached; one was recovered with a snare. However, one stent was not recovered; it was partially expanded at a proximal site, with no clinical complications.

Stent Displacement.—Upon balloon inflation, we observed that balloon-mounted stents tended to advance from the selected position because of flow propulsion, but they could be repositioned easily. A loosely positioned stent may have been displaced backward when we attempted to remove a balloon.

from the stent lumen after deflating it. The use of a stent with an inadequate diameter or underexpansion of the stent for fear of rupture may have accounted for this event. This occurred in three cases; one required the implantation of a telescoped proximal stent. Three patients had sudden hypertension related to balloon inflation, and one had associated bradycardia. Two embolic events were successfully treated with selective urokinase infusion. No acute or subacute stent thrombosis, wire perforations, or arterial ruptures occurred. The procedural morbidity rate was 12%.

Postoperative Morbidity and Follow-up

At immediate postoperative follow-up, two patients had a TIA, and one had a myocardial infarction. One patient with bilateral severe stenoses of the supraclinoid and proximal M1 segments was successfully treated, and adequate revascularization of the left ICA and M1 was achieved. However, the patient had a postoperative cerebral hematoma related to the reperfusion of a chronically ischemic non autoregulating parenchyma. The patient underwent surgery but had a contralateral infarction and died. Postmortem pathologic examination of the stented artery revealed amyloid angiopathy.

Twenty patients were followed up clinically and angiographically for at least 6 months. This subset of patients remained clinically and angiographically stable, and repeat angioplasty was not required in any of the cases. One patient with type C vertebrobasilar atherosclerotic stenosis died from a myocardial infarction 5 months after the procedure.

The clinical follow-up period varied from 1 to 42 months (mean, 5 month). Good short-term clinical outcomes were achieved in 32 patients (94%). Angiographic follow-up varied from 1 to 24 months (mean, 4 months). No evidence of angiographic in-stent de novo stenosis or restenosis was recognized in seven cases that were followed up clinically and angiographically for at least 12 months. Two patients had incidental focal arterial dissection at the target parent vessel. Both were successfully treated with anticoagulation. The global morbidity rate was 18% (six of 32), the neurologic morbidity rate was 6% (two of 32), and the mortality rate was 6% (two of 34).

Discussion

Indications for any therapy depend on both the risks of the untreated disease and the safety and effectiveness of the therapeutic procedure. The natural history of intracranial stenoses has not been studied as well as that of extracranial stenoses, but they consistently have a high rate for stroke. Patients with intracranial ICA stenoses who were followed up for an average of 3.9 years had a TIA or stroke rate of 27.3%, (3, 4, 6). Stenoses of the MCA occur at a rate of at least 8% per year (21–22). Posterior fossa lesions managed with either warfarin or aspirin therapy for a

mean of 13.8 months have a stroke rate of 8–40%, depending on the site of the lesion (7, 23, 24).

Advantages of stent-assisted angioplasty include exclusion of the plaque and regions of dissection from the vessel lumen, as well as prevention of vessel recoil and rupture. In the intracranial circulation, the application of stents has been limited largely because of the inability to manipulate existing stents in the cranial vessels. However, the availability of recently introduced flexible stents, the development of potent antiplatelet inhibitors, and the increasing evidence from experimental and clinical studies of intracranial stents have encouraged the use of stents in the management of ischemic and hemorrhagic intracranial cerebrovascular disease (15–19, 25–33).

We report findings in a series of 36 consecutive patients, focusing on the 34 whom we were able to treat with angioplasty and stent placement. In two cases, we were unable to place the stent in the desired location because of technical limitations. Both cases involved lesions in the supraclinoid carotid artery, and the limiting segment was the cervical segment or the anterior bend of the cavernous carotid artery. In two other patients, we prematurely dislodged the stent before reaching the target. Retrospective analysis of these four cases revealed that the radius of the curve of the major vascular loop (carotid siphon) proximal to the target lesion was smaller than that of patients in whom stents were successfully deployed. In no case were we unable to place the stent because of lesion complexity, but three cases (9%) required fibrinolysis and predilation with an angioplasty balloon before the stent could be placed.

In our series, the most common site for intracranial angioplasty was the distal vertebral artery (Fig 2). The issue that must be considered is whether a stenotic vertebral artery should be treated when the contralateral artery is normal and provides adequate supply to the basilar artery if the risk of thrombus formation and distal embolization is not eliminated. This pathogenic mechanism prevails in 25% of patients with vertebrobasilar insufficiency (34). When the stenotic artery ends in PICA, protection of this particular territory may also warrant intervention (35).

Compared with balloon angioplasty, stent placement produced a better angiographic result. In terms of the mean residual stenosis in intracranial vessel disease, stent placement seems to be a feasible, safe, and effective treatment. The mean postoperative residual stenosis was 18% after stent placement, whereas that of previously reported balloon angioplasty was 41–47% (11, 36); limitation of the plaque recoil phenomena account for this difference. Balloon overdilation is not an accepted practice in the intracranial circulation, and it may be especially dangerous in the basilar artery, where different authors advocate underdilation (to not more than half of the normal diameter) because of the insubstantial muscularis and adventitial layers of the artery wall and the subsequent elevated risk of perforation (37–38) (Fig 3). In a recent case (not included in this series), fatal arterial rupture occurred after stent deployment. This patient had a severe symptomatic

basilar lesion in the middle third of the basilar trunk. An acceptable angiographic result was initially achieved, with the restoration of the arterial diameter, to as much as to 50%, without complications. However, a better result was considered possible, and further balloon inflation provoked artery rupture. Vascular and neurologic complications related to intracranial angioplasty include vessel rupture, dissection, thrombosis, thromboembolism, and death.

Our neurologic morbidity rate of 12% and mortality rate of 6% compares favorably with those of other reports (11, 36, 39–43). Our treatment protocol included a high level of heparin with the concomitant use of platelet glycoprotein IIb/IIIa receptor inhibitor. Adequate anticoagulation is essential for the procedure, and we did not find consistent data to cause us to reduce its level. In this series, we found no hemorrhagic complications that were specifically attributed to this approach; this observation confirms previously published data (44).

Conclusion

Endovascular revascularization of intracranial vessels with angioplasty and stent placement is feasible, safe, and effective. Continued development of flexible balloon and stent systems—with a focus on tracking, flexibility, radiopacity, and thrombogenic properties—in essential to overcome technical limitations. The potential advantages of endovascular revascularization of the inaccessible intracranial vessels with angioplasty and stent placement are encouraging.

References

- Akins PT, Pilgram TK, Cross DT III, Moran C. Natural history of stenosis from intracranial atherosclerosis by serial angiography. *Stroke* 1998;29:433–438
- Sacco R, Zamanillo C, Kargman D, Shi T. Determinants of intracranial atherosclerotic stroke: The Northern Manhattan Stroke Study (abstract). *Stroke* 1994;25:259
- Marzewski DJ, Furlan AJ, St Louis P, et al. Intracranial internal carotid stenosis: long term prognosis. *Stroke* 1982;13:821–824
- Bogousslavsky J, Regli F. Prognosis of symptomatic intracranial obstruction of internal carotid artery. *Eur Neurol* 1983;22:351–358
- Wechsler LR, Kistler P, Davis KR et al. The prognosis of carotid siphon stenosis. *Stroke* 1986; 17:714–718
- Craig DR, Mageuro K, Watridge C, Robertson JT, Barnett HJM, Fox AJ. Intracranial internal carotid stenosis. *Stroke* 1982;13:825–828
- Chimowitz MI, Kokkinos J, Strong J, et al. The Warfarin–Aspirin Symptomatic Intracranial Disease Study. *Neurology* 1995;45:1488–1493
- North American Symptomatic Endarterectomy Trial (NASCET) Collaborators. Beneficial effect of carotid endarterectomy in symptomatic patients with high-grade stenosis. *N Engl J Med* 1991;325:445–453
- European Carotid Surgery Trialists Collaborative Group. MRC European Carotid Surgery Trial: interim results for asymptomatic patients with severe or with mid carotid stenosis. *Lancet* 1995;337:1235–1241
- Executive Committee for the Asymptomatic Carotid Atherosclerosis Study. Endarterectomy for asymptomatic carotid artery stenosis. *JAMA* 1995;18:1421–1428
- Clark WM, Barnwell SL, Nesbit G, O'Neill, OR, Wynn ML, Coull BM. Safety and efficacy of percutaneous transluminal angioplasty for intracranial atherosclerotic stenosis. *Stroke* 1995;26:1200–1204
- Takis C, Kwan ES, Pessin MS, Jacobs DH, Caplan LR. Intracranial angioplasty: experience and complications. *AJNR Am J Neuroradiol* 1997;18:1661–1668
- Roubin GS, Yadav S, Iyer SS, Vitek J. Carotid stent-supported angioplasty: a neurovascular intervention to prevent stroke. *Am J Cardiol* 1996; 78:8–12
- Yadav JS, Roubin GS, King P, Iyer S, Vitek J. Angioplasty and stenting for restenosis after carotid endarterectomy: initial experience. *Stroke* 1996; 27:2075–2079
- Al-Mubarak N, Gomez CR, Vitek JJ, Roubin GS. Stenting of symptomatic stenosis of the intracranial internal carotid artery. *AJNR Am J Neuroradiol* 1998; 19:1949–1951
- Dorros G, Cohn JM, Palmer LE. Stent deployment resolves a petrous carotid artery angioplasty dissection. *AJNR Am J Neuroradiol* 1998;19:392–394
- Feldman RL, Trig L, Gaudier J, Galat J. Use of a coronary Palmaz Schatz stent in the percutaneous treatment of a intracranial carotid artery stenosis. *Cathet Cardiovasc Diagn* 1996;38:316–319
- Gomez CR, Misra VK, Liu MW, et al. Elective stenting of symptomatic basilar artery stenosis. *Stroke* 2000;31:95–99
- Mori T, Kazita K, Mori K. Cerebral angioplasty and stenting for intracranial vertebral atherosclerotic stenosis. *AJNR Am J Neuroradiol* 1999;20:787–789
- Mori T, Fukuoka M, Kazita K, et al. Follow-up study after intracranial percutaneous transluminal cerebral balloon angioplasty. *AJNR Am J Neuroradiol* 1998;19:1525–1533
- Bogousslavsky J, Barnett HJM, Fox AJ, Hachinski V, Taylor W. Atherosclerotic disease of the middle cerebral artery. *Stroke* 1986; 17:1112–1120
- The EC/IC Bypass Study Group. Failure of extracranial-intracranial arterial bypass to reduce the risk of ischemic stroke: results of an international randomized trial. *N Engl J Med* 1985;3:1191–1200
- The Warfarin–Aspirin Symptomatic Intracranial Disease Study Group. Prognosis of patients with symptomatic vertebral or basilar artery stenosis (abstract). *Stroke* 1995;26:35
- Moufarrij NA, Little JR, Furlan AJ, Leatherman JR, Williams GW. Basilar and distal vertebral artery stenosis: long-term follow up. *Stroke* 1986;17:938–942
- Geremia G, Haklin M, Brennecke L. Embolization of experimentally created aneurysms with intravascular stent devices. *AJNR Am J Neuroradiol* 1994;15:1223–1231
- Szikora I, Guterman LR, Wells KM, Hopkins LN. Combined use of stents and coils to treat experimental wide-necked carotid aneurysms: preliminary results. *AJNR Am J Neuroradiol* 1994;15:1091–1102
- Turjman F, Massoud TF, Cheng J, Ji C, Guglielmi G, Viñuela F, Robert J. Combined stent implantation and endovascular coil placement for treatment of experimental wide-necked aneurysms: a feasibility study in swine. *AJNR Am J Neuroradiol* 1994;15:1087–1090
- Wakhloo AK, Lanzino G, Lieber BB, Hopkins LN. Stents for intracranial aneurysms: the beginning of a new endovascular era? *Neurosurgery* 1998; 43:377–379
- Wakhloo AK, Scheilhammer F, de Vries J, Haberstroh J, Schumacher M. Self-expanding and balloon expandable stents in the treatment of carotid aneurysms: an experimental study in canine model. *AJNR Am J Neuroradiol* 1994;15:493–502
- Lylyk P, Ceratto R, Hurvitz D, Basso A. Treatment of a vertebral dissecting aneurysm with stents and coils: technical case report. *Neurosurgery* 1998;43:385–388
- Mericle RA, Lanzino G, Wakhloo AK, Guterman LR, Hopkins LN. Stenting and secondary coiling of intracranial internal carotid artery aneurysm: technical case report. *Neurosurgery* 1998;43:1229–1233
- Sekhon LH, Morgan S, Sorby W, Grinell V. Combined endovascular stent implantation and endosaccular coil placement for the treatment of a wide-necked vertebral artery aneurysm: technical case report. *Neurosurgery* 1998;43:380–384
- Phatouros CC, Higashida RT, Malek AM, et al. Endovascular stenting of an acutely thrombosed basilar artery: technical case report and review of the literature. *Neurosurgery* 1999;44:667–673
- Wityk RJ, Chang HM, Rosengart A, et al. Proximal extracranial vertebral artery disease in the New England Medical Center Posterior Circulation Registry. *Arch Neurol* 1998;55:470–478
- Chastain HD II, Campbell MS, Iyer S, et al. Extracranial vertebral artery stent placement: in-hospital and follow-up results. *J Neurosurg* 1999; 91:547–552

36. Marks MP, Marcellus M, Norbash AM, et al. **Outcome of angioplasty for atherosclerotic intracranial stenosis.** *Stroke* 1999;30:1065–1069
37. Ahuja A, Guterman LR, Hopkins LN. **Angioplasty for basilar artery atherosclerosis: case report.** *J Neurosurg* 1992;77:941–944
38. Nakatsuka H, Ueda T, Ohta S, Sasaki S. **Successful percutaneous transluminal angioplasty for basilar stenosis: technical case report.** *Neurosurgery* 1996;39:161–164
39. Callahan AS III, Berger BL. **Balloon angioplasty of intracranial arteries for stroke prevention.** *J Neuroimaging* 1997; 7:232–235
40. Higashida RT, Tsai FY, Halbach VV, et al. **Transluminal angioplasty for atherosclerotic disease of the vertebral and basilar arteries.** *J Neurosurg* 1993;78:192–198
41. Terada T, Higashida RT, Halbach VV, et al. **Transluminal angioplasty for atherosclerotic disease of the distal vertebral and basilar arteries.** *J Neurol Neurosurg Psychiatry* 1996;60:377–381
42. Connors JJ, Wojak JC. **Percutaneous transluminal angioplasty for intracranial atherosclerotic lesions: evolution of technique and short-term results.** *J Neurosurg* 1999;91:415–423
43. Rasmussen PA, Perl J II, Barr JD, et al. **Stent assisted angioplasty of intracranial vertebrobasilar atherosclerosis: an initial experience.** *J Neurosurg* 2000;92:771–778
44. Meemon MA, Blankenship JC, Wood GC, Frey CM, Menapace FJ. **Incidence of intracranial hemorrhage complicating treatment with glycoprotein IIb/IIIa receptor inhibitors: a pooled analysis of major clinical trials.** *Am J Med* 2000;109:213–217