

Case Report

Necrotizing Neurosarcoidosis Masquerading as a Left Optic Nerve Meningioma: Case Report

Jack W. Jennings, Amy M. Rojiani, Steven S. Brem, and F. Reed Murtagh

Summary: Isolated neurosarcoidosis involving the optic nerve meninges is extremely rare and is often indistinguishable from a meningioma in its anatomic site and MR imaging presentation. Characteristic findings include enhanced perineural encasement and thickening of the affected optic nerve on contrast-enhanced T1-weighted cranial MR imaging studies. We present the case report of a patient with isolated necrotizing neurosarcoidosis of the left optic nerve, with clinical and MR imaging findings strongly suggestive of a preoperative diagnosis of a meningioma.

Neurosarcoidosis, a rare idiopathic inflammatory disease of the CNS, occurs in approximately 5% of patients with sarcoidosis (1). A wide spectrum of clinical and radiologic findings of neurosarcoidosis have mimicked and made them indistinguishable from other CNS diseases, including meningioma, tuberculosis, diffuse white matter disease, lymphomas, gliomas, metastatic carcinomatosis, meningitis, and isolated cranial nerve syndromes (1–8). Orbital and ophthalmic involvement in the presence of systemic sarcoidosis is common and well reported in the literature, with the optic nerve being one the most commonly affected cranial nerves (1, 2, 4). On the contrary, isolated optic nerve sarcoid is extremely rare, with few reported cases.

MR imaging has been shown to be sensitive yet nonspecific in identifying neurosarcoidosis (5, 6). Reports have shown MR imaging findings of involved meninges to have signal intensities that vary from isointense to hypointense on both T1- and T2-weighted images (5–8). Studies have also shown that the use of contrast enhancement with fat suppression increases the sensitivity of MR imaging in the detection of dural sheath sarcoidosis. With this technique, optic nerve involvement characteristically shows perineural enhancement and optic nerve thickening, which are best seen on coronal MR images (9–11). The case reported herein further confirms the protean nature of neurosarcoidosis and contributes an example of an

isolated necrotizing neurosarcoidosis involving the optic nerve with clinical and MR imaging findings mimicking a meningioma.

Case Report

The patient was a 44-year-old right-handed African American woman who initially presented with acute painless blurring of vision in the left eye that then progressed during a 2-week period to a dull ache with further loss of vision. Initial MR imaging revealed enhancement of the left optic nerve, thought to be consistent with optic neuritis. The patient was treated with nonsteroidal anti-inflammatory drugs and steroids; however, there was no improvement in her vision. Follow-up CT performed 4 months later showed a normal brain; however, the patient's vision loss continued to progress. Nearly 6 months after her initial presentation, an ophthalmologic examination revealed no light perception and complete loss of vision in the left eye. Extraocular muscles were intact bilaterally, and the right eye had normal visual fields with normal light perception. No other neurologic or motor deficits were noted. The patient denied any other systemic symptoms. Her medical and surgical histories were positive for hypertension, diabetes mellitus, and a hysterectomy.

MR imaging was again performed, and the findings showed the intracranial portion of the optic nerve to be symmetrically enlarged. Coronal MR images confirmed the presence of a perineural enhancing mass lesion confined primarily to the optic canal and encircling the left optic nerve. The mass was hypointense on T2-weighted images and enhanced homogeneously on fat-suppressed contrast-enhanced T1-weighted images (Fig 1). The optic chiasm, the intracranial portion of the nerve, and the para- and suprasellar structures appeared normal. The presumptive diagnosis was a left optic nerve meningioma. With this impression, it was thought that the mass might infiltrate along the skull base and threaten the contralateral vision by extending into the optic chiasm. Thus, the patient was considered an excellent surgical candidate for exploration of the optic nerve with resection and attempted removal of the tumor. The patient was offered surgical resection, not as a cure of her left-sided blindness but rather as a preventive measure to preserve sight in her right eye. The results of radiography of the chest and preoperative laboratory studies were normal.

The patient underwent left frontotemporal craniotomy with decompression of the orbital roof and optic nerve canal at a local National Cancer Institute–designated cancer center. The intracranial portion of the left optic nerve appeared normal; however, the portion in the optic canal had a tightly adherent discolored tissue around the optic nerve. Tissue specimens were sent for definitive pathologic determination, and findings from immediately frozen pathologic sections suggested that the lesion was not a meningioma but rather was consistent with granulomatous disease. Fragments of the tissue were removed to decompress the optic nerve, and the ventral remnant of the optic nerve and ophthalmic artery were left intact. A final histologic impression was multiple granulomas with multinucleated giant cells and caseating central necrosis. There was a chronic inflammatory infiltrate and histiocytes surrounding the granulomas. Findings with special stains and cultures for acid-

Received September 28, 2001; accepted after revision November 9.

From the Department of Anatomy (J.W.J.), the Department of Pathology, Division of Neuropathology (A.M.R.), the Department of Neurosurgery (S.S.B.), and the Department of Radiology, Division of Neuroradiology (F.R.M.), University of South Florida College of Medicine, Tampa, FL.

Address reprint requests to F. Reed Murtagh, MD, University Diagnostic Institute, 3301 Alumni Drive, Tampa, FL 33612.

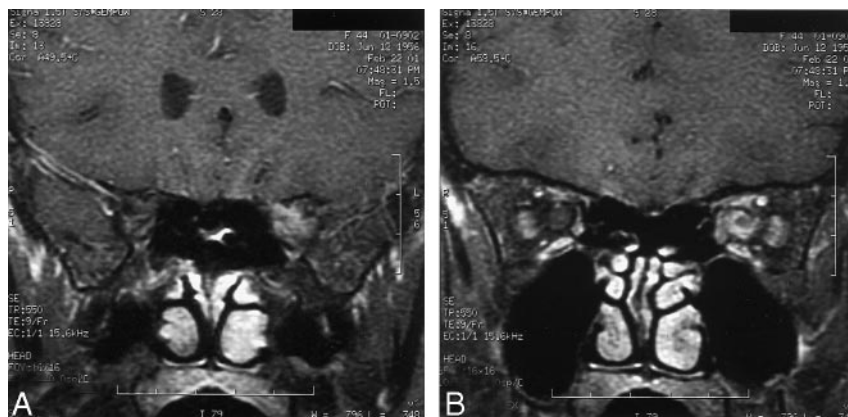


Fig 1. Fat-suppressed T1-weighted coronal view MR images (550/9/1 [TR/TE/NEX]).

A, Soft-tissue enhancing mass is seen at the orbital apex, completely surrounding the unenhanced left optic nerve.

B, Image obtained anterior to the image shown in A shows homogenous perineural enhancement of the intracranial portion of the left optic nerve.

fast bacilli and fungi were negative. These histologic features were most suggestive of necrotizing sarcoidosis. Postoperatively, the patient's findings did not change from her preoperative examination and steroid therapy was resumed. There was no evidence of systemic sarcoidosis, as revealed by initial postoperative testing. The patient underwent extensive workup to assess potential infectious causes of the granulomatosis. Results were negative for toxoplasmosis; tuberculosis; *Candida*, *Cryptococcus*, and *Bartonella* species; histoplasmosis; and HIV.

Discussion

Neurosarcoidosis is a rare disease that often mimics other pathologic processes of the CNS. Cranial nerves are often involved in neurosarcoidosis, with the most frequent being the facial nerve and the next most frequent being the optic nerve (1). Sarcoid manifesting as an isolated optic nerve tumor is extremely rare, and an extensive review of the literature by Ing et al (9) found fewer than 20 reported cases of patients with optic nerve neurosarcoidosis and no concurrent evidence of systemic disease. In the majority of these cases, the preoperative diagnosis was meningioma (9). The clinical presentation of the patient in this case report and other reports of optic nerve neurosarcoidosis mirrors that of optic nerve meningiomas with the gradual progressive loss of visual acuity and, as in this case, sometimes complete loss of vision (9).

The MR imaging findings of optic nerve dural sheath neurosarcoidosis lack specificity and do not permit its distinction from neoplastic or chronic inflammatory processes. Subsequently, these lesions, as in this case, are often operated on because a neoplasm is highly suspected. The use of contrast-enhanced MR imaging with fat suppression augments the sensitivity in detection and characteristically reveals enhanced perineural encasement and thickening of the affected optic nerve. In this case, the intracranial portion of the left optic nerve and the optic chiasm were spared. Other optic disease processes that result in characteristic enhancement of the optic nerve or its meningeal sheath include orbital pseudotumor, optic nerve meningioma, optic neuritis, and leptomeningeal spread of tumor (9–11).

The histopathologic results of the surgical biopsy were suggestive of granulomatous disease, with a final

diagnosis of necrotizing neurosarcoidosis. Permanent sections failed to reveal bacteria, fungi, mycobacteria, or foreign bodies. Necrotizing neurosarcoidosis is rare; the first histologically proven case involving the CNS was recently published (12). In the reported case, there was evidence of systemic sarcoid manifestations, unlike in this case, where there was no history or manifestation of systemic disease. A review of the literature revealed that there were no reports of this necrotizing variant of neurosarcoidosis involving the orbit or optic nerve pathway.

Considering the atypical and protean presentations of neurosarcoidosis, it is important that the condition be considered in the differential diagnosis of lesions presenting as meningiomas, but it must be a diagnosis of exclusion and necessitates a confirmatory biopsy. This awareness of neurosarcoidosis as a diagnostic possibility is necessary, and distinguishing neurosarcoidosis from a meningioma is important in making medical management decisions regarding the initiation of steroid therapy. This report presents a rare example of primary necrotizing neurosarcoidosis masquerading as a left optic nerve meningioma and confirms the difficulties in making the diagnosis from both a clinical and radiologic perspective. Finally, it also illustrates that the diagnosis of isolated optic nerve sarcoidosis in the absence of systemic involvement may still be elusive and virtually impossible to diagnose, even in the presence of advancing MR imaging and imaging technology.

References

1. Delaney P. Neurologic manifestations in sarcoidosis: a review of the literature, with report of 23 cases. *Ann Intern Med* 1977;87:336–345
2. Stern BJ, Krumholz A, Johns CJ. Neurosarcoidosis: presentation and management. *Ann N Y Acad Sci* 1986;465:722–730
3. Cahill DW, Saleman M. Neurosarcoidosis: a review of the rarer manifestations. *Surg Neurol* 1981;15:204–211
4. Zajicek JP, Scolding NJ, Foster O, et al. Central nervous system sarcoidosis: diagnosis and management. *Q J Med* 1999;92:103–117
5. Lexa FJ, Grossman RI. MR of sarcoidosis in the head and spine: spectrum of manifestations and radiographic response to steroid therapy. *AJNR Am J Neuroradiol* 1994;15:973–982
6. Miller DH, Kendall BE, Barter S, et al. Magnetic resonance imaging of central nervous system sarcoidosis. *Neurology* 1988;38:378–383

7. Seltzer S, Mark AS, Atlas SW. **CNS sarcoidosis: evaluation with contrast-enhanced MR imaging.** *AJNR Am J Neuroradiol* 1991;12:1227-1233
8. Sherman JL, Stern BJ. **Sarcoidosis of the CNS: comparison of unenhanced and enhanced MR images.** *AJNR Am J Neuroradiol* 1990;11:915-923
9. Ing EB, Garrity JA, Cross SA, Ebersold MJ. **Sarcoid masquerading as optic nerve sheath meningioma.** *Mayo Clin Proc* 1997;72:38-43
10. Carmody RF, Mafee MF, Goodwin JA, Small K, Haery C. **Orbital and optic pathway sarcoidosis: MR findings.** *AJNR Am J Neuroradiol* 1994;15:775-783
11. Engelken JD, Yuh WT, Carter KD, Nerad JA. **Optic nerve sarcoidosis: MR findings.** *AJNR Am J Neuroradiol* 1992;13:228-230
12. Strickland-Marmol LB, Fessler RG, Rojiani AM. **Necrotizing sarcoid granulomatosis mimicking an intracranial neoplasm: clinicopathologic features and review of the literature.** *Mod Pathol* 2000;13:909-913