

Are your **MRI contrast agents** cost-effective?

Learn more about generic **Gadolinium-Based Contrast Agents**.



**FRESENIUS
KABI**

caring for life

AJNR

**Plain Film Imaging of Baerveldt Glaucoma
Drainage Implants**

Elizenda M. Ceballos and Richard K. Parrish II

AJNR Am J Neuroradiol 2002, 23 (6) 935-937

<http://www.ajnr.org/content/23/6/935>

This information is current as
of April 19, 2024.

Plain Film Imaging of Baerveldt Glaucoma Drainage Implants

Elizenda M. Ceballos and Richard K. Parrish II

Summary: A glaucoma drainage implant was detected on plain skull radiographs before MR imaging examination of the brain. The patient was denied the MR imaging for fear of dislodging the “metallic foreign body.” The Baerveldt glaucoma drainage implant was mistakenly identified as an orbital metallic object based on its radiographic characteristics. Because none of the current glaucoma drainage implants contain ferromagnetic material, patients with these devices can undergo MR imaging without special precaution.

Drainage implants are increasingly being used for the surgical treatment of glaucoma refractory to medical and standard surgical therapy. Echographic and radiographic findings may suggest the diagnosis of an orbital foreign body if the ophthalmic history is not known.

Case Report

An asymptomatic 82-year-old female patient with open angle glaucoma presented to her ophthalmologist for evaluation of a “metallic object” in her left orbit (Fig 1). The object in question was identified as a 350-mm² Baerveldt glaucoma drainage implant (Pharmacia Co., Kalamazoo, MI) that had been previously placed to lower intraocular pressure. The smooth convex radiographic profile of the device corresponded to the globe curvature in the superotemporal orbit.

Discussion

Of the commercially available glaucoma drainage implants, only the Baerveldt glaucoma drainage im-

plant (250, 350, and 425 mm²) is radiopaque (Fig 2). Barium-impregnated silicone used in the fabrication of the Baerveldt plate increases echographic resolution and facilitates radiographic identification. The Krupin-Denver eye valve to disc implant (184 mm²) (E. Benson Hood Laboratories, Pembroke, MA), Ahmed glaucoma valve (184 mm²) (New World Medical, Rancho Cucamonga, CA), Molteno drainage device (single plate 129 mm² and double plate 259 mm²) (Molteno Ophthalmic Ltd., Dunedin, New Zealand), and the Joseph valve (Valve Implants Limited, Hertford, England) feature a translucent silicone tube connected to a plate made of rigid plastic or flexible silicone rubber that is fixed to the sclera (Fig 3). None of these devices contain ferromagnetic material or have been impregnated with a radiopaque substance.

Intraocular pressure is lowered when aqueous humor flows from inside the eye through the tube into the space between the plate that rests on the scleral surface and surrounding fibrous capsule. The adjacent periocular tissues absorb aqueous humor from the reservoir. Although intraocular ferromagnetic foreign bodies have been shown to move during MR imaging (1–3), because neither the Baerveldt drainage implant nor any of the other commercially available devices contain ferromagnetic material, inadvertent dislocation of these devices is unlikely.

References

1. Lagouros PA, Langer BG, Peyman GA, Mafee MF, Spigos DG, Grisolano J. **Magnetic resonance imaging and intraocular foreign bodies.** *Arch Ophthalmol* 1987;105:551–553
2. Williams S, Char DH, Dillon WP, Lincoff N, Moseley M. **Ferrous intraocular foreign bodies and magnetic resonance imaging.** *Am J Ophthalmol* 1988;105:398–401
3. Ta CN, Bowman RW. **Hyphema caused by metallic intraocular foreign body during magnetic resonance imaging.** *Am J Ophthalmol* 2000;129:533–534

Received August 13, 2001; accepted after revision January 28, 2002.

From the Department of Ophthalmology, University of Miami School of Medicine, Miami, FL.

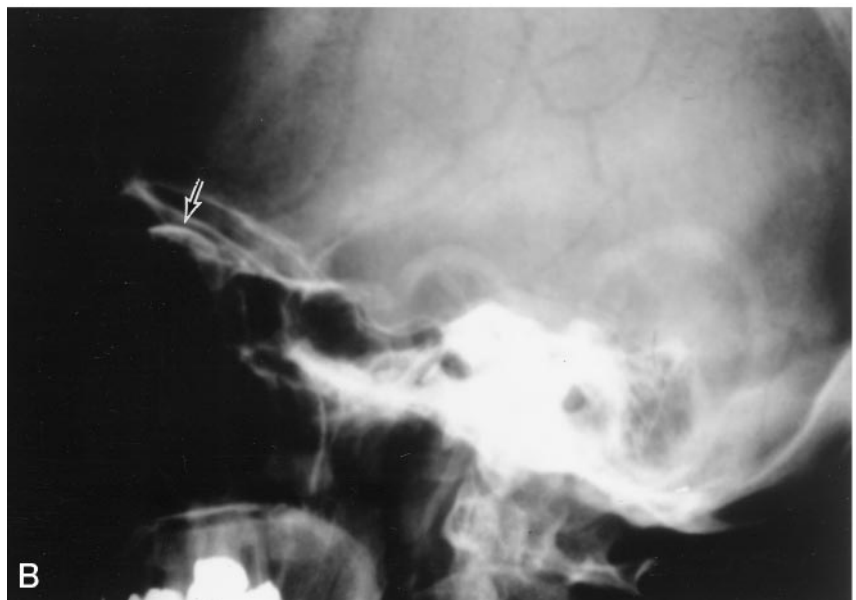
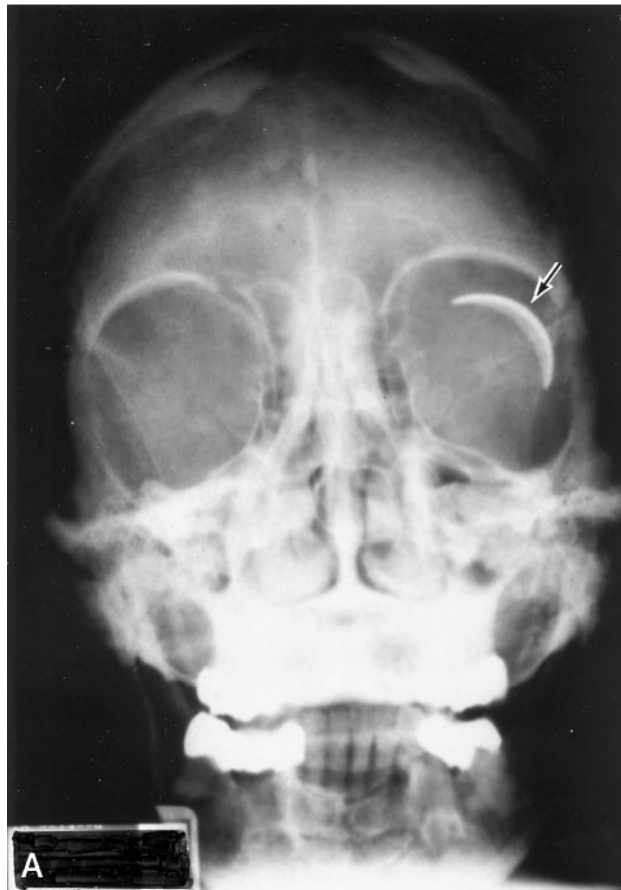Address reprint requests to Richard K. Parrish II, MD, Department of Ophthalmology, University of Miami School of Medicine, 900 NW 17th Street, Miami, FL 33136.

© American Society of Neuroradiology

FIG 1. Plain film radiographs obtained from an asymptomatic 82-year-old female patient with open angle glaucoma who presented to her ophthalmologist for evaluation of a "metallic object" in her left orbit.

A, Anteroposterior view shows the convex, barium-impregnated plate of the Baerveldt glaucoma drainage implant positioned superotemporally on the globe.

B, Lateral view shows the implant.



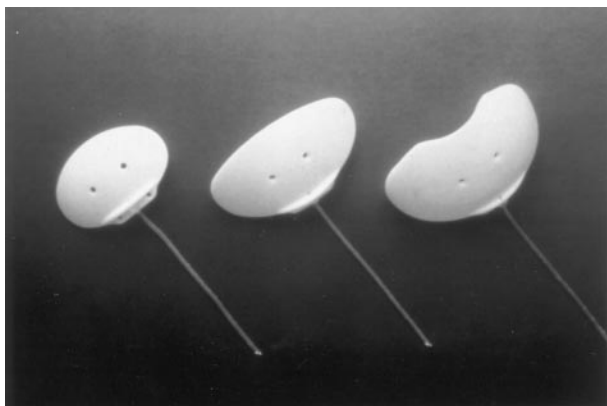


FIG 2. Baerveldt glaucoma drainage implants are shown in three sizes with surface areas of 250, 350, and 425 mm² (*left to right*).

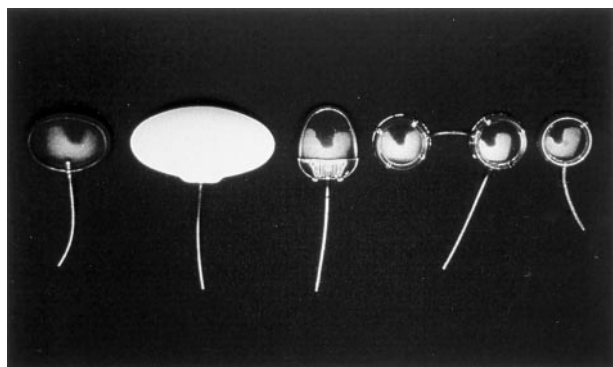


FIG 3. Commercially available glaucoma drainage devices are shown. From *left to right*, they are the Krupin drainage device, Baerveldt drainage implant (350 mm²), Ahmed implant, double plate Molteno device, and single plate Molteno device. (Note that the Joseph valve is not shown).