

Are your MRI contrast agents cost-effective?

Learn more about generic Gadolinium-Based Contrast Agents.



AJNR

**Intraarterial Administration of Abciximab
for Thromboembolic Events Occurring
during Aneurysm Coil Placement**

Charbel Mounayer, Michel Pötting, Sebastian Baldi, Laurent
Spelle and Jacques Moret

This information is current as
of April 19, 2024.

AJNR Am J Neuroradiol 2003, 24 (10) 2039-2043
<http://www.ajnr.org/content/24/10/2039>

Intraarterial Administration of Abciximab for Thromboembolic Events Occurring during Aneurysm Coil Placement

Charbel Mounayer, Michel Piotin, Sebastian Baldi, Laurent Spelle, and Jacques Moret

BACKGROUND AND PURPOSE: Platelet-derived thrombi may occur during intracranial aneurysm coiling. We report a series of 13 patients treated with intraarterial Abciximab for thrombus formation complicating aneurysm coiling.

METHODS: Four patients were treated for acutely ruptured aneurysms. Three procedures consisted of the retreatment of previously coiled aneurysms. Six patients had asymptomatic untreated aneurysms. Abciximab was administered intraarterially through a microcatheter as a bolus of 4–10 mg over a period of 10–20 minutes. All patients underwent postthrombolysis control angiography. They also underwent immediate pre- and postoperative cranial CT.

RESULTS: In 10/13 cases, the thrombi developed without coil protrusion into the parent artery. In one case, the thrombus was generated from the guiding catheter and embolized remote from the aneurysm site. In one case, the thrombus developed before any coil placement. In another patient, a coil loop protruded into the parent artery favoring a heightened thrombotic state. Arterial thrombi were totally occlusive in two patients, whereas in the remaining 11 cases, the thrombi were not totally obstructive. Complete recanalization was achieved in 92% (12/13) of cases within 20–30 minutes. Incomplete arterial reopening was noted in one case, in which a thrombus fragment embolized distally, causing cerebral infarction. There were no Abciximab-related intracranial hemorrhages.

CONCLUSION: Intraarterial Abciximab was effective in this series for the treatment of thrombotic complications occurring during aneurysm coiling.

Thromboembolic complications, typically platelet-derived events, occur during aneurysm coiling in approximately 3% of the cases, resulting in a permanent neurologic disability in 1.7–5% of the procedures (1–3). In eloquent brain areas, thrombus disruption (of either mechanical or pharmacological origin) to reestablish arterial blood flow is mandatory when a thrombotic occlusion occurs in the absence of collateral flow. Until now, intraarterial thrombolysis with fibrinolytic agents has been widely used, but their benefit is hampered by the risk of subsequent intracranial hemorrhage (ICH), especially in the setting of acutely ruptured aneurysms. Moreover, the intraarterial administration of urokinase achieves arterial recanalization in only 47% of cases (4). Abciximab, the Fab fragment of the chimeric human-murine mono-

clonal antibody 7E3, binds to the glycoprotein Iib/IIIa receptor, as well as the vitronectin ($\alpha v \beta 3$) receptor, inhibiting platelet aggregation with additional antithrombotic properties. Until now, few small series have reported the potential usefulness of Abciximab in the management of thromboembolic complications occurring in the setting of the endovascular treatment with detachable coils of intracranial aneurysms (5–8). We report our experience of intraarterial administration of Abciximab in the treatment of 13 patients for whom aneurysm coiling was complicated by thromboembolic events.

Methods

From January 2002 to October 2002, 227 aneurysms were treated by endovascular means. Ninety-eight of these 227 interventions were conducted with the balloon-remodeling technique, 14 were carried out with the assistance of a stent, and three were treated with a neck-bridge device (Trispan; Target/Boston Scientific, Fremont, CA). During the same period of time, 13 patients (eight men and five women; mean age, 49 years) developed intraprocedural thromboembolic complications during endovascular treatment of aneurysms with coils. Four patients were treated for acutely ruptured aneurysms; the delay from the onset of subarachnoid hemorrhage did not exceed 48 hours in all four cases. Three of these ruptured

Received May 27, 2003; accepted after revision July 7.

From the Department of Interventional Neuroradiology, Fondation Rothschild, Paris, France.

Address correspondence and reprint requests to Jacques Moret, MD, Service de Neuroradiologie Interventionnelle, Hôpital de la Fondation Rothschild, 25–29 rue Manin 75940 Paris Cedex 19, France.

Case characteristics

Patient No./ Sex/Age (y)	Abciximab (mg/Kg)	Aneurysm Location	Acutely Ruptured	Coiling Technique	Thrombus Location	Vessel Occlusion
1/F/42	0.062	AcoA	No	Remodeling	A2 origin	No
2/F/53	0.125	Basilar tip	No	Remodeling	P1 origin	No
3/F/45	0.096	Supra ICA	No	NA	MCA	No
4/M/40	0.1	ICA Bif	No	Remodeling	MCA	No
5/F/48	0.08	PcoA	No	Std	PcoA origin	No
6/M/46	0.061	AcoA	No	Remodeling	A2 origin	No
7/F/56	0.071	AcoA	No	Std	A2 origin	No
8/M/48	0.06	AcoA	Yes	Std	AcoA A2 origin	Yes
9/M/61	0.053	MCA Bif	Yes	Remodeling	A5	No
10/M/45	0.057	MCA Bif	Yes	Remodeling	Upper trunk of MCA	Yes
11/M/47	0.065	AcoA	Yes	Remodeling	A2 origin	No
12/M/55	0.057	ICA Bif	No	Remodeling	M1 origin	No
13/M/51	0.054	MCA Bif	No	Remodeling	Upper trunk of MCA	No

Note.—AcoA, anterior communicating artery; ICA bif, bifurcation of the internal carotid artery; MCA bif, bifurcation of the middle cerebral artery; NA, not applicable; PcoA, posterior communicating artery; Std, standard coiling technique; Supra ICA, supraclinoid internal carotid artery.

aneurysms were coiled with the remodeling technique by using a balloon microcatheter that was temporarily inflated across the aneurysm neck during coil delivery. Three of 13 interventions consisted of the retreatment of partially recanalized previously coiled aneurysms; all three of these interventions were conducted at least 1 year after the initial coiling. These three aneurysms were retreated with the remodeling technique. Six of the 13 patients harbored an asymptomatic aneurysm, three of which were coiled with the remodeling technique. All patients were given an initial bolus of 5000 IU of heparin followed by the continuous infusion of 2500–3000 IU/h to maintain an activated clotting time (ACT) between 200 and 300 seconds. In accordance with our anticoagulation protocol, a 250-mg intravenous bolus of aspirin was administered to the patients for whom the aneurysm was not ruptured or was in the setting of a retreatment. Abciximab (ReoPro; Centocor, Malvern, PA) was administered intraarterially through the coil delivery microcatheter (Excelsior; Boston/Target, Fremont, CA) with its distal tip inserted in the occluded artery adjacent to the thrombus. The catheter tip was located just proximal to the aneurysm neck in 11 of 13 cases. In the remaining two cases (patients 3 and 9), the catheter tip was navigated distally up to the thrombus, which was located remote from the aneurysm site. Abciximab, diluted in saline to achieve a concentration of 0.2 mg/mL, was administered as a bolus of 4–10 mg over a period of 10–20 minutes, depending on how fast thrombus resolution was achieved while preventing injections exceeding 10 mg. In two cases, a concomitant local intraarterial bolus of 4 mg of Nimodipine was administered to resolve an associated vasospasm. All patients underwent postthrombolysis control angiography. They also underwent immediate pre- and postprocedural cranial CT in the angiographic room as we routinely do in the setting of endovascular treatment of cerebral aneurysms. Relevant data of all the 13 cases are summarized in the Table.

Results

In 10/13 cases (78%), the thrombi originated and were in contact with the coil mesh without any angiographically apparent coil protrusion into the parent artery. In one case of a right middle cerebral artery bifurcation aneurysm, the thrombus was located distally in the right anterior cerebral artery, as the embolus was generated from the guiding catheter totally irrespective of the aneurysm location. In another case, the thrombus developed before any coil place-

ment; this patient was later shown to have an elevated factor VIII and a short ACT (30 seconds). Abciximab was administered and successfully dissolved the complicating clot, although no coils were placed. In another patient, a coil loop protruded into the parent artery, favoring a heightened thrombotic state. Seven patients had broad-neck aneurysms in which the coil-blood interface was large, thus increasing the thrombotic risk. Arterial thrombi were totally occlusive in two patients (Fig 1) whereas in the remaining eleven cases, the thrombi were small and not completely obstructive but compromising downstream arterial flow (Fig 2). Complete recanalization was achieved in 92% (12/13) of cases. In these patients, the thrombus dissolution was achieved within 20–30 minutes after the end of the Abciximab perfusion. Incomplete arterial reopening was obtained in one case in which a thrombus fragment embolized distally; Abciximab failed to completely dissolve the thrombus and a CT scan revealed a cerebral infarct in the territory of the compromised arterial branch (patient 9). This patient presented on admission with a ruptured aneurysm associated with a cerebral hematoma and a left hemiplegia; he subsequently died at day 4 from intracranial vasospasm. The deleterious effect of the vasospasm was augmented by the cerebral infarct secondary to the distal embolus. No evidence of postthrombolysis ICH or other developments of aggregated neurologic deficits related to the thrombotic events were present.

Discussion

Abciximab is a potent glycoprotein receptor inhibitor capable of preventing thrombosis. It is indicated as an adjunct to percutaneous coronary intervention for the prevention of cardiac ischemic complications. The standard dose of Abciximab in coronary angioplasty is an intravenous bolus of 0.25 mg/kg followed by a 12-hour infusion of 0.125 μ g/kg/min. There are several reports in the literature of the thrombolytic

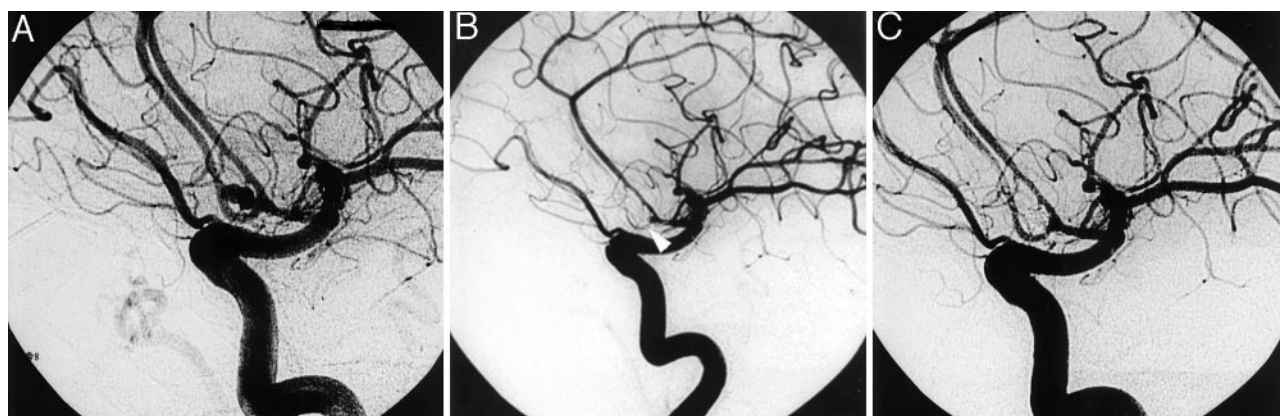


FIG 1. Case 8.

A, Left ICA (best projection), showing a ruptured anterior communicating artery (AcoA) aneurysm before the embolization treatment.
 B, Left ICA (best projection) after aneurysm coiling, showing an obstructive thrombus (arrowhead) at the origin of the AcoA.
 C, Left ICA (best projection) 20 minutes after the local delivery of 4 mg of Reopro, showing the restoration of the arterial flow in the AcoA and the right A2 segment.

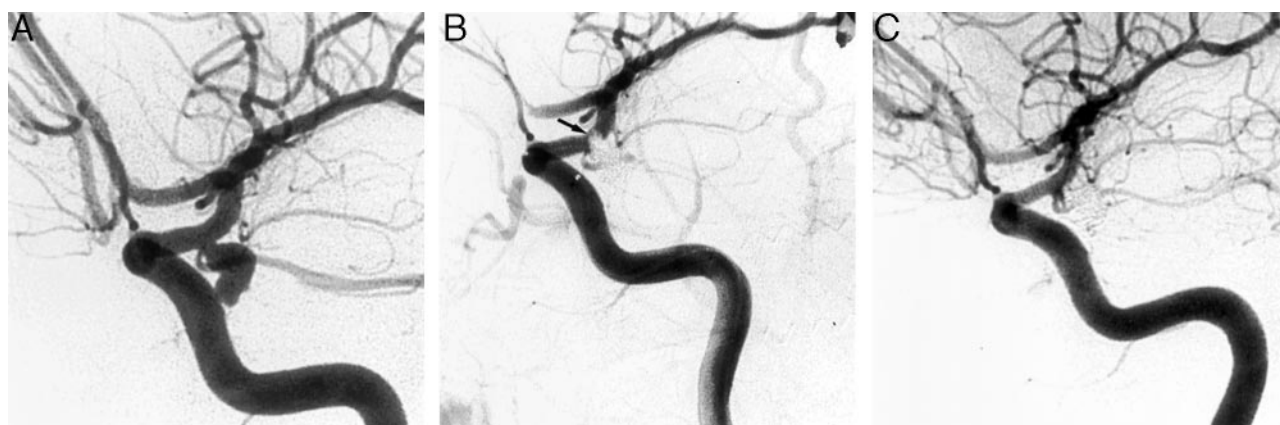


FIG 2. Case 5.

A, Left ICA (best projection), showing a ruptured supraclinoid ICA at the origin of the posterior communicating artery.
 B, Left ICA (best projection) after aneurysm coiling showing a nonocclusive thrombus (arrow) into the ICA lumen (arrow).
 C, Left ICA (best projection) 30 minutes after the local delivery of 4 mg of Reopro, showing that the thrombus has been desegregated.

properties of Abciximab and of its benefits during endovascular intracranial procedures. These reports have shown that Abciximab has a potential indication as a rescue agent after failed thrombolysis (6, 9, 10) in the management of thrombotic complications of intracranial angioplasty (11), in the treatment of complications occurring during carotid angioplasty (5, 12, 13), and in aneurysm coiling (5–8). Abciximab has also been used in combination with fibrinolytic agents to enhance thrombolysis (6, 14). Abciximab was administered intraarterially in only three of these reports (6, 12, 15). In experimental studies, rapid and complete resolution of preformed thrombi was achieved after early administration of Abciximab in a dose-dependent manner. This dose-dependent dispersion of platelet aggregates back to single cells was observed with Abciximab concentration well above the recommended dose used in coronary procedures (16). The mechanism of this effect was shown to be due to partial displacement of platelet-bound fibrinogen by Abciximab. In addition to its ability to disperse platelet aggregates, Abciximab has properties

that impede the formation and stability of clot structure. It has been shown to allow the penetration of both endogenous and parenteral fibrinolytic agents into the clot, thereby promoting more rapid and extensive thrombolysis (17). The latter property is of significant importance particularly in older clots (ie, those consisting of platelets as well as fibrin and red blood cells).

Dose and Administration of Abciximab

We chose to deliver a 4-mg bolus of Abciximab intraarterially, up to a maximum of 10 mg. The above-mentioned experimental data showed that early administration of Abciximab (within a minute of thrombus formation) at high concentrations led to rapid desegregation of the thrombus. We observed that clot resolution began within 20 minutes and was complete within 30 minutes in 92% (12/13) of the cases. It is likely that the local and immediate intraarterial administration of low doses of Abciximab effectively

produced high concentrations at the site of the thrombus.

To our knowledge, only three reports of intraarterial administration of Abciximab in the cerebral circulation exist in the literature. In two cases of acute distal embolization associated with carotid angioplasty, Abciximab was successfully used in a selective internal carotid bolus injection of 5 mg followed by an intravenous bolus of 5 mg (15). In three other cases of ischemic cerebrovascular events complicating carotid stent placement procedures, Abciximab bolus (0.25 mg/kg) was injected into the common carotid artery, followed by the standard coronary intravenous infusion of 0.125 μ g/kg/min for 12 hours. Symptoms resolved in all three cases within 5 hours (12). Kwon et al (6) recently reported three cases of intraarterial use of Abciximab as a bailout procedure after failure of urokinase therapy for acute thrombosis of cerebral arteries. Abciximab was injected intraarterially at doses of 4 mg, 5 mg, and 10 mg, respectively, achieving a rapid flow restoration without hemorrhagic complications.

In our series, because the intraarterial route was chosen, a reduced partial bolus of 4–10 mg was used, representing a small fraction of the dose used for prophylactic administration of Abciximab in percutaneous coronary procedures (eg, 20 mg Abciximab bolus in an 80-kg adult). The standard recommended 12-hour Abciximab infusion, after bolus administration, maintains a platelet blockade during the highly thrombogenic phase within the first hours after coronary angioplasty and stent placement. In our cases, the procedure consisting of aneurysm embolization, with coils and any possible thrombi forming downstream of the aneurysm, would occur at a site without current vessel wall damage. Therefore, we did not consider that there was a need for prolonged anti-thrombotic coverage once the thrombus had dissolved.

Risk of Intracranial Hemorrhage

The main and potentially serious concern with Abciximab is bleeding. Abciximab is recommended to be used with low-dose heparin (≤ 70 IU/kg) in conjunction with aspirin. No increase of major bleeding was observed as compared with that of heparin administration alone. It is important to note that the incidence of ICH in patients receiving Abciximab was not different from placebo in more than 8500 patients from the combined analysis of four major trials (18). There was, however, an insignificant trend toward increased ICH when Abciximab was used in combination with a high dose of nonweight-adjusted heparin (bolus $>10,000$ IU). Furthermore, in a randomized double-blind, placebo-controlled study designed to evaluate the safety of Abciximab in acute ischemic stroke, the rate of ICH was not increased as compared with that of placebo, despite enrollment of patients up to 24 hours after stroke onset (19). However, minor bleeding (3–5 g/L of hemoglobin loss) was increased by Abciximab, although most occurred at

the vascular access site. Our patients underwent full heparinization, obtaining an ACT between 200 and 300 seconds. Patients in whom ICH was ruled out received an additional 250 mg of aspirin at the beginning of the procedure. We did not observe any ICH with this pharmacological combination; however, the amount of platelet-bound circulating Abciximab was certainly negligible in our patients. The absence of ICH in our series compares favorably with the risk of ICH when urokinase is used as a thrombolytic agent.

Conclusion

In our series, Abciximab proved a safe and effective rescue agent for thromboembolic complications during aneurysm coil placement. As a result, we no longer administer urokinase in the management of thrombotic complications in neurovascular procedures. The selective intraarterial administration of Abciximab allows significantly reduced dosing while providing a favorable safety profile and lowered costs.

References

1. Eskridge JM, Song JK. Endovascular embolization of 150 basilar tip aneurysms with Guglielmi detachable coils: results of the Food and Drug Administration multicenter clinical trial. *J Neurosurg* 1998;89:81–86
2. McDougall CG, Halbach VV, Dowd CF, et al. Endovascular treatment of basilar tip aneurysms using electrolytically detachable coils. *J Neurosurg* 1996;84:393–399
3. Vinuela F, Duckwiler G, Mawad M. Guglielmi detachable coil embolization of acute intracranial aneurysm: perioperative anatomical and clinical outcome in 403 patients. *J Neurosurg* 1997;86:475–482
4. Cronqvist M, Pierot L, Boulain A, et al. Local intraarterial fibrinolysis of thromboemboli occurring during endovascular treatment of intracerebral aneurysm: a comparison of anatomic results and clinical outcome. *AJNR Am J Neuroradiol* 1998;19:157–165
5. Cloft HJ, Samuels OB, Tong FC, Dion JE. Use of abciximab for mediation of thromboembolic complications of endovascular therapy. *AJNR Am J Neuroradiol* 2001;22:1764–1767
6. Kwon OK, Lee KJ, Han MH, et al. Intraarterially administered abciximab as an adjuvant thrombolytic therapy: report of three cases. *AJNR Am J Neuroradiol* 2002;23:447–451
7. Lempert TE, Malek AM, Halbach VV, et al. Rescue treatment of acute parent vessel thrombosis with glycoprotein IIb/IIIa inhibitor during GDC coil embolization. *Stroke* 1999;30:693–695
8. Ng PP, Phatouros CC, Khangure MS. Use of glycoprotein IIb-IIIa inhibitor for a thromboembolic complication during Guglielmi detachable coil treatment of an acutely ruptured aneurysm. *AJNR Am J Neuroradiol* 2001;22:1761–1763
9. Houdart E, Woimant F, Chapot R, et al. Thrombolysis of extracranial and intracranial arteries after IV abciximab. *Neurology* 2001;56:1582–1584
10. Wallace RC, Furlan AJ, Moliterno DJ, et al. Basilar artery rethrombosis: successful treatment with platelet glycoprotein IIb/IIIa receptor inhibitor. *AJNR Am J Neuroradiol* 1997;18:1257–1260
11. Piotin M, Blanc R, Kothimbakam R, et al. Primary basilar artery stenting: immediate and long-term results in one patient. *AJR Am J Roentgenol* 2000;175:1367–1369
12. Ho DS, Wang Y, Chui M, et al. Intracarotid abciximab injection to abort impending ischemic stroke during carotid angioplasty. *Cerebrovasc Dis* 2001;11:300–304
13. Tong FC, Cloft HJ, Joseph GJ, et al. Abciximab rescue in acute carotid stent thrombosis. *AJNR Am J Neuroradiol* 2000;21:1750–1752
14. Eckert B, Koch C, Thomalla G, et al. Acute basilar artery occlusion treated with combined intravenous Abciximab and intra-arterial tissue plasminogen activator: report of 3 cases. *Stroke* 2002;33:1424–1427
15. Kittusamy PK, Koenigsberg RA, McCormick DJ. Abciximab for the

- treatment of acute distal embolization associated with internal carotid artery angioplasty. *Catheter Cardiovasc Interv* 2001;54:221–233
16. Marciniak SJ Jr, Mascelli MA, Furman MI, et al. An additional mechanism of action of abciximab: dispersal of newly formed platelet aggregates. *Thromb Haemost* 2002;87:1020–1025
17. Collet JP, Montalescot G, Lesty C, Weisel JW. A structural and dynamic investigation of the facilitating effect of glycoprotein IIb/IIIa inhibitors in dissolving platelet-rich clots. *Circ Res* 2002;90:428–434
18. Akkerhuis KM, Deckers JW, Lincoff AM, et al. Risk of stroke associated with abciximab among patients undergoing percutaneous coronary intervention. *JAMA* 2001;286:78–82
19. Abciximab in Ischemic Stroke Investigators. Abciximab in acute ischemic stroke: a randomized, double-blind, placebo-controlled, dose-escalation study. *Stroke* 2000;31:601–609