

Are your **MRI contrast agents** cost-effective?

Learn more about generic **Gadolinium-Based Contrast Agents**.



**FRESENIUS
KABI**

caring for life

AJNR

**Aortic Arch Origin of the Left External
Carotid Artery and Type II Proatlantal Fetal
Anastomosis**

Michael Horowitz, Surendra Bansal and Kush Dastur

AJNR Am J Neuroradiol 2003, 24 (3) 323-325

<http://www.ajnr.org/content/24/3/323>

This information is current as
of April 20, 2024.

Aortic Arch Origin of the Left External Carotid Artery and Type II Proatlantal Fetal Anastomosis

Michael Horowitz, Surendra Bansal, and Kush Dastur

Summary: This case report demonstrates a rare vascular pattern of a left external carotid artery (ECA) that arises directly from the aortic arch (AA), along with a type II proatlantal-vertebral artery anastomosis. Our research shows no report of an ECA arising from the AA. This, in association with a type II proatlantal anastomosis, is interesting because of its apparent rarity.

A variety of aortic arch (AA) branch anomalies have been reported, but we found no report of an external carotid artery (ECA) that arises directly from the AA. Such an aberrant origin in association with a type II proatlantal artery must be so rare as to be reportable. This case documents such a vascular pattern.

Case Report

A 50-year-old woman presented with transient ischemic events. An arteriogram was requested by the referring physician to evaluate for the presence of hemodynamic abnormalities or sources of emboli. The study showed a left ECA and left internal carotid artery (ICA) arising separately from the aortic arch (Figs 1–3). A type II proatlantal intersegmental artery was also identified (Figs 4–5).

Discussion

The AA and great vessels develop secondary to the formation and selective regression of paired vascular arches that connect the embryonic aortic sac (ventral aorta) with the paired dorsal aortae (1). During the first 35 days of fetal development, the primitive carotid arteries provide most of the intracranial blood flow (1). The proximal part of the primitive carotid arteries arises from the ventral aorta and third AAs and gives rise to the common carotid arteries. The distal segments of the primitive carotid arteries arise from the paired dorsal aortae and give rise to the

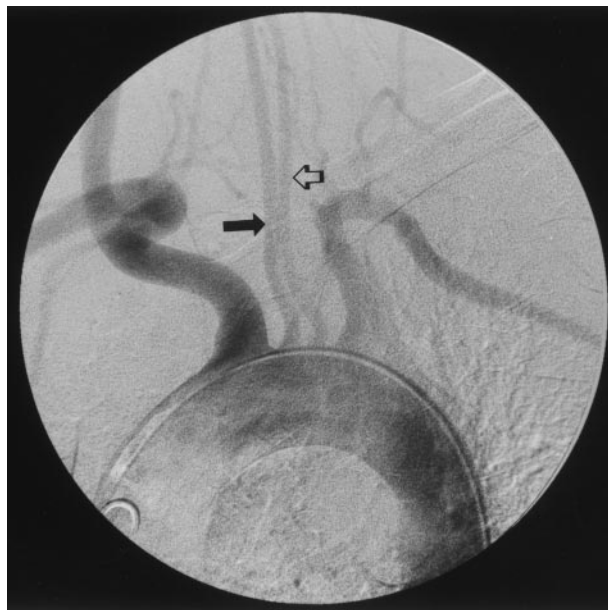


FIG 1. Oblique view of the AA shows the left ECA (solid arrow) and the left ICA (open arrow) arising separately from the AA.

ICAs (1). The ECAs arise as outgrowths from the third AAs (1). The ECA ultimately supplies those regions originally supplied by the ventral pharyngeal arteries, which arise from the ventral aorta and supplied the pharyngeal pouches.

While the AA and carotid circulation are developing, the future vertebrobasilar system is developing. The vertebral arteries are formed from plexiform longitudinal anastomoses between the cervical intersegmental arteries (1). Connections between the paired plexiform longitudinal neural arteries and the carotid system exist and form what we know as the persistent fetal anastomoses (proatlantal intersegmental, hypoglossal, otic, and trigeminal arteries) (1, 2). These anastomoses eventually regress in most individuals; the only connection between the anterior and posterior circulations is the posterior communicating arteries.

The case described in this report is unique in several aspects. We have not encountered any other reports in the literature demonstrating a left ECA arising directly from the AA nor have we seen any literature describing such an ECA giving rise to a type II proatlantal intersegmental artery (proatlantal intersegmental artery arising from the ECA). It is clear that the anomalies found in this patient developed within the first 4–6 weeks of gestation.

Received August 5, 2002; accepted August 21.

From the Department of Neurosurgery and Radiology, Presbyterian Hospital, University of Pittsburgh Medical Center (M.H.) and the Department of Radiology, Mercy Hospital, Pittsburgh (S.B., K.D.), PA.

Address reprint requests to Michael Horowitz, MD, Department of Neurosurgery, Suite B400, 200 Lothrop Street, Pittsburgh, PA 15238.

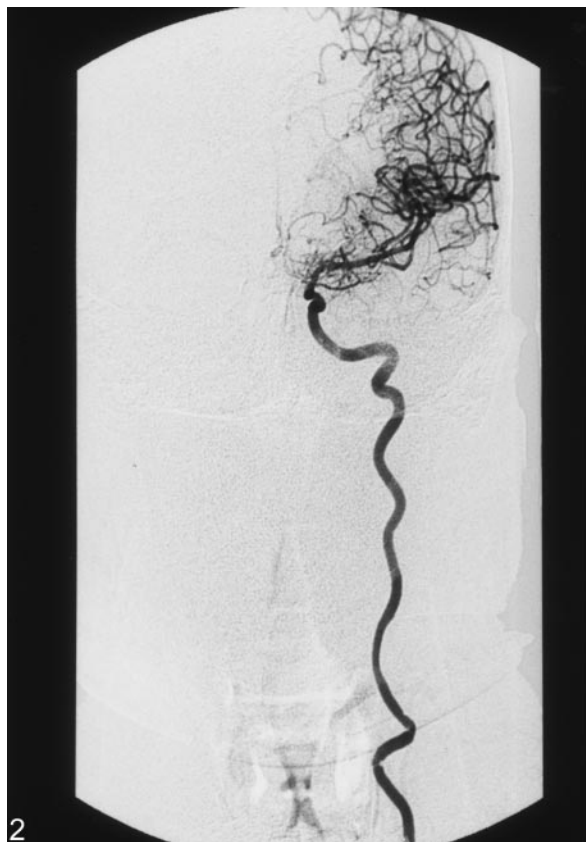

FIG 2. Anteroposterior (AP) view of the nonbranching ICA.

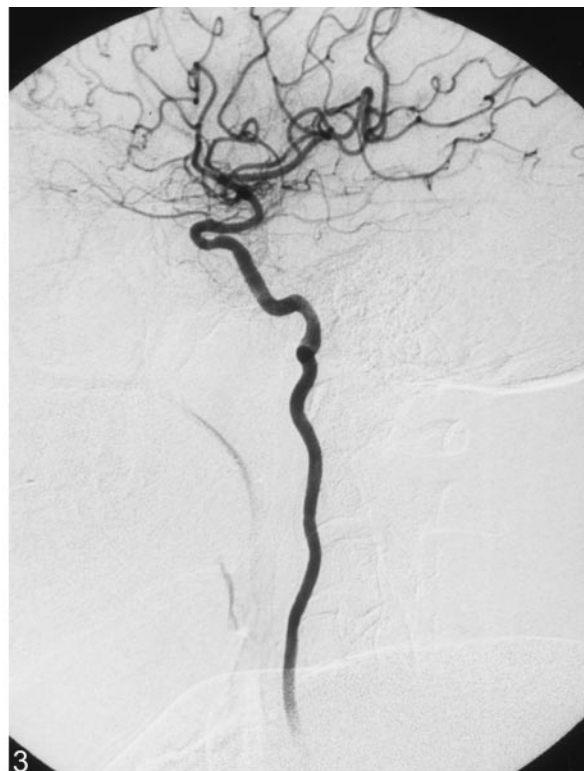

FIG 3. Lateral view of the nonbranching left ICA.

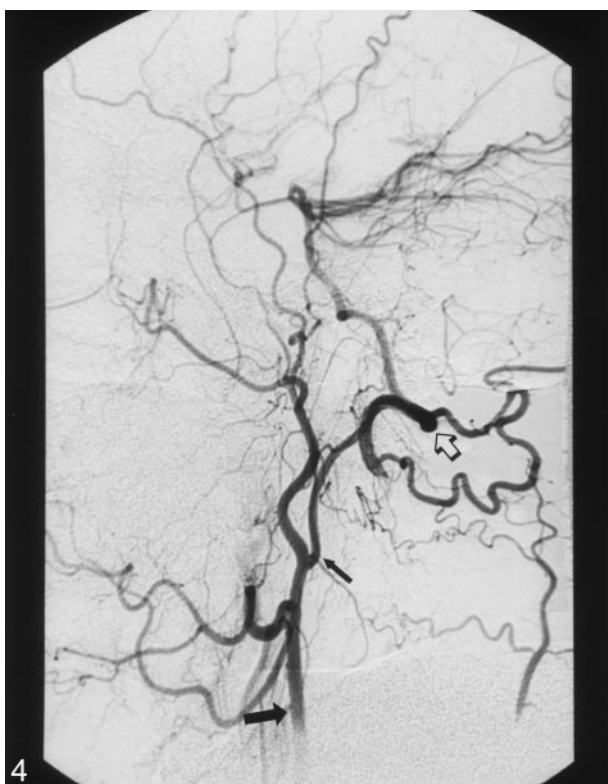

FIG 4. Lateral view of left the ECA (*bottom solid arrow*), type II proatlantal intersegmental artery (*top solid arrow*), and vertebral artery (*open arrow*).

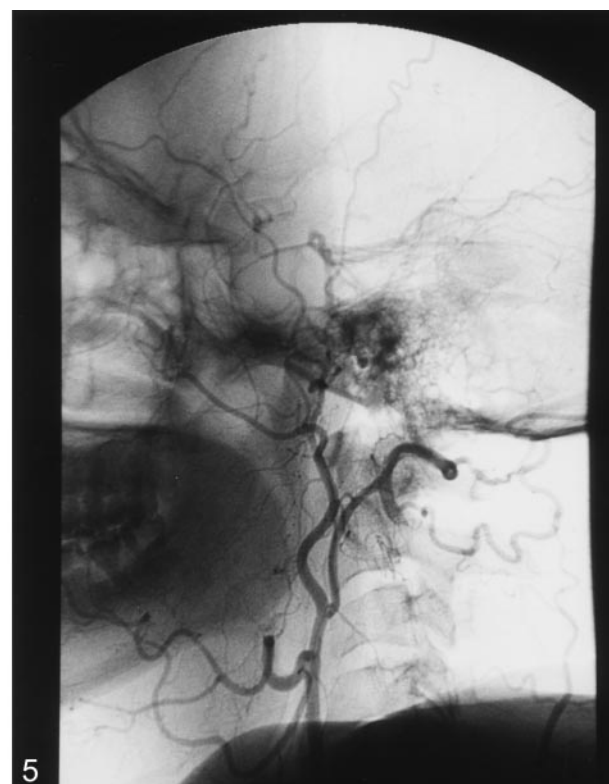


FIG 5. Nonsubtracted image of Figure 4 shows the relationship of the arteries to the spinal levels.

We speculate that they are due to abnormal regression of the ventral aorta, the third AA, the ventral pharyngeal arteries, and the proatlantal intersegmental artery anastomoses. Aside from being an angiographic curiosity, this finding reminds us of the complex nature of human development.

References

1. Osborn AG. **The aortic arch, external carotid artery and internal carotid artery.** In: Osborn AG, ed. *Diagnostic Cerebral Angiography*. 2nd ed. New York: Lippincott, Williams & Wilkins; 1999:1-83
2. Lasjaunias P, Berenstein A. **Arterial anatomy: introduction.** In: Lasjaunias P, Berenstein A, eds. *Surgical Neuro-angiography Functional Anatomy of Craniofacial Arteries*. New York: Springer-Verlag. 1987:1-11