

Are your MRI contrast agents cost-effective?

Learn more about generic Gadolinium-Based Contrast Agents.



FRESENIUS
KABI

caring for life

AJNR

Abdominal-Pelvic MRI

AJNR Am J Neuroradiol 2003, 24 (5) 1025

<http://www.ajnr.org/content/24/5/1025>

This information is current as
of April 20, 2024.

Abdominal-Pelvic MRI

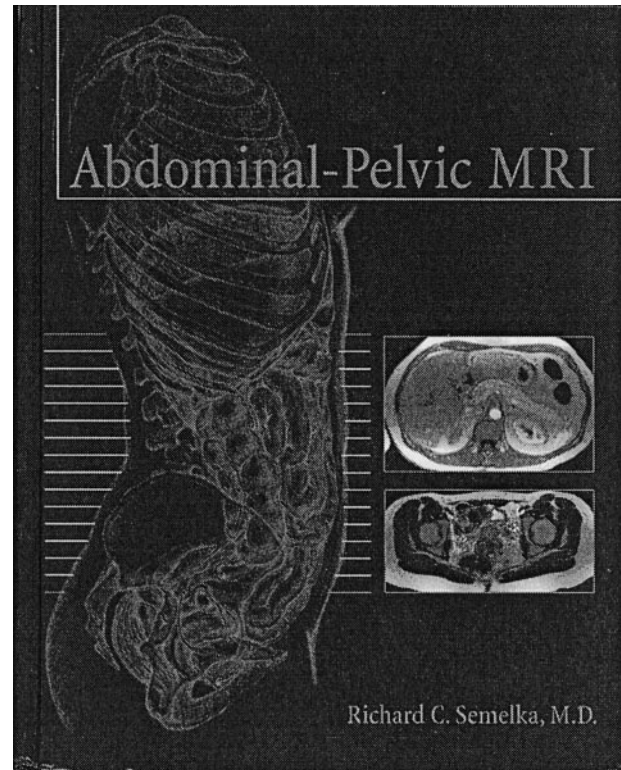
Richard C. Semelka, ed. 2nd ed. New York: Wiley-Liss; 2002. 1,224 pages, 2000 illustrations. \$245.00.

This is the second edition of Semelka's *Abdominal-Pelvic MRI*. The new volume has doubled in size and, because of the increase in the number of illustrations, now comprises 1200 pages, making it an atlas. In the preface, Semelka, a well-recognized authority in the field, states that the purpose of the book is to "provide a clear and balanced text and atlas describing the disorders of the abdomen and pelvis with MR imaging." To a great extent, he has succeeded with the help of a handful of authors, mainly from the same radiology department, and a few selected experts from other institutions. To the best of my knowledge, no comparable book on this subject with the same depth and scope has been published recently in English.

The book is organized into 15 chapters. The first describes MR imaging protocols and the different MR imaging techniques to study the abdomen and pelvis. The chapter is very informative and clearly written and contains information regarding conventional and new pulse sequences available. A series of tables at the end of each chapter gives useful outlines for the practical application of body MR protocols in a day-to-day practice.

The second chapter concerns the liver. In keeping with the current importance of MR imaging of this organ—undoubtedly the number one subject of body MR—it is almost 300 pages long. This comprehensive chapter alone justifies purchase of the book. Not only are the different MR imaging techniques described, but extensive examples of pathologic conditions, including both diffuse liver disease and focal liver masses, are well outlined and illustrated. Chapter 3 is dedicated to the gallbladder and biliary system and has good coverage of MRCP, attesting to its importance in current MR imaging practice. The next chapter is dedicated to the pancreas, one of the main areas of interest to the book's editor. It is more than 100 pages long and contains a wealth of information on the MR imaging manifestations of pancreatic disease. To round out the abdominal portion of the book, the chapters that follow deal with the gastrointestinal tract and peritoneal cavity, the adrenal gland, kidneys, and retroperitoneum. Although the chapter on the kidneys contains a rather short discussion of MR urography, it is otherwise complete.

The pelvic portion of the book is fairly comprehensive, including individual chapters on the bladder, male pelvis, female urethra and vagina, uterus and



cervix, and adnexa. MR imaging in pregnancy and congenital uterine malformations are well described.

In summary, the book is well organized, and for the most part the text is clearly written. The quality of the printing and illustrations is outstanding. A minor, but recurrent, defect is the frequent lack of correspondence between illustrations and figures and text, which are often placed on different pages; however, once we realize that this is the case, it is a minor distraction. For a book that was published in early 2002, the bibliography is up to date, and even in this rapidly growing field I could not find any major omissions. The book fulfills its purpose and should be available to anyone who is involved in the performance and interpretation of abdominal and pelvic MR imaging studies. Although it is not directly relevant to the neuroradiology audience, it represents an excellent general source of consultation. Because the book has no peer in the English language at this time, I highly recommend it to anyone interested in extending their knowledge in this area of body imaging.