

Are your **MRI contrast agents** cost-effective?

Learn more about generic **Gadolinium-Based Contrast Agents**.



AJNR

**Neuroimaging Clinics of North America.
Volume 12. Diffusion Imaging**

AJNR Am J Neuroradiol 2003, 24 (5) 1026-1027
<http://www.ajnr.org/content/24/5/1026>

This information is current as
of April 17, 2024.

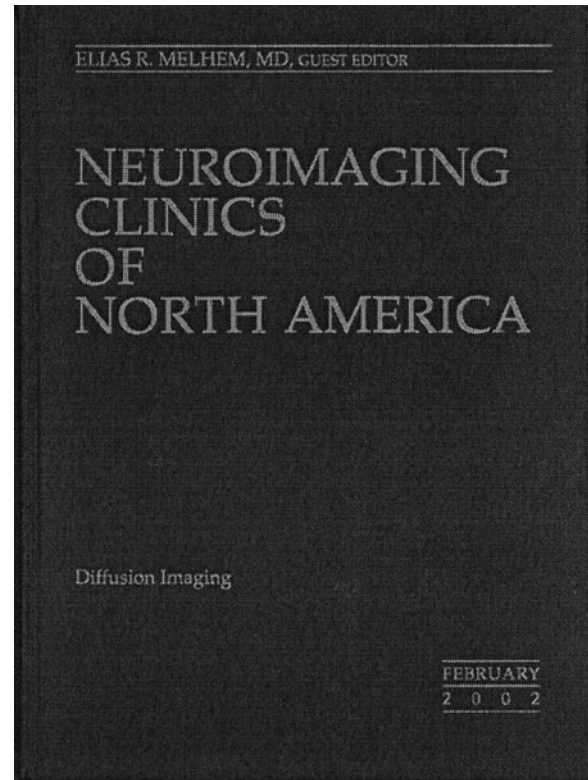
Neuroimaging Clinics of North America. Volume 12. Diffusion Imaging

Elias R. Melhem, ed. Volume 12, Number 1, Philadelphia: WB Saunders. 160 pages, 120 illustrations. \$45.25.

This 160-page volume contains contributions by approximately two dozen authors, some comprehensively describing various schemes of diffusion-weighted acquisition methods, along with image presentation methods of visualizing the white matter fiber tracts by using diffusion tensor (DT) imaging. Throughout the volume, a wide range of clinical applications of diffusion-weighted (DW) imaging in the brain and spine are presented in great detail. The mathematical descriptions of the DW and DT methods have been presented by several contributing authors, which made it cumbersome for this reader. This shortcoming could have been avoided by providing details of the theory of DW and DT imaging and various acquisition methods in one article.

This volume contains eight chapters. The first chapter presents concepts of DT imaging as it relates to isotropic and anisotropic diffusion. The authors use the schematic diagram of an anisotropic diffusion ellipsoid to describe how it can be characterized by six parameters, three of which are the eigenvectors that describe the orientation of the ellipsoid relative to the laboratory frame and the remaining three of which are the eigenvalues that describe the magnitudes of diffusivity along the three orthogonal coordinate axes of the ellipsoid. The authors have discussed the implication of signal intensity to noise on acquisition schemes of the DT data and the measurement accuracy of diffusion coefficients. Advantages and disadvantages of different readout strategies (echo-planar, fast spin-echo, gradient- and spin-echo, line-scan sequences) have been discussed at length, and methods for correction of geometric distortion and image registration are presented. The authors have shown several image presentation methods of white matter fiber tracts that can be derived from the quantitative indices that are generated by DT imaging.

The second chapter discusses use of high b values. The authors show the reversal in contrast between the gray and white matter on DW images at b values of 3500 s/mm^2 compared with those of 1000 s/mm^2 . They discuss the issue of mono- and biexponential decay of the signal intensity on DW images when high b values are used. One explanation for the biexponential signal intensity decay is that the extracellular component of water dominates the signal intensity loss at low b values ($<1000 \text{ s/mm}^2$), and the intracellular component plays a major role in signal intensity loss at high b values. In this chapter, the authors make an interesting observation that this may not be the case, because anisotropy is observed in the white matter at high b values, similar to the anisotropy on DW images acquired at low b values. The authors show that the use of high- b -value DW imaging has a distinct advantage



over conventional DW imaging, because the former improves delineation of diseases and reduces T2 shine-through, which is a major problem with conventional DW imaging.

Several chapters demonstrate the advantages of DW imaging in assessing pathologic conditions. DW imaging has much higher sensitivity for acute stroke as compared with other imaging modalities and differentiates acute stroke from other pathologic conditions. It may provide greater insight into the pathophysiological changes in multiple sclerosis. Diffusion tractography provides accurate depiction of important white matter adjacent to brain tumors. DW imaging may play a major role in assessment of brain maturation between neonates and older children.

The last two chapters deal with DW imaging in other regions of the body. One concentrates on *in vitro* imaging of injured spinal cord of rats. At 1 week post injury, the apparent diffusion coefficient (ADC) values parallel to white matter decreased, whereas the ADC values perpendicular to white matter were close to normal values in the sections rostral and caudal to injury, indicating reduction in anisotropy, whereas no signal intensity changes were observed on conventional T2-weighted images. Microscopy of the fixed cord demonstrated axonal swelling 3–4 mm rostral

and caudal to the site of injury. The authors show that DW imaging is much more sensitive in assessing secondary changes that take place in white matter structures following spinal cord injury as compared with conventional MR imaging.

The final chapter describes several DW acquisition methods that have been developed to overcome problems of physiologic motion in the body. DW imaging was performed on skeletal muscles of patients with claudication caused by arteriosclerosis before and after exercise. DW data showed correlation between claudication and diffusion values. DW imaging has been used to assess musculoskeletal tumors and effusion in knee joints and associated changes in marrow and to differentiate acute benign and malignant vertebral compression fractures. In all the studies represented in this volume, DW imaging is shown to provide higher specificity and sensitivity as compared with conventional imaging techniques.

In summary, this volume presents an impressive collection of different DW imaging acquisition methods, along with their advantages and disadvantages. The newer methods such as DT imaging have been applied in the clinical setting. Also, the image maps generated from the quantitative indices of DT imaging, such as fractional anisotropy, relative anisotropy, color trace, and diffusion tractography, have been used to show changes in diseased white matter structures. These advanced image acquisition and display methods when applied in the clinical realm will further aid radiologists in making accurate diagnoses. Other acquisition schemes for DT imaging, such as tetrahedral and super DT imaging, that will further aid clinicians in understanding and determining the pathophysiologic changes that occur in tissue following trauma, disease, and response to therapy are being investigated by researchers.