

Are your **MRI contrast agents** cost-effective?

Learn more about generic **Gadolinium-Based Contrast Agents**.



**FRESENIUS
KABI**

caring for life

AJNR

**Neurosurgery of Arteriovenous
Malformations and Fistulas: A Multimodal
Approach**

AJNR Am J Neuroradiol 2003, 24 (8) 1722-1723

<http://www.ajnr.org/content/24/8/1722>

This information is current as
of April 19, 2024.

Neurosurgery of Arteriovenous Malformations and Fistulas: A Multimodal Approach

Hans-Jakob Steiger, Robert Schmid-Elsaesser, Alexander Muacevic, Hartmut Brückmann, and Berndt Wowra. Vienna and New York: Springer-Verlag. 473 pages, 617 illustrations.

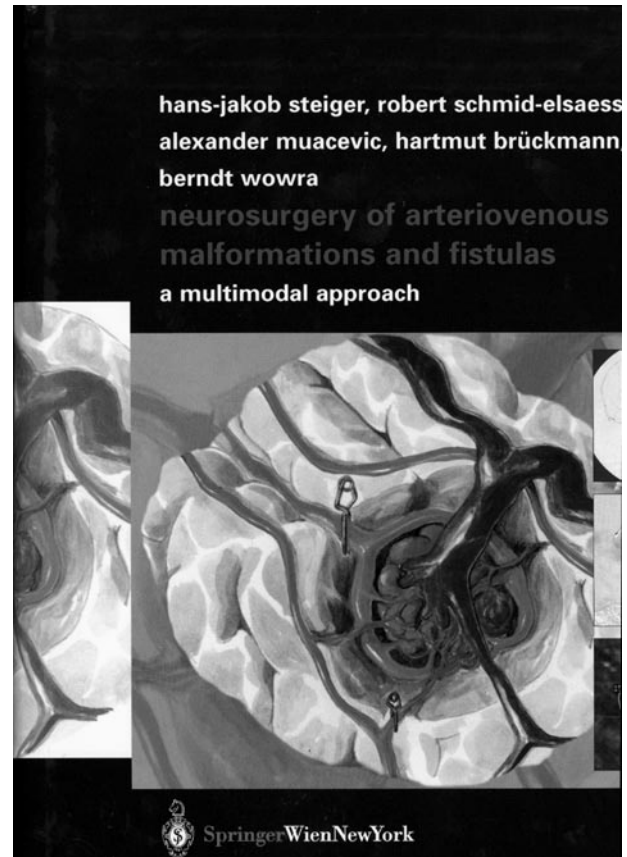
Arteriovenous malformations (AVMs) and dural arteriovenous fistulas (DAVFs) of the brain and spinal cord are among the most difficult and complex lesions to treat and pose a significant challenge to neurosurgeons and neurointerventionalists who deal with these lesions in everyday practice. The authors, a group of clinicians from Munich, Germany, with diverse experience in the management of these vascular lesions, have taken this challenge and in this book share their expertise with readers.

The book is divided into six major chapters and concludes with case illustrations for each treatment technique, namely, surgery, endovascular embolization, and radiosurgery. The first chapter begins with general considerations about AVMs of the brain and of the spinal cord and DAVFs and reviews the pertinent literature. The review is exhaustive and comprehensive; no matter how small, no publication is neglected. The bibliography includes 855 references for this chapter alone.

The second chapter covers the classification of AVMs and DAVFs from different perspectives: pathologic, anatomic, surgical, and topographic. It also reviews the angioarchitecture of these lesions. Again in this chapter, the literature review is phenomenally detailed.

The third chapter exposes the published management outcomes of surgery, embolization, and radiosurgery as well as those obtained with combined treatment modalities. The chapters that follow address the principles of surgical, endovascular, and radiosurgical treatment modalities. Surgical techniques and approaches to lesions in various locations are satisfactorily covered. Surgical principles are covered according to location of the lesion, which is divided into convexity (frontal, Rolandic, parietal, occipital, temporal, and Sylvian), interhemispheric (anterior and posterior callosal and paracallosal), basal ganglia and thalamus, ventricular, cerebellar, and brain stem AVMs. For each location, appropriate surgical approaches are given.

The case illustrations given in the last three chapters include presentations of the cases, planned treatment techniques, and discussions. Each case was enriched with plenty of radiologic and schematic drawings. Some of the cases discussed in these chapters may be treated differently by other neurosurgeons. For example, the authors describe a patient (case S-1) with Spetzler-Martin grade III AVM in the nondominant frontal lobe. This patient presented with seizures and underwent embolization before surgery or radiosurgery. During the third session of endovascular embolization, the AVM ruptured, resulting in a large intracerebral hematoma (ICH). Evacuation



of the ICH and excision of the AVM were undertaken emergently, and the patient eventually made a good recovery. In the management of this particular case, we would personally follow a different course of action. First, with this location, size, and deep drainage (Spetzler-Martin grade III), we would not consider radiosurgery as a treatment alternative, because, at best, stereotactic radiosurgery leads to complete angiographic obliteration in about 70–80% of lesions with a diameter of less than 3 cm at 2–3 years after treatment. Moreover, patients will remain at risk for hemorrhage until the AVM is completely obliterated, and this risk appears to be the same as the risk of hemorrhage in untreated AVMs.

Total microsurgical excision of an AVM is the ideal method of treatment because it achieves the goal of AVM treatment, which is to eliminate the risk of hemorrhage immediately and permanently. In addition, it may also provide improvement in neurologic function and a reduction in the incidence of seizures. There are considerable data on immediate and long-term outcome after microsurgical excision of AVMs. The morbidity and mortality is minimal for patients

with Spetzler-Martin grades I and II AVMs and acceptably low for patients with grade III AVMs. With higher grades (IV and V), however, morbidity and mortality rates with surgical excision significantly increase. In a series of 176 patients who underwent microsurgical excision of their AVMs, Heros and Korosue, for example, reported 0% serious morbidity or mortality in grade I AVMs and 100% of patients had excellent or good outcome, whereas 95% of patients with grade II AVMs had excellent or good outcome without mortality. In grade III patients, they achieved excellent or good outcome in 88.2% of cases, with 2% poor outcome and 2% mortality. Morbidity and mortality rates were 12.2% in grade IV and 38.4% in grade V patients. In the study by Hamilton and Spetzler in which Spetzler-Martin grading was applied prospectively in 120 patients, serious permanent neurologic morbidity was reported as 0% in grades I-III, and 21.9% and 16.7% in grades IV and V, respectively.

Second, we prefer endovascular embolization in cases where it is advantageous to limit a multiangle dissection of the AVM and thus decrease brain manipulation in eloquent areas. For this reason, we are in full agreement with the authors about the management of another case (case S-2). As opposed to case S-1, the authors decided to perform preoperative em-

bolization for this relatively small AVM located in the right frontobasal lobe with close relation to hypothalamic structures. In this case, we would definitely prefer preoperative embolization to keep surgical dissection at minimum near the hypothalamus as did the authors.

Another important point is that even in experienced hands embolization of AVMs carries significant morbidity and mortality. Deruty et al reported 25% overall morbidity and 8% mortality rates. In the study by Wickholm et al, embolization resulted in severe complications in 6.6%, moderate complications in 15.3%, and mild complications in 17.3% of 150 patients.

Overall, this book is an important reference source for physicians dealing with AVMs and DAVFs of the central nervous system. The comprehensive literature review on all topics covered in the chapters is unique and alone makes the purchase worthwhile. This is notwithstanding the fact that medical technology is a continuously moving target and passage of time may make certain therapeutic techniques relatively obsolete. The book should appeal to general and cerebrovascular surgeons, interventionalists, and stroke neurologists as well as trainees in the cerebrovascular neurosciences at all level.