

Are your **MRI contrast agents** cost-effective?

Learn more about generic **Gadolinium-Based Contrast Agents**.



AJNR

Successful Revascularization of Acute Carotid Stent Thrombosis by Facilitated Thrombolysis

Sabine Steiner-Böcker, Manfred Cejna, Christian Nasel, Erich Minar and Christoph W. Kopp

This information is current as of April 17, 2024.

AJNR Am J Neuroradiol 2004, 25 (8) 1411-1413
<http://www.ajnr.org/content/25/8/1411>

Successful Revascularization of Acute Carotid Stent Thrombosis by Facilitated Thrombolysis

Sabine Steiner-Böcker, Manfred Cejna, Christian Nasel, Erich Minar, and Christoph W. Kopp

Summary: A 64-year-old woman undergoing protected carotid artery stent placement developed acute stent thrombosis despite pretreatment with combined antiplatelet therapy. A reduced dose of recombinant tissue plasminogen activator and a half-dose bolus of abciximab were administered intra-arterially via superselective catheterization followed by systemic intravenous infusion of abciximab for 12 hours. Control angiography showed complete restoration of blood flow paralleled by neurologic improvement.

In carotid stent placement, periprocedural complications include transient or permanent neurologic deficit due to distal thrombus embolization. Two measures are taken to reduce this risk: 1) a well-established antithrombotic regimen that combines antiplatelet premedication and periprocedural heparin to control thrombogenesis (1), and 2) routine use of distal embolic protection devices (2). Technical success with minimal residual stenosis is reported in most series, and acute stent thrombosis is an extremely rare event (2).

Herein we report one case of acute stent thrombosis during filter protected carotid stent placement despite combined antiplatelet therapy with aspirin and clopidogrel, as well as peri-interventional use of heparin. Combined thrombolysis and dethrombolysis (3, 4)—so-called facilitated thrombolysis—led to rapid arterial recanalization with minor peri-interventional clinical symptoms.

Case Report

A 64-year-old woman presented with an asymptomatic, calcified, 90% stenosis with rapid progression of the right internal carotid artery (ICA) as judged by velocity criteria by using duplex sonography and a concomitant contralateral 70% ICA stenosis.

After placement of the vascular access sheath, 5000 IU of unfractionated heparin (UFH) were administered intra-arterially. The cerebral angiogram in two planes revealed 85% stenosis of the ICA according to NASCET criteria (5) with no major irregularities or visible appositional thrombus (Fig 1A). A FilterWire EX (Boston Scientific) was placed in the distal

right ICA to provide distal embolic protection. A self-expandable 7 × 30 mm Wallstent (Boston Scientific, Natick, MA) was deployed by monorail technique across the stenosis and single poststent dilation was performed with an Agiltrac balloon catheter (5.5 × 30 mm, Guidant, Indianapolis, IN). The patient received 1 mg Atropin intravenously before stent deflation to control potential bradycardia and hypotension due to vasovagal stimulation by compression of the glomus caroticus. A control angiogram obtained immediately after balloon deflation with the protective device in place showed complete occlusion of the right carotid artery within the stent and thrombotic masses surrounded by contrast medium (Fig 1B). Peri-interventional neurologic deficit consisted of mild left facial paresis and dysarthria. Intracarotid injection of 5 mg rtPA was followed by 5 mg recombinant tissue plasminogen activator (rtPA) intra-arterially via the inguinal sheath and a half-dose bolus of abciximab (0.125 mg/kg) via the intracarotid guiding catheter within 9 minutes. Additional heparin (3000 IU) was administered to raise the activated clotting time from <250 to 276 seconds during the prolonged procedure. Carotid recanalization with completely restored blood flow was achieved within 15 minutes of visible onset of acute stent thrombosis (Fig 1C). Moderate vasospasm distal to the segment treated with a stent was observed without visible flow impairment; no further treatment was required. After complete restoration of blood flow, the filter device was removed. Intravenous abciximab therapy was continued for 12 hours at standard dose (0.125 $\mu\text{g}\cdot\text{kg}^{-1}\cdot\text{min}^{-1}$).

Initial MR imaging showed small perfusion deficits within the right precentral gyrus. Control MR imaging after 48 hours confirmed reduced de novo ischemic lesions. Neurologic complications completely resolved within 24 hours, and the patient was discharged 48 hours after intervention with combined antiplatelet therapy for 4 weeks.

Discussion

Acute or subacute thrombosis in carotid stent placement is a rare complication previously described only in patients without combined antiplatelet therapy due to omission of an ADP-receptor antagonist (6, 7). In our patient, the reason for acute stent thrombosis remained obscure, because the standard antithrombotic regimen, including combined antiplatelet therapy, was administered and the intervention was performed in a routine fashion by using monorail technique and distal filter protection without repeat poststent dilation or any evidence of dissection. Routine laboratory parameters including prothrombin time, activated partial thromboplastin time, platelet count, and C-reactive protein at baseline were within the normal range; however, poorly controlled diabetes indicated by an elevated level of glycated hemoglobin (HbA1c 7.6 rel%) may have predisposed to a hypercoagulable state in this patient (8).

Peri-interventional carotid stent thrombosis re-

Received October 13, 2003; accepted after revision January 5, 2004.

From the Second Department of Medicine (S.S.-B., E.M., C.W.K.) and the Department of Radiology (C.N.), University of Vienna Medical School, Vienna, Austria

Address correspondence to Christoph W. Kopp, MD, Second Department of Medicine, Division of Angiology, University of Vienna Medical School, Waehringer Guertel 18–20, 1090 Vienna, Austria.

© American Society of Neuroradiology

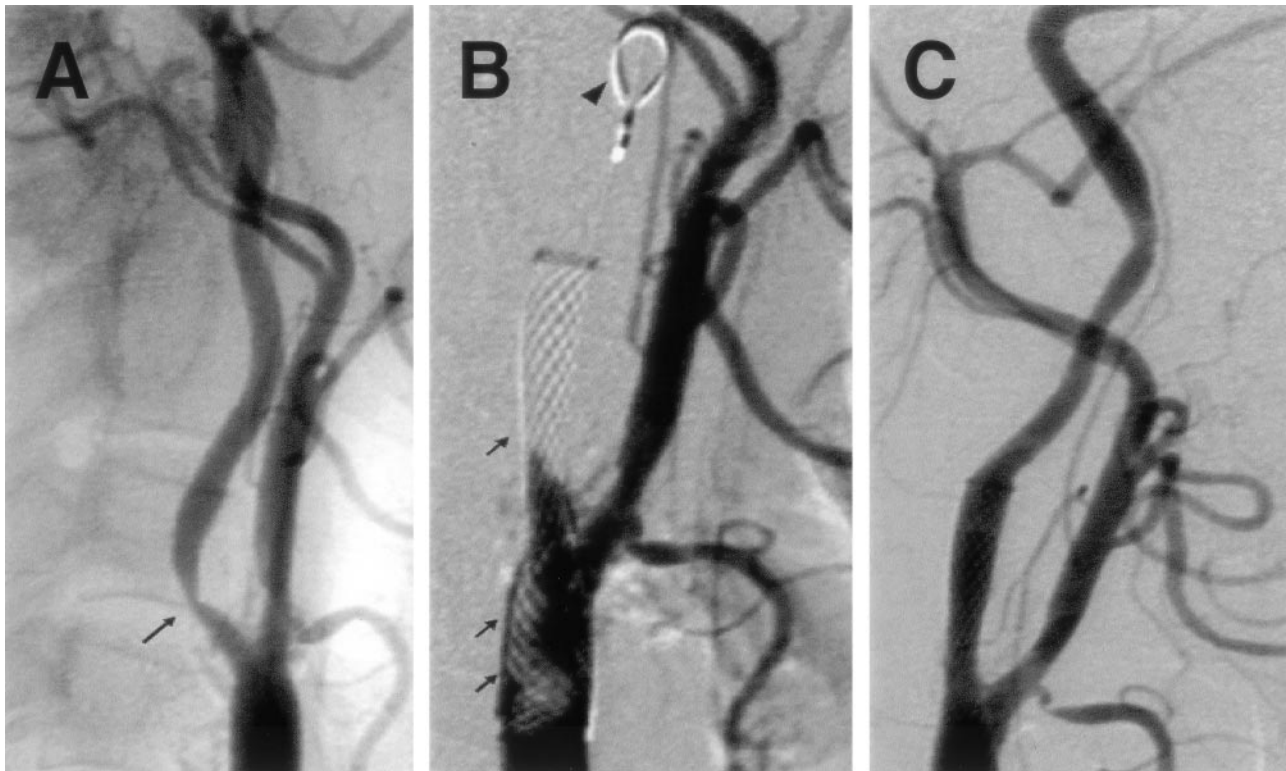


FIG 1. Resolution of acute carotid stent thrombosis by combined administration of rtPA and abciximab.

A, Digital subtraction angiogram obtained before intervention. Arrow indicates 85% stenosis of the right proximal ICA.

B, Small arrows indicate thrombus formation within the proximal stented segment and total thrombotic occlusion of the distal stented segment. Filter WilterEx protection device in situ in the distal ICA (arrowhead).

C, Restoration of blood flow with moderate residual vasospasm distal of the stented segment after successful combined thrombolysis.

quires (ideally) rapid intra-arterial–intracarotid initiation of reperfusion therapy to limit time of ischemia, reperfusion injury, and associated symptomatic intracranial hemorrhage (9). Thrombolysis with rtPA is the only thrombolytic therapy approved for the treatment of acute ischemic stroke (10). Its major limitations, however, consist of the high incidence of intracranial bleeding complications and the short time window for application within 3 hours from onset of symptoms. In addition, for the treatment of peri-interventional thrombotic events in neuroendovascular procedures, rtPA did not significantly improve recanalization rates and clinical outcome (11).

By contrast, early thrombus disaggregation—termed “dethrombolysis” (3)—by using the GP IIb/IIIa inhibitor abciximab as adjunct for carotid artery stent placement reportedly reduced adverse peri-interventional events (12, 13). Furthermore, abciximab for treatment of acute ischemic stroke proved safe and efficient with a positive trend toward a higher rate of minimal residual neurologic disability after 3 months (14).

A combined therapeutic regimen consisting of dethrombolysis (abciximab) and fibrinolysis (by using alteplase)—termed “facilitated thrombolysis”—was studied in acute myocardial infarction (MI) (15) and was also reported in selected cases of acute basilar artery occlusion (16). Because of the increased bleeding risk observed with abciximab after full-dose thrombolysis in rescue or urgent angioplasty for acute

MI, (17) study protocols for facilitated thrombolysis employing a lytic agent in combination with a GP IIb/IIIa antagonist were designed with half the usual dose of the fibrinolytic agent (15). Similarly, rtPA in a reduced dosage of only 10 mg/h (for a total of 2 hours) was given intra-arterially together with full-dose (bolus and infusion) intravenous abciximab for recanalization of acute basilar artery occlusion (16).

In our patient, both rtPA and the half-bolus abciximab were administered intra-arterially via superselective catheterization of the occluded carotid artery. This strategy ensures high local drug concentration associated with improved efficacy (18, 19). Therefore, a reduced dosage of both agents was used employing a careful “wait and watch” tactic; however, because fibrinolytic agents simultaneously exert clot-dissolving and procoagulant actions, which may in fact precipitate reocclusion of the infarct-related artery after thrombolysis (20), we decided to perform facilitated thrombolysis by using rtPA and abciximab simultaneously, rather than fibrinolysis alone.

Heparin was used to titrate the activated clotting time between 250 and 280 seconds, which is recommended for adjunct abciximab therapy. We doubt that UFH by itself had a prothrombotic effect in our patient, although it was previously shown to induce platelet P-selectin expression, to increase platelet surface bound fibrinogen and to significantly augment ADP-dependent platelet activation, when compared with low-molecular-weight heparin (21). These data

were derived from whole blood flow cytometry and platelet aggregation assays. Whole blood flow cytometry performed in our patient showed postinterventional P-selectin expression on platelet-monocyte aggregates, a marker known to be more sensitive than direct platelet P-selectin expression (22), that was comparable to the baseline level (pre 22.3% versus post 22.2% P-selectin-positive monocyte-platelet aggregates). This result, however, was not unexpected because of the suppressive effect of abciximab on the platelet load of individual monocytes previously described in in vitro (23) and in vivo (13) models.

The emergency situation of peri-interventional acute carotid stent thrombosis seems particularly suitable for facilitated thrombolysis (4), because the time window of ischemia is minimal (which is a determinant of reperfusion injury and associated bleeding risk), and the freshly formed thrombus may be prone to dethrombosis (3). Thus, coadministration of abciximab and rTPA may be beneficial with respect to both reduced time for arterial recanalization and suppression of recurrent thrombosis.

Conclusion

In our case, the bailout strategy by using the synergistic effect of thrombolysis and dethrombosis led to rapid revascularization after carotid stent thrombosis with minimal de novo ischemic lesion formation and transient neurologic deficit.

References

1. Moussa I, Gishel N, Lawrence E, et al. Clopidogrel may enhance the clinical efficacy of carotid artery stent implantation: the EMILY registry. *Stroke* 2000;31:299
2. Wholey MH, Wholey M. Current status in cervical carotid artery stent placement. *J Cardiovasc Surg* 2003;44:331-339
3. Marciniak SJ Jr, Mascelli MA, Furman MI, et al. An additional mechanism of action of abciximab: dispersal of newly formed platelet aggregates. *Thromb Haemost* 2002;87:1020-1025
4. Luciarci H, Berman S, Muntaner J, et al. Facilitated thrombolysis: dethrombosis? *Clin Appl Thromb Hemost* 2002;8:133-138
5. North American Symptomatic Carotid Endarterectomy Collaborators. Beneficial effect of carotid endarterectomy in symptomatic patients with high-grade carotid stenosis. *N Engl J Med* 1991;325:445-453
6. Tong FC, Cloft HJ, Joseph JJ, et al. Abciximab rescue in acute carotid stent thrombosis. *AJNR Am J Neuroradiol* 2000;21:1750-1752
7. Chaturvedi S, Sohrab S, Tselis A. Carotid stent thrombosis: report of 2 fatal cases. *Stroke* 2001;32:2700-2702
8. Juhan-Vague I, Alessi MC, Vague P. Thrombogenic and fibrinolytic factors and cardiovascular risk in non-insulin-dependent diabetes mellitus. *Ann Med* 1996;28:371-380
9. Molina CA, Alvarez-Sabin J, Montaner J, et al. Thrombolysis-related hemorrhagic infarction: a marker of early reperfusion, reduced infarct size, and improved outcome in patients with proximal middle cerebral artery occlusion. *Stroke* 2002;33:1551-1556
10. The National Institute of Neurological Disorders and Stroke rt-PA Stroke Study Group. Tissue plasminogen activator for acute ischemic stroke. *N Engl J Med* 1995;333:1581-1587
11. Hahnel S, Schellinger PD, Gutschalk A, et al. Local intra-arterial fibrinolysis of thromboemboli occurring during neuroendovascular procedures with recombinant tissue plasminogen activator. *Stroke* 2003;34:1723-1728
12. Kapadia SR, Bajzer CT, Ziada KM, et al. Initial experience of platelet glycoprotein IIb/IIIa inhibition with abciximab during carotid stenting: a safe and effective adjunctive therapy. *Stroke* 2001;32:2328-2332
13. Kopp CW, Steiner S, Nasel C, et al. Abciximab reduces monocyte tissue factor in carotid angioplasty and stenting. *Stroke* 2003;34:2560-2567
14. The Abciximab in Ischemic Stroke Investigators. Abciximab in acute ischemic stroke: a randomized, double-blind, placebo-controlled, dose-escalation study. *Stroke* 2000;31:601-609
15. Antman EM, Giugliano RP, Gibson CM, et al. Abciximab facilitates the rate and extent of thrombolysis: results of the thrombolysis in myocardial infarction (TIMI) 14 trial: the TIMI 14 Investigators. *Circulation* 1999;99:2720-2732
16. Eckert B, Koch C, Thomalla G, et al. Acute basilar artery occlusion treated with combined intravenous abciximab and intra-arterial tissue plasminogen activator: report of 3 cases. *Stroke* 2002;33:1424-1427
17. Joung P, Cohen EA, Batchelor W, et al. Bleeding risk with abciximab after full-dose thrombolysis in rescue or urgent angioplasty for acute myocardial infarction. *Am Heart J* 2001;141:218-225
18. Wohrle J, Grebe OC, Nusser T, et al. Reduction of major adverse cardiac events with intracoronary compared with intravenous bolus application of abciximab in patients with acute myocardial infarction or unstable angina undergoing coronary angioplasty. *Circulation* 2003;107:1840-1843
19. Qureshi AI, Siddiqui AM, Suri MFK, et al. Aggressive mechanical clot disruption and low dose intra-arterial third-generation thrombolytic agent for ischemic stroke: a prospective study. *Neurosurgery* 2002;51:1319-1329
20. Hoffmeister HM, Szabo S, Kastner C, et al. Thrombolytic therapy in acute myocardial infarction: comparison of procoagulant effects of streptokinase and alteplase regimens with focus on the kallikrein system and plasmin. *Circulation* 1998;98:2527-2533
21. Klein B, Faridi A, von Temelhoff GF, et al. A whole blood flow cytometric determination of platelet activation by unfractionated and low molecular weight heparin in vitro. *Thromb Res* 2003;108:291-296
22. Furman MI, Barnard MR, Krueger LA, et al. Circulating monocyte-platelet aggregates are an early marker of acute myocardial infarction. *J Am Coll Cardiol* 2001;38:1002-1006
23. Steiner S, Seidinger O, Huber K, et al. Effect of glycoprotein IIb/IIIa antagonist abciximab on monocyte-platelet aggregates and tissue factor expression. *Arterioscler Thromb Vasc Biol* 2003;23:1697-1702.