

Errata

Due to an author oversight, Claudia Furtado, was misspelled in the published list of authors for two articles in the October 2004 issue. The correct citation for those articles should be:

McComb JG, Bradley, Jr. WG, Safar FG, Furtado C, Ord J and Alksne JF. **Is a Large Hat Size Hazardous to Your Health?** *AJNR Am J Neuroradiol* 2004;25:1454–1455; and

Bradley WG, Safar FG, Furtado C, Ord J and Alksne JF. **Increased Intracranial Volume: A Clue to the Etiology of Idiopathic Normal-Pressure Hydrocephalus?** *AJNR Am J Neuroradiol* 2004;25:1479–1484.

In the article **Blood Brain-Barrier Disruption of Nonionic Iodinated Contrast Medium Following Coil Embolization of a Ruptured Intracerebral Aneurysm**, *AJNR* 25:1783–1786, November/December 2004, the figures were incorrectly labeled. The correct figures and layouts are as follows:

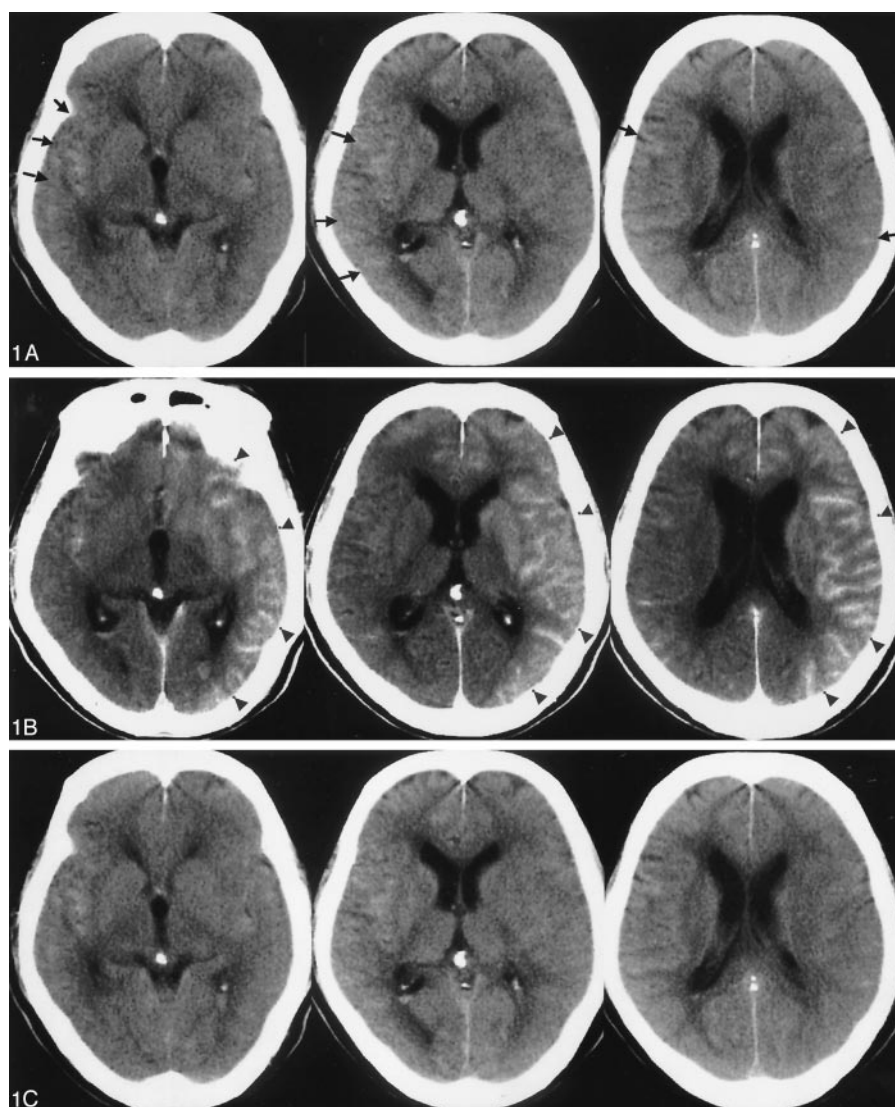


FIG 1. A 72-year-old man presented with subarachnoid hemorrhage secondary to a ruptured anterior communicating artery complex aneurysm. The patient underwent primary endovascular coil treatment of the aneurysm to occlusion.

A, Pretreatment CT scan showing hyperattenuated area mainly in the right Sylvian fissure (arrow).

B, Postprocedural CT scan, obtained 1 hour after the procedure, demonstrating extensive gyriform enhancement of the cerebral cortex, significantly greater on the left (arrowhead).

C, Follow-up CT scan, obtained 11 hours after the procedure, demonstrates resolution of the previously demonstrated gyriform cortical enhancement, with only slight diffuse vasogenic edema shown in the left cortical mantle.

For the articles **CT Fluoroscopy–Guided Epidural Injections: Technique and Results**, AJRN 25:1821–1823, November/December 2004 and **Gadolinium Diskography**, AJNR 25:1824–1827, November/December 2004, the correct contact information for the corresponding author's is Andrew L. Wagner, MD, Department of Radiology, Rockingham Memorial Hospital, 235 Cantrell Avenue, Harrisonburg, VA 22801.