

**Are your MRI contrast agents cost-effective?**

Learn more about generic Gadolinium-Based Contrast Agents.



**FRESENIUS  
KABI**

caring for life

**AJNR**

**Regional Cerebral Blood Flow After  
Acetazolamide Challenge in Patients with  
Dural Arteriovenous Fistula: Simple Way to  
Evaluate Intracranial Venous Hypertension**

Jun Deguchi, Makoto Yamada, Hitoshi Kobata and  
Toshihiko Kuroiwa

This information is current as  
of April 19, 2024.

*AJNR Am J Neuroradiol* 2005, 26 (5) 1101-1106  
<http://www.ajnr.org/content/26/5/1101>

# Regional Cerebral Blood Flow After Acetazolamide Challenge in Patients with Dural Arteriovenous Fistula: Simple Way to Evaluate Intracranial Venous Hypertension

Jun Deguchi, Makoto Yamada, Hitoshi Kobata, and Toshihiko Kuroiwa

**BACKGROUND AND PURPOSE:** Because venous hypertension determines the clinical severity of dural arteriovenous fistulas (DAVFs), evaluation of intracranial venous pressure is important in making decisions concerning treatment. We determined whether intracranial venous hypertension could be quantified by using an acetazolamide test in a manner that indicates whether treatment of the DAVF is necessary.

**METHODS:** We enrolled 21 untreated patients: 11 with a sigmoid and/or transverse DAVF, six with a cavernous DAVF, two with an anterior cranial fossa DAVF, and two with a superior sagittal sinus DAVF. Cerebral hemodynamics were studied with stable-xenon CT. Patients were angiographically classified into three groups, and regional cerebral blood flow (rCBF) after acetazolamide challenge was compared between angiographic groups, between patients with and those without symptoms attributable to intracranial venous hypertension, and between preembolization and postembolization examinations.

**RESULTS:** A high angiographic grade was associated with decreased resting rCBF and a blunted response to acetazolamide. Response to acetazolamide was more sensitive to venous hypertension, as angiographically assessed, than decreased resting rCBF. Resting rCBF and the increase in rCBF associated with acetazolamide were significantly lower in the symptomatic group than in the asymptomatic group. Treatment of the DAVF significantly enhanced the increased rCBF due to the acetazolamide challenge.

**CONCLUSION:** Cerebral venous hypertension in DAVF reduced the response to acetazolamide, as shown on stable-Xe CT. Therefore, a patient with DAVF and a reduced rCBF response to acetazolamide requires treatment irrespective of his or her symptoms.

In patients with dural arteriovenous fistula (DAVF), the severity of symptoms can range from benign tinnitus to coma. Factors predisposing the patient to an aggressive neurologic course are retrograde leptomeningeal venous drainage, a venous varix, and galenic venous drainage (1). In particular, venous hypertension is generally recognized to determine the clinical presentation of patients with a cranial DAVF (2–4). Many classification systems based on the angiographic appearance of the lesion and the mode of venous drainage have been proposed (5–7), but all are based on the presence or absence of venous reflux rather than a quantitative assessment of congestion or

venous hypertension. Indeed, venous hypertension in DAVF is seldom examined quantitatively (8).

A carbonic anhydrase inhibitor, acetazolamide is a potent dilator of cerebral arterioles. Because of its vasodilating effect, acetazolamide has been used to evaluate cerebral vascular reserve capacity (9–11). Because venous hypertension decreases the pressure gradient between cerebral arteries and veins, we hypothesized that venous hypertension blunts the increase in regional cerebral blood flow (rCBF) in response to acetazolamide. Accordingly, we quantitatively assessed cerebral venous hypertension by using an acetazolamide test.

## Methods

Twenty-one consecutive patients with DAVF (11 men and 10 women; mean age, 64.3 years; age range, 33–85 years) who consented to undergo stable-xenon CT were examined between January 1997 and March 2003. All patients gave informed consent, and the ethics committee at our institution approved the study. Table 1 shows the patients' symptoms.

Received March 11, 2004; accepted after revision September 24.  
From the Department of Neurosurgery (J.D., M.Y., H.K., T.K.), Osaka Medical College, Japan.

Address correspondence to Jun Deguchi, MD, Department of Neurosurgery, Osaka Medical College, 2-7 Daigaku-cho Takatsuki-shi Osaka, Japan 569-8686.

TABLE 1: Clinical summary of patients

Patient/Age (y)/Sex	Cognard Classification	Affected Sinus	Symptom		Treatment*
			Description	Due to Venous Hypertension?	
1/75/M	I	R sigmoid	Tinnitus	No	TAE
2/54/M	I	Superior sagittal sinus	Bulging scalp vessels	No	TAE
3/78/F	I	Superior sagittal sinus	Aneurysm-like STA dilatation	No	None
4/54/F	I	L cavernous	None	NA	None
5/58/M	I	R cavernous	Chemosis, diplopia	No	None
6/73/M	I	L cavernous	Diplopia	No	None
7/75/F	I	L cavernous	Chemosis	No	TVE
8/62/M	IIa	L sigmoid	Tinnitus	No	TAE, TVE
9/75/M	IIa	R transverse sigmoid	None	NA	None
10/33/M	IIb	L transverse sigmoid	Headache, tinnitus	Yes	TAE, TVE
11/66/F	IIb	L cavernous	Diplopia, disorientation	Yes	TVE
12/85/F	IIb	L cavernous	Chemosis, diplopia	No	TAE
13/33/F	IIa+b	R transverse sigmoid	Headache, visual disturbance	Yes	TAE
14/54/F	IIa+b	L transverse sigmoid	Dementia	Yes	TAE, TVE
15/55/M	III	L transverse sigmoid	Hemorrhage, vertigo, convulsion	Yes	TAE, TVE
16/63/M	III	R transverse sigmoid	Hemorrhage	Yes	TAE
17/67/M	III	R transverse confluence	L lower quadrant homonymous anopsia	Yes	TAE, TVE
18/72/F	III	L transverse confluence	Dementia	Yes	TVE
19/78/F	III	L transverse	Convulsion, disturbed consciousness	Yes	TAE
20/67/M	IV	L anterior fossa	Convulsion	Yes	Surgery
21/74/M	IV	R anterior fossa	None	NA	Surgery

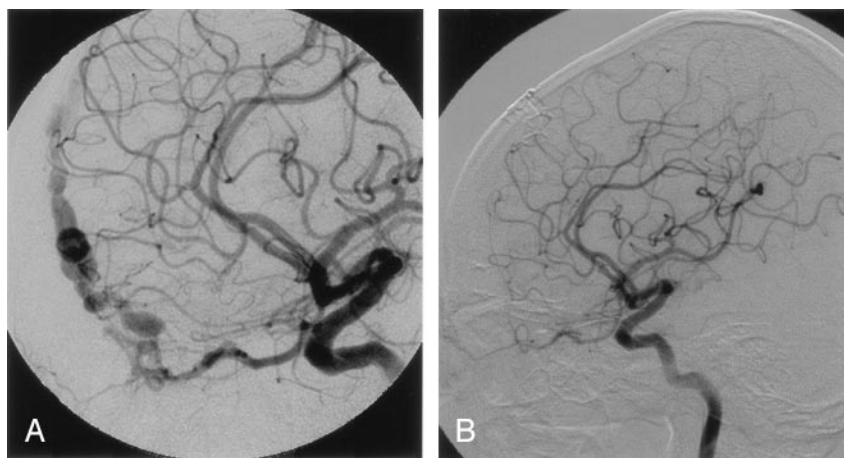
Note.—NA = Not applicable, STA = superficial temporal artery, TAE = transarterial embolization, TAV = transvenous embolization.

\* All patients improved except for patients 3 and 12, whose condition was unchanged.

FIG 1. Case 21. Right lateral internal carotid angiograms show a Cognard type IV lesion in an asymptomatic patient.

A, Preoperative image shows an anterior fossa DAVF with cortical venous reflux.

B, Postoperative image shows disappearance of the DAVF and venous reflux.



Xe CT assessment was performed by using a rebreathing system (Xetron-I; Anzai-Sogyo, Tokyo, Japan) and a CT scanner (X-Vigor; Toshiba, Tokyo, Japan). Specific conditions were an Xe concentration of 30 vol%, an oxygen concentration of 30 vol%, and combined wash-in/wash-out measurements of 4 minutes each, with one CT section obtained per minute. Each Xe CT procedure included one measurement at rest and another after challenge with acetazolamide (Diamox; Sanwa-kagaku, Nagoya, Japan). This pharmacologic maneuver revealed the patient's cerebrovascular reserve capacity by causing intense cerebral vasodilation. As a rule, the study was performed shortly before intervention (within 7 days) and repeated 6 months after intervention. A single brain section was studied. When possible, this section was at the level of the basal ganglia or at the body of the lateral ventricle.

On each CT image obtained for the measurement of blood flow, a region of interest (ROI) was drawn to reflect mean rCBF in a broad area (Figs 1 and 2). In cases of a cavernous or anterior fossa DAVF, the ROI was placed to include the entire

outer surface of the frontal lobe anterior to the sylvian fissure. In cases of a transverse and/or sigmoid DAVF, the ROI was placed to enclose the outer surface of the temporo-occipital region posterior to the superior temporal sulcus on the CT section that included the pineal gland. In cases of a superior sagittal sinus DAVF, the ROI was placed to enclose the gray matter from the superior frontal sulcus to the postcentral sulcus on the CT section that included the body of the lateral ventricle. rCBF was measured in the ROI at rest and after acetazolamide challenge. In cases of bilateral DAVFs, the lesion side was defined as the side on which more arteriovenous shunt surgery had been performed. ROIs were placed and rCBF was measured by one author (M.Y.) who was aware of the location and side of each DAVF but blinded to the clinical and angiographic data.

Patients were divided into two groups according to their symptoms of venous hypertension. In the symptomatic group, manifestations included disturbed consciousness, headache, papilledema, convulsions, and intracranial hemorrhage (12). In

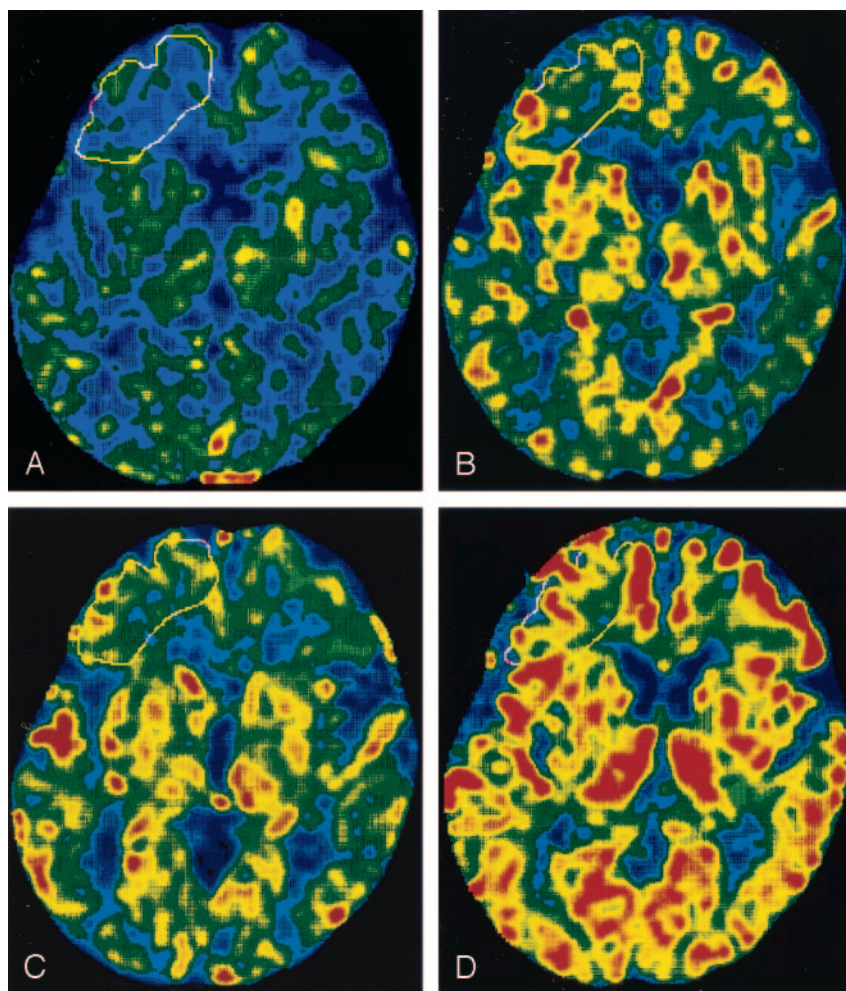


FIG 2. Case 21. rCBF maps for a Cognard type IV lesion in an asymptomatic patient.

A and B, Before surgery, resting rCBF in the right frontal region (white outline) is low (A), and the response of rCBF to the acetazolamide challenge is limited (B).

C and D, At 6 months after surgery, resting rCBF (C) and the response of rCBF (D) to the acetazolamide challenge is increased.

the asymptomatic group, patients had no clinical manifestations of venous hypertension, but they may have had symptoms due to the arteriovenous shunt surgery itself, such as tinnitus, chemosis, or oculomotor palsy.

Statistical analysis was performed by using the Scheffé  $F$  method after the Friedman test to detect differences between angiographic groups. The Mann-Whitney  $U$  test was used to detect differences between symptomatic and asymptomatic groups. The Wilcoxon signed-rank test was applied to detect differences between tests performed before treatment and those performed after treatment. Differences were considered significant when  $P$  was less than .05. Values are presented as the mean  $\pm$  standard deviation.

## Results

Using Cognard classification (6), we assigned the DAVFs to one of three angiographic groups, with subgroups: type I was antegrade venous drainage (seven patients); type IIa, retrograde venous drainage into only a sinus (two patients); type IIb, retrograde venous drainage into only a cortical vein (three patients); type IIa+b, retrograde venous drainage into a sinus and a cortical vein (two patients); and type III and IV, direct drainage into a cortical vein (seven patients).

Resting rCBF was significantly less in type III and IV than in type I ( $P < .005$ ), whereas rCBF did not

differ between type I and type II (Fig 3A). However, rCBF after acetazolamide challenge and the increase in rCBF associated with acetazolamide challenge ( $\Delta F$ ) were significantly less in type II than in type I (Fig 3B and C). Therefore, rCBF after acetazolamide challenge and  $\Delta F$  were more sensitive than resting rCBF to impaired venous drainage.

Although symptomatic and asymptomatic patients did not differ in age ( $P = .11$ ), resting rCBF, rCBF after acetazolamide, and  $\Delta F$  were significantly lower in the symptomatic group than in the asymptomatic group ( $P < .01$ ) (Table 2).

Embolization or surgical resection was performed in 16 patients; in 14, the DAVF was obliterated by 6 months after treatment. In the other two patients (patients 1 and 12), shunt flow through the DAVF was reduced, as shown on angiography performed 6 months after embolization. In patients 2 and 7, follow-up Xe CT was not performed. In symptomatic patients, rCBF after acetazolamide challenge and  $\Delta F$  were significantly higher after treatment than before ( $P < .05$ ), whereas treatment such as embolization did not change the resting rCBF (Table 3). Asymptomatic patients tended to have an improvement in acetazolamide-associated rCBF and  $\Delta F$  with treatment of the DAVF, but



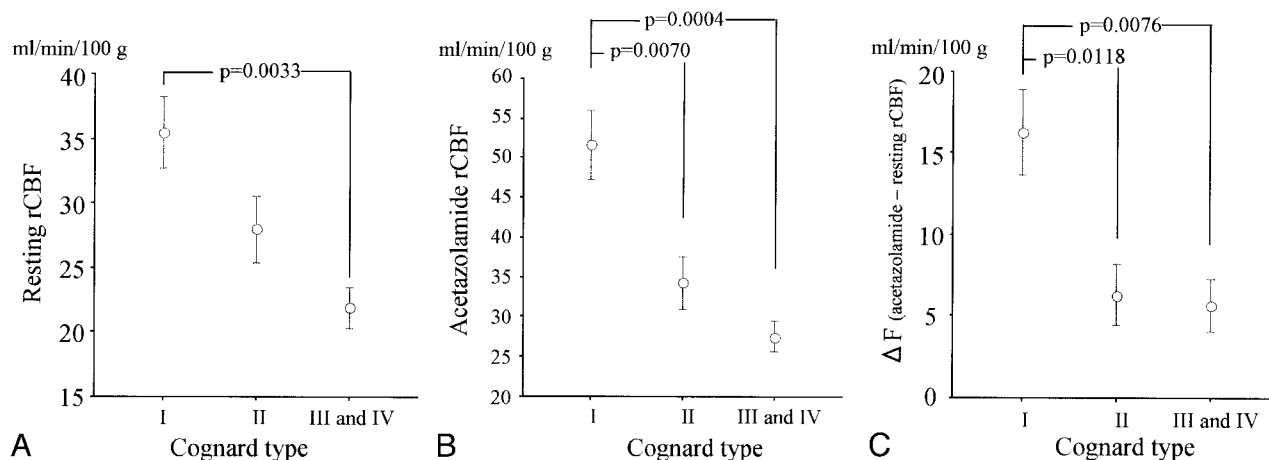


FIG 3. Differences in rCBF between groups according to Cognard angiographic classification.

A, Resting rCBF significantly differs between type I and types III and IV.

B, After acetazolamide challenge, rCBF significantly differs, even between type I and type II.

C, Increase in rCBF due to acetazolamide ( $\Delta F$ , or acetazolamide value minus resting value) is significantly different between type I and the other types.

TABLE 2: rCBF in patients with and those without symptoms caused by venous hypertension

Measure	Symptomatic Group	Asymptomatic Group	P Value*
Age (y)	58.8 $\pm$ 15.3	69.4 $\pm$ 10.5	.1118
rCBF (mL/min/100g)			
Resting	23.3 $\pm$ 5.1	33.2 $\pm$ 7.8	.0092
Acetazolamide	27.1 $\pm$ 5.1	47.6 $\pm$ 10.9	.0003
$\Delta F^\dagger$	3.9 $\pm$ 2.7	14.4 $\pm$ 6.2	.0002

\* Mann-Whitney U test.

$^\dagger$  Acetazolamide rCBF – resting rCBF.

given the small number of cases, the difference was not significant ( $P = .068$ ).

## Discussion

In DAVF, venous ischemia and hemorrhage result from retrograde leptomeningeal venous drainage (1, 3, 13) because venous hypertension decreases the normal pressure gradient between cerebral arteries and veins. Therefore, evaluation of venous hypertension is essential for treatment of DAVF. In frontal fossa or tentorial DAVFs, treatment is required irrespective of symptoms, given the great risk of intracerebral hemorrhage due to disturbed venous return (14, 15). Treatment decisions concerning DAVF should be based on the patient's symptoms and also the type of cortical venous and sinus reflux. Many angiographic classifications (5–7, 13) proposed from this viewpoint are used to qualitatively assess venous reflux. However, quantitative assessment of congestion or venous hypertension is considerably more objective and informative.

Venous hypertension first increases cerebral blood volume (CBV) and then reduces CBF. Therefore, the degree of venous hypertension can be estimated by measuring CBV, which presently requires positron emission tomography, a procedure with limited avail-

ability. Perfusion MR imaging and perfusion CT are used to evaluate CBV by comparing sides; therefore, these more-available do not help in evaluating severe venous hypertension present throughout the brain. Cerebral angiography, an invasive examination, depicts retrograde leptomeningeal venous drainage and is used to determine an indication for treatment in cases of DAVF. However, cerebral angiography indicates only presence or absence of cerebral venous congestion and not the degree of the venous hypertension. As an alternative to angiography, dynamic MR digital subtraction angiography aids in diagnosing DAVF (16), especially if it is complemented by a noninvasive examination that provides quantitative information about venous hypertension.

A noninvasive examination, stable-Xe CT can provide an actual, nonrelative value for CBF. Moreover, a patient's cerebral vascular reserve capacity can be evaluated by performing stable-Xe CT before and after the administration of acetazolamide (10, 11). By inhibiting carbonic anhydrase, acetazolamide increases the concentration of  $H^+$  in the brain, which dilates the cerebral arterioles to increase CBF. However, blood flow depends on vascular resistance and the pressure gradient between arteries and veins. Even if the vascular resistance decreases, blood flow is not increased if the pressure gradient between arteries and veins is reduced. We hypothesized that venous hypertension blunts the increase in CBF elicited by acetazolamide because arteriolar dilation does not increase CBF in the presence of a decreased pressure gradient between the cerebral arteries and veins. In our study, the increase in CBF caused by acetazolamide was indeed limited in patients with symptoms of venous hypertension. Moreover, lesions of high angiographic grade were associated with weak responses to acetazolamide. In patients with type I lesions, the response of CBF to acetazolamide was unimpaired, whereas in those with type II, III, or IV lesions, it was eliminated. CBF responses to acetazol-

TABLE 3: Regional rCBF before and after treatment

rCBF (ml/min/100g)	Before Treatment	6 Months After Treatment	P Value*
Symptomatic patients (n = 10)			
Resting	23.3 ± 5.1	26.8 ± 7.3	.1849
Acetazolamide	27.1 ± 5.1	38.0 ± 12.4	.0166
$\Delta F^\dagger$	3.9 ± 2.7	11.2 ± 7.0	.0367
Asymptomatic patients (n = 4)			
Resting	28.8 ± 8.2	30.1 ± 6.4	>.05
Acetazolamide	38.4 ± 7.6	47.4 ± 8.6	.0679
$\Delta F^\dagger$	9.7 ± 2.6	17.2 ± 6.9	.0679

\* Wilcoxon signed rank test.

 $^\dagger$  Acetazolamide rCBF – resting rCBF.

amide were negatively related to the severity of cortical venous hypertension caused by the DAVF. Resting rCBF was reduced in types III and IV but unimpaired in type II. In patients with DAVF, a reduced response to acetazolamide was a more sensitive indicator of venous hypertension than resting rCBF.

Our observations suggest a need for caution in interpreting the results of acetazolamide tests performed for indications other than the assessment of a DAVF. The acetazolamide test was originally developed to identify patients with compromised cerebrovascular reserve (10). Kuroda et al (9) reported that decreased rCBF and decreased regional cerebrovascular reserve, as shown on acetazolamide testing, may identify a subgroup of patients with an increased risk of subsequent ischemic stroke if they are treated only medically. However, because venous hypertension and/or congestion influences regional cerebrovascular reserve on acetazolamide testing, the test is reliable in evaluating cerebral arterial hemodynamic impairment only if venous outflow is unimpaired.

Iwama et al (17) reported that patients with DAVF and cerebral symptoms had severely reduced rCBF and a mildly elevated regional oxygen-extraction fraction. Their symptomatic patients presented with impairments ranging from disorientation to disturbed consciousness, whereas some of our symptomatic patients also had milder symptoms, such as headache or focal neurologic signs. However, in our study, resting rCBF in symptomatic patients was still significantly lower than that in asymptomatic patients. van Roost and Schramm (13) demonstrated a reduction in rCBF and impaired regional cerebrovascular reserve capacity in patients with a cerebral arteriovenous malformation (AVM). Moreover, venous congestion, large AVMs, and AVM-related vascular territories were associated with impaired vascular reserve capacity. In our patients with DAVF, the increase in rCBF induced by acetazolamide was significantly decreased in the group with symptoms venous hypertension.

Because stable-Xe CT can be used to measure actual rather than relative rCBF, the method is used to evaluate rCBF after extracranial-intracranial bypass surgery (18) or steroid treatment of brain tumors (19). We similarly used Xe CT to evaluate rCBF after the treatment of DAVF. In symptomatic patients, the response of rCBF to acetazolamide improved at 6

months after treatment. According to our hypothesis, these results indicated that treatment normalized the severely reduced pressure gradient between the artery and vein in symptomatic patients. On the contrary, resting rCBF did not improve with treatment in symptomatic patients. Because venous hypertension is a chronic condition, recovery from venous congestion after treatment may require a long interval. This requirement may reflect limitations in the present treatments for DAVF, which only interrupt cortical venous reflux without reconstructing the occluded sinus. Therefore, patients may require extended follow-up.

Because DAVF-associated venous hypertension (which can cause intracranial hemorrhage or venous infarction) influences the degree to which rCBF increases with acetazolamide, rCBF evaluation with acetazolamide is prognostically useful. In general, treatment for DAVF is indicated when angiograms show a reflux of flow into the cortical veins. In the Cognard classification, types IIb, IIa+b, III, and IV are indications for treatment. In our study, patients in these groups had an impaired response of rCBF to acetazolamide. Although symptoms of venous hypertension indicate a need for embolization or other treatment, a poor or absent response of rCBF to acetazolamide may help in identify candidates, even in the absence of such symptoms. Acetazolamide testing is a simple, easily performed, and informative method for evaluating both the need for intervention and its effectiveness. Further prospective study is warranted to confirm our observation.

## Conclusion

The results of cerebral hemodynamic evaluation with acetazolamide corresponded to those of conventional angiographic classification of DAVF. Moreover, the response of rCBF to acetazolamide helped in identifying venous hypertension in patients with DAVE. Therefore, the acetazolamide test can contribute to decision making concerning embolization or other treatment for DAVF. A poor or absent response of rCBF to acetazolamide indicates a need for such intervention. Cerebral angiography is not required to simply diagnose DAVF, and it can be reserved for patients who require treatment for DAVF, as determined on the basis of

results of acetazolamide testing or symptoms of venous hypertension.

## References

- Awad IA, Little JR, Akrawi WP, et al. **Intracranial dural arteriovenous malformations: factors predisposing to an aggressive neurological course.** *J Neurosurg* 1990;72:839–850
- Chung SJ, Kim JS, Kim JC, et al. **Intracranial dural arteriovenous fistulas: analysis of 60 patients.** *Cerebrovasc Dis* 2002;13:79–88
- van Dijk JMC, terBrugge KG, Willinsky RA, et al. **Clinical course of cranial dural arteriovenous fistulas with long-term persistent cortical venous reflux.** *Stroke* 2002;33:1233–1236
- Willinsky R, Goyal M, terBrugge K, et al. **Tortuous, engorged pial veins in intracranial dural arteriovenous fistulas: correlations with presentation, location, and MR findings in 122 patients.** *AJNR Am J Neuroradiol* 1999;20:1031–1036
- Borden JA, Wu JK, Shucart WA. **A proposed classification for spinal and cranial dural arteriovenous fistulas malformations and implications for treatment.** *J Neurosurg* 1995;82:166–179
- Cognard C, Gobin YP, Pierot L, et al. **Cerebral dural arteriovenous fistulas: clinical and angiographic correlation with a revised classification of venous drainage.** *Radiology* 1995;194:671–680
- Lalwani AK, Dowd CF, Halbach VV. **Grading venous restrictive disease in patients with dural arteriovenous fistulas of the transverse/sigmoid sinus.** *J Neurosurg* 1993;79:11–15
- Fujita A, Nakamura M, Tamaki N, et al. **Haemodynamic assessment in patients with dural arteriovenous fistulae: dynamic susceptibility contrast-enhanced MRI.** *Neuroradiology* 2002;44:806–811
- Kuroda S, Houkin K, Kamiyama H, et al. **Long-term prognosis of medically treated patients with internal carotid or middle cerebral artery occlusion: can acetazolamide test predict it?** *Stroke* 2001;32:2110–2116
- Pindzola RR, Balzer JR, Nemoto EM, et al. **Cerebrovascular reserve in patients with carotid occlusive disease assessed by stable xenon-enhanced CT cerebral blood flow and transcranial Doppler.** *Stroke* 2001;32:1811–1817
- Rogg J, Rutigliano M, Yonas H, et al. **The acetazolamide challenge: Imaging techniques designed to evaluate cerebral blood flow reserve.** *AJNR Am J Neuroradiol* 1989;10:803–809
- Lasjaunias PL, Rodesch G. **Lesion types, hemodynamics, and clinical spectrum.** In: Awad IA and Barrow DL, eds. *Dural Arteriovenous Malformations*. Rolling Meadows, IL: American Association of Neurological Surgeons; 1993:49–79
- van Roost D, Schramm J. **What factors are related to impairment of cerebrovascular reserve before and after arteriovenous malformation resection? A cerebral blood flow study using Xenon-enhanced computed tomography.** *Neurosurgery* 2001;48:709–717
- Awad IA. **Tentorial incisure and brain stem dural arteriovenous malformations.** In: Awad IA and Barrow DL, eds. *Dural Arteriovenous Malformations*. Rolling Meadows, IL: American Association of Neurological Surgeons; 1993:131–146
- King WA, Martin NA. **Anterior fossa dural arteriovenous malformations.** In: Awad IA and Barrow DL, eds. *Dural Arteriovenous Malformations*. Rolling Meadows, IL: American Association of Neurological Surgeons; 1993:105–116
- Coley SC, Romanowski CA, Hodgson TJ, et al. **Dural arteriovenous fistulae: noninvasive diagnosis with dynamic MR digital subtraction angiography.** *AJNR Am J Neuroradiol* 2002;23:404–407
- Iwama T, Hashimoto N, Takagi Y, et al. **Hemodynamic and metabolic disturbances in patients with intracranial dural arteriovenous fistulas: positron emission tomography evaluation before and after treatment.** *J Neurosurg* 1997;86:806–811
- van Roost D, Hartmann A, Quade G. **Changes of cerebral blood flow following dexamethasone treatment in brain tumor patients: a Xe/CT study.** *Acta Neurochir (Wien)* 2001;143:37–44
- Yamashita T, Kashiwagi S, Nakano S, et al. **The effect of EC-IC bypass surgery on resting cerebral blood flow and cerebrovascular reserve capacity studied with stable Xe-CT and acetazolamide test.** *Neuroradiology* 1991;33:217–222