

Are your MRI contrast agents cost-effective?

Learn more about generic Gadolinium-Based Contrast Agents.



FRESENIUS
KABI

caring for life

AJNR

Tumefactive Cysts: A Delayed Complication following Radiosurgery for Cerebral Arterial Venous Malformations

Whitney B. Edmister, John I. Lane, Julie R. Gilbertson,
Robert D. Brown and Bruce E. Pollock

This information is current as
of April 19, 2024.

AJNR Am J Neuroradiol 2005, 26 (5) 1152-1157
<http://www.ajnr.org/content/26/5/1152>

Case Report

Tumefactive Cysts: A Delayed Complication following Radiosurgery for Cerebral Arterial Venous Malformations

Whitney B. Edmister, John I. Lane, Julie R. Gilbertson, Robert D. Brown, and Bruce E. Pollock

Summary: We report five cases of symptomatic delayed cyst formation after radiosurgery for intracranial arterial venous malformations. Median time to discovery of the cysts following most recent radiosurgery was 59 months (range, 34–89 months). In all five patients, the radiation therapy–induced cysts exhibited tumefactive characteristics, including vasogenic edema, mass effect, and nodular enhancement. Despite these malignant features, these cystic lesions should be recognized as a benign complication of radiosurgery so that proper treatment (i.e., cystoperitoneal shunt surgery or excision) can be initiated.

Radiosurgery has emerged as a safe and effective alternative to craniotomy and direct surgical intervention for the treatment of some patients with benign or malignant intracranial lesions. Most commonly, radiosurgery has been successfully used to treat intracranial arterial venous malformations (AVMs; 1). As the number of patients treated by radiosurgery continues to increase, the neuroradiologist needs to be familiar with the complications that occur as a result of radiation therapy and their imaging findings. Reported complications include parenchymal hemorrhage, radiation necrosis, arterial stenosis, occlusive hyperemia, diffuse white matter ischemia, and delayed cyst formation (2). We report five cases of symptomatic radiation therapy–induced cysts as a late complication of radiosurgery.

Case Reports

Five cases of symptomatic delayed cyst formation after radiosurgery for intracranial AVMs were managed at our institution between April 1996 and June 1999 (Table 1). The clinical management and surgical treatment of these cysts were described by Pollock et al (3). Four patients had gamma knife radiosurgery at our center, and one patient received linear accelerator radiosurgery elsewhere. Two of the patients had repeat radiosurgery at 38 and 44 months after initial radiosurgery failed to eliminate their AVMs. Median age at treatment was 24 years (range, 20–56 years). Median time to discovery of the cysts following most recent radiosurgery was 59 months

(range, 34–89 months). Three patients presented with symptoms related to mass effect and underwent treatment. Cysts were discovered incidentally in two patients who later developed symptoms and were treated at 13 and 40 months after diagnosis. Patients underwent cyst aspiration ($n = 4$), cystoperitoneal shunt surgery ($n = 5$), and excision ($n = 2$), with no morbidity. Pathologic results were benign in both cases treated by cystectomy.

Case 1

A 33-year-old woman presented with severe, recurrent headaches and a right parietal AVM was the diagnosis. She underwent gamma knife ablation of the AVM that was verified by conventional angiography. Following radiosurgery, she developed a hemorrhage with two episodes of generalized tonic-clonic seizures. Although the hemorrhage resolved, she continued to have severe headaches. Imaging at that time showed only vasogenic edema in the postradiation bed. She was treated with steroids, and her symptoms resolved. Her neurologic examination was stable for many years. Eighty-nine months after the radiation therapy treatment for her right parietal AVM, she presented again with gradually increasing left arm weakness and numbness in an ulnar distribution of her left hand. MR imaging showed a 3-cm cyst in the frontoparietal region with vasogenic edema and nodular contrast enhancement superficial to the cyst (Fig 1A, B). This was initially interpreted by the radiologist as a possible radiation-induced neoplasm. The patient underwent successful cyst aspiration under stereotactic guidance. Two months after aspiration, the cyst and the associated neurologic symptoms recurred and cystoperitoneal shunting was performed. Postoperative CT showed successful decompression of the cyst (Fig 1C). The patient remains asymptomatic after 4 years.

Case 2

A 23-year-old woman underwent radiation therapy for a left parietal AVM. Complete resolution of the AVM was documented by angiography. She had a generalized seizure 66 months after the radiation therapy treatment. MR imaging showed a small 1-mL cyst adjacent to the AVM site. She had no further seizures or symptoms. Another 40 months later, she gradually developed generalized neurologic symptoms such as difficulty finding words and progressive headaches. She experienced a single 6–8-hour episode of right arm numbness that resolved completely. She underwent cyst aspiration, but this was unsuccessful and her cysts returned. MR imaging performed 2 weeks after the initial cyst aspiration but before the cystoperitoneal shunt placement showed a 5-cm complex, multiloculated cyst in the left frontoparietal region with irregular peripheral enhancement, vasogenic edema, and local mass effect (Fig 2A, B). CT imaging after cystoperitoneal shunt placement showed complete decompression of the cysts (Fig 2C). The patient remains asymptomatic after 2 years.

Received January 5, 2004; accepted after revision August 6.

Presented at the 40th annual meeting of the American Society of Neuroradiology, Vancouver, B.C., May 11–17, 2002.

From the Departments of Radiology (W.B.E., J.I.L., J.R.G.), Neurology (R.D.B.), and Neurosurgery (B.E.P.), Mayo Clinic, Rochester, MN.

Address correspondence to John I. Lane, MD, Department of Radiology, Mayo Clinic, 200 1st Street SW, Rochester, MN 55905.

© American Society of Neuroradiology

Summary of patient demographics and clinical history

Case	Age at Gamma Tx	Sex	Rx isodose vol (cc), margin/max dose (Gy)	Tx to cyst Dx (months)	Size at Dx (cc)	Sx	Tx	AVM location
1	33	F	28.7, 16/20	89	14.0	HA, L arm weakness.	Aspiration; CP shunt.	R parietal
2	23	F	13.4, 16/32	66	1.0 (40 at 106 months)	None. HA, mild aphasia, transient R arm paresthesia at 106 months.	Aspiration; CP shunt.	L parietal
3	20	F	13.5, 28/22.5	34	11.9	HA.	Aspiration; CP shunt.	R temporal
4	56	F	8.0, 16/32 4.9, 18/36	59	4.0	Repeat Tx at 44 months. HA, ataxia.	Aspiration; CP shunt; cystectomy.	R temporal
5	24	M	11.1, 18/36 16.5, 16/32	37	3.5 (63 at 50 months)	Repeat Tx at 38 months. None. HA at 50 months.	CP shunt; cystectomy.	L parietal

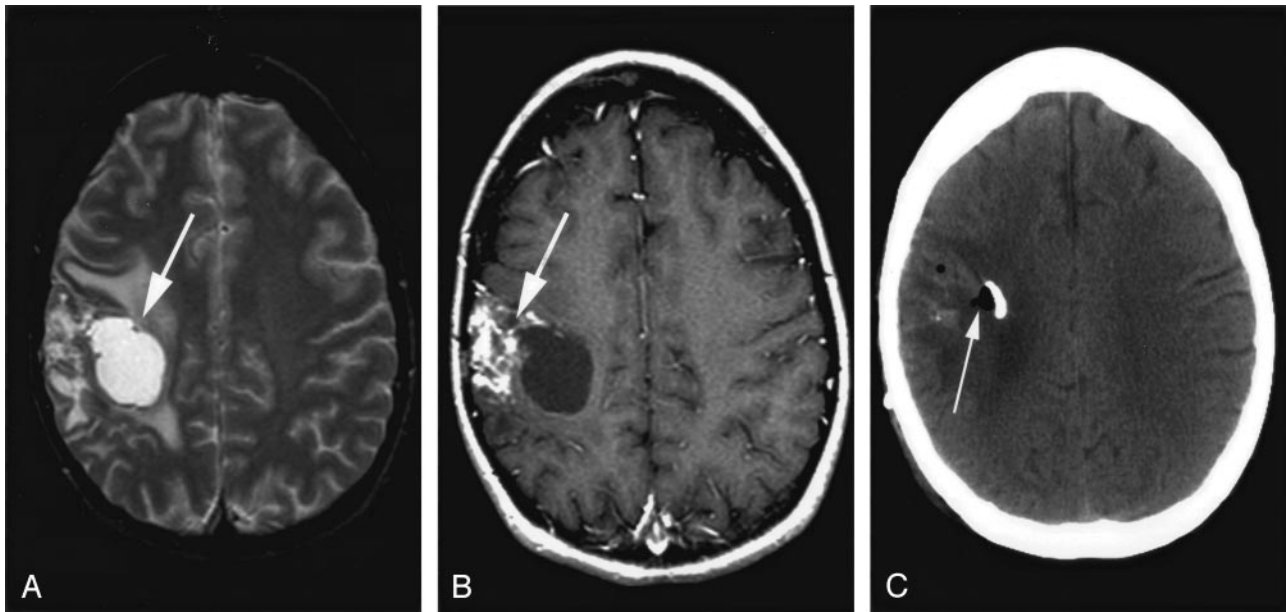


FIG 1. Radiation therapy-induced cyst 89 months after AVM treatment.

A, T2-weighted axial image shows a 3-cm cyst in the frontoparietal region with vasogenic edema (arrow).

B, Contrast-enhanced T1-weighted axial image shows nodular contrast enhancement superficial to the cyst (arrow).

C, Postoperative CT showed successful cyst decompression (arrow) after cystoperitoneal shunt placement.

Case 3

A 20-year-old woman presented to the hospital emergency room with a severe headache and presyncopal episode. Imaging showed a temporal-occipital interparenchymal hemorrhage secondary to a right temporal AVM. She underwent linear accelerator therapy for the AVM. After the radiosurgery, she had some immediate difficulty with her vision in her left eye but otherwise did well. One year later, she presented with further visual complaints in her left eye, headaches, and difficulty with short-term memory. CT imaging again showed an intracranial hemorrhage with extension into the ventricular system and significant vasogenic edema causing mass effect. She was treated with high-dose steroids, and her symptoms subsided. Another year later, 34 months after her original radiosurgery, she developed a severe, bifrontal headache without focal neurologic symptoms. MR imaging showed multiple complex cysts in the posterior right temporal, occipital, and parietal region with extensive vasogenic edema, midline shift, and nodular enhancement (Fig 3A, B). There was a small residual AVM in the radiation therapy site, as well as three additional smaller AVMs. These included one lesion on the right side in the distal right interior cerebral artery, the callosal marginal branches,

and two lesions on the left side, one in the distal middle cerebral, and one in the distal anterior cerebral artery system. Initially this cyst was aspirated, but the cyst and the symptoms recurred. A cystoperitoneal shunt was placed. Two years after shunt placement, the vasogenic edema and enhancement persist, but the cyst has resolved (Fig 3C, D). The patient has been asymptomatic for 4 years.

Case 4

A 56-year-old woman first presented with a right sylvian fissure AVM that was treated by gamma knife radiation therapy. The AVM recurred at 44 months and was treated again by gamma knife radiation therapy. Angiography confirmed obliteration of the AVM at this time. At 59 months from the initial gamma knife therapy, she developed symptoms of unsteady gait and generalized headaches. MR imaging showed interval development of multiple cysts with surrounding edema, mass effect, midline shift, and heterogeneous enhancement (Fig 4A, B). Three months after cyst aspiration, the cysts recurred, and a cystoperitoneal shunt was placed. After two shunt revisions for CSF drainage problems, an open cystectomy was performed

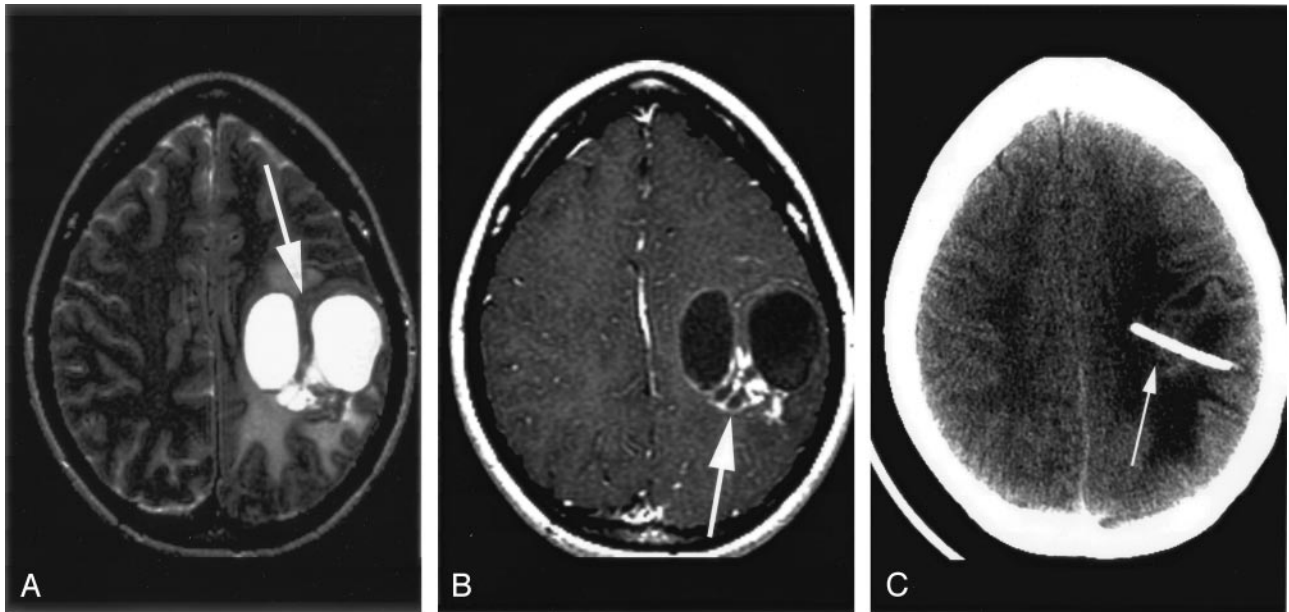


Fig 2. MR image obtained 40 months after AVM ablation.

A, T2-weighted axial image showed a 5-cm complex, multiloculated cyst in the left frontoparietal region with vasogenic edema and local mass effect (*arrow*).

B, Contrast-enhanced T1-weighted axial image shows nodular parenchymal enhancement (*arrow*).

C, CT after successful cystoperitoneal shunt placement shows decompression of the cysts.

(Fig 4C, D). MR imaging 1 year later showed postoperative changes, encephalomalacia, and resolution of the cysts. Pathologic results of the resected tissue showed an AVM with hemorrhage and gliosis. The patient remained asymptomatic at 13-month follow-up.

Case 5

A 24-year-old man with a left parietal lobe AVM was treated with gamma knife therapy. Three years later, a cerebral angiogram showed recurrence of the AVM. He was treated again by gamma knife. A small 3.5-mL cyst was diagnosed incidentally at 36 months on the basis of MR imaging results. Concurrent angiography showed that the AVM had been obliterated. Over the next 13 months, the patient developed increasingly severe generalized headaches. MR imaging showed that the cyst had enlarged to 63 mL with mass effect and peripheral enhancement (Fig 5A). A cystoperitoneal shunt was placed, decompressing the cyst. Even after shunt surgery, MR imaging showed recurrent cysts, new multiloculated cysts, and a residual AVM (Fig 5B, C). The patient underwent open resection 2 years after the shunt placement for definitive treatment. The patient remained asymptomatic at 14-month-follow-up.

Discussion

In recent years, radiosurgery with stereotactic MR imaging and gamma knife has become an alternative for open treatment of benign intracranial lesions, including AVMs. One of the delayed complications of this therapy is the formation of symptomatic, expansile cysts in the postradiation area. In this series, the earliest time to symptomatic cyst formation is 34 months. The longest time to presentation was 89 months after treatment. Patients were not routinely imaged after resolution of the AVM was documented by angiography or MR imaging.

The natural history of these cysts appears to be gradual expansion over time. Increasing mass effect results in increasing neurologic symptoms. These can be generalized, usually manifested by headaches or seizures, or focal, with symptoms such as aphasia, focal weakness, or paresthesia. Headache is the most common presentation. Once the cysts are properly diagnosed, the most effective treatment appears to be cystoperitoneal shunt surgery (3). Stereotactic cyst aspiration was not effective, and the cysts recurred in each case. In cases in which shunt surgery failed, cystectomy was the definitive treatment.

The delayed formation of benign cysts in the radiosurgery bed is a late complication of radiosurgery (3–10). The incidence of these cysts is not well known for two reasons. First, follow-up imaging is not done routinely after radiosurgery for the treatment of AVM. Once the resolution of the AVM has been documented by angiography or MR imaging and the patient is neurologically stable, follow-up imaging is obtained only in patients who present with new neurologic symptoms. Second, the time to cyst development is 2–8 years after radiosurgery, so patients must be followed routinely for many years to identify the incidence of cysts. Hara et al (4) and Yamamoto et al (5) reported three patients who developed cysts at 5, 7, and 9 years after radiosurgery for AVM who presented with focal neurologic deficits. Studies that examined patients 2 or 3 years after radiosurgery showed an incidence of cyst formation between 0.2% and 0.5% (8, 11). Nakamura et al, cited in work by Yamamoto et al (7), reported a higher incidence of 2.8% in a study of 213 patients with six cysts identified. Yamamoto et al routinely examined 38 patients

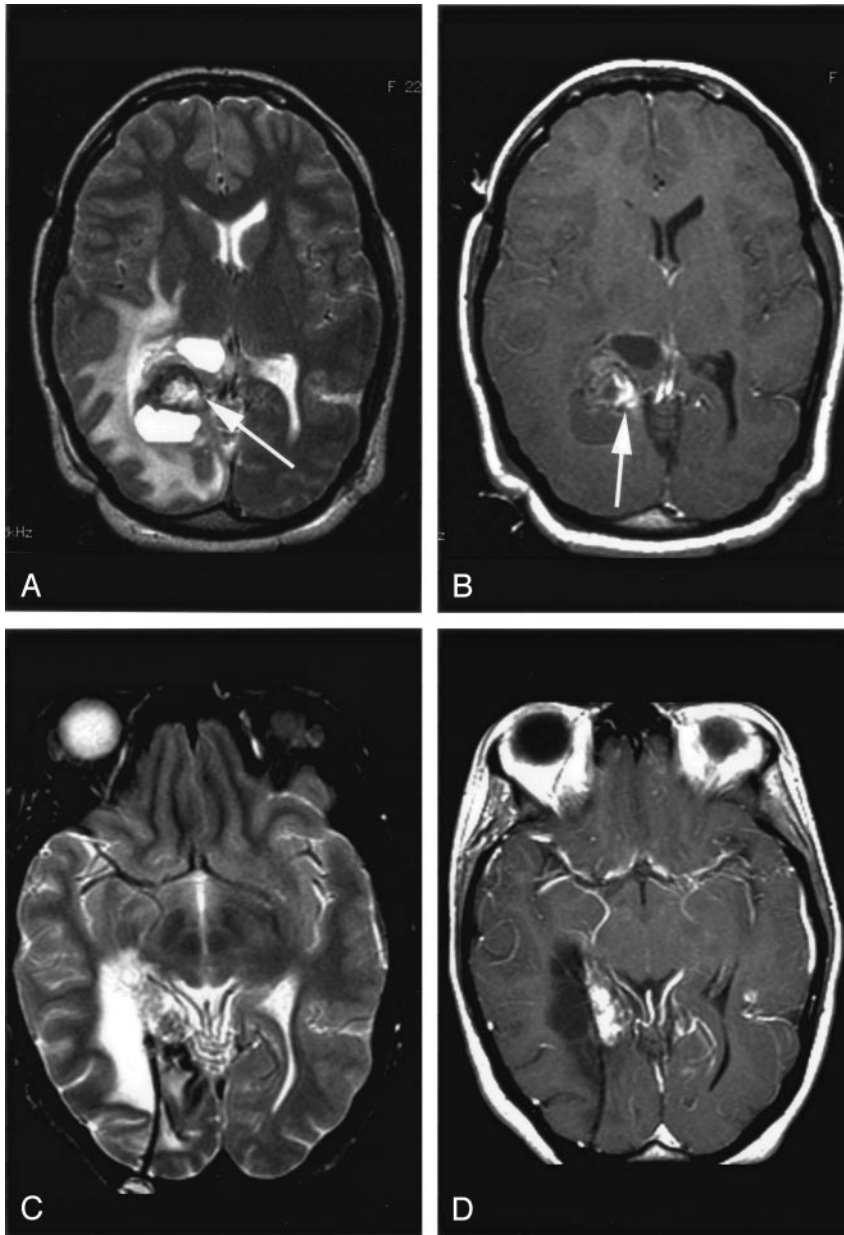


FIG 3. MR image obtained 34 months after AVM ablation.

A, T2-weighted axial image shows multiple complex cysts in the posterior right temporal, occipital, and parietal region with vasogenic edema and mass effect.

B, Contrast-enhanced T1-weighted axial image shows nodular parenchymal enhancement.

C and D, MR images obtained after successful cystoperitoneal placement. Vasogenic edema and enhancement persist, but the patient remains asymptomatic after 4 years.

5 years after radiosurgery reported delayed cyst formation in three patients, a higher incidence of 7.9% (5). When Kihlstrom et al (6) imaged 18 patients treated by gamma knife for AVM 8 to 23 years after radiosurgery, they identified cysts in five patients and reported an incidence of 28%. The incidence of cysts does not correlate with the specific dose used for radiosurgery, but it may be related to the volume of tissue being treated with radiation therapy (1, 6).

The pathogenesis of these cysts is not understood. It has been proposed that these cysts occur after intraparenchymal hemorrhage as part of the resolution of the hematoma bed. In patients with both previous hematomas and cyst formation, however, the cysts occurred in different locations from the hematomas (6). It was postulated that the cysts were related to some property of the AVM being treated and may arise at the site of the nidus of the AVM. This

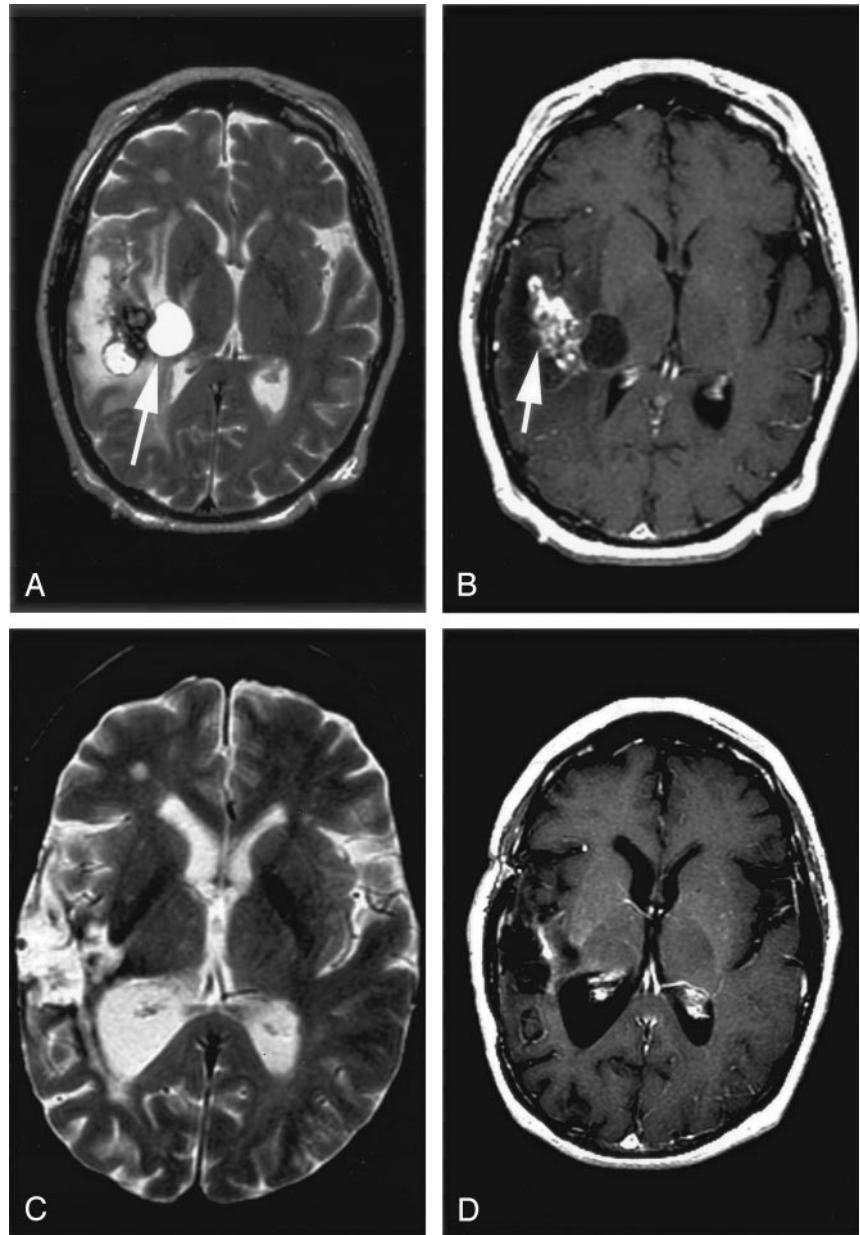
was disproved by the occurrence of radiation-induced cysts in patients treated for other benign lesions, including meningiomas and chordomas (3). Initially, radiation therapy induces focal coagulation necrosis and breakdown of the blood-brain barrier. Years later, this is replaced by liquefactive necrosis in the same tissue. Because these cysts contain a proteinaceous, plasma transudate, they are thought to be the result of this combination of liquefactive necrosis and blood brain-barrier breakdown (12, 13). MR imaging is very sensitive for the detection of radiation-induced changes in the brain following radiosurgery (2, 14). Vasogenic edema, white matter demyelination, encephalomalacia, contrast enhancement, and mass effect have been described and can persist for decades (2, 15). These delayed cysts have several malignant features, including a thick irregular wall, contrast enhancement, vasogenic edema, gradual enlargement,

FIG 4. MR image obtained 59 months after AVM ablation.

A, T2-weighted axial image demonstrates multilocular cyst with surrounding vasogenic edema (*arrow*).

B, Contrast-enhanced T1-weighted axial image shows nodular parenchymal enhancement (*arrow*).

C and D, MR after cystectomy show postoperative encephalomalacia, resolution of cysts and minimal residual parenchymal enhancement (*arrow*).



and neurologic symptoms. The appearance of these cysts in the background of radiation-induced changes can have an appearance similar to a primary or radiation-induced neoplasm. In a few reported cases (4–7), these cysts have been excised to exclude a new primary or radiation-induced malignancy in the radio-surgery bed.

Several diagnostic criteria may be suggested from this series of cases. Radiation-induced cysts occur at the site of previous irradiation. These cysts are typically complex and multilocular. Often there is a single dominant cyst with multiple smaller satellite cysts. They have a thin wall that enhances after intravenous gadolinium diethylene triamine pentaacetic acid (Gd-DTPA) injection. There is heterogeneous nodular enhancement in the adjacent tissue. When followed over time, the cysts expand in size, resulting in in-

creasing mass effect and neurologic symptoms. The increased T2 signal intensity in the white matter within the radiation bed may be due to a combination of vasogenic edema, gliosis, and demyelination of the white matter in the treatment area (6). These T2 changes persist for many years but decrease gradually over time.

These delayed cysts can be similar in appearance to a radiation-induced glioblastoma multiforme (GBM), which is the primary differential consideration (16). GBMs are characterized by Gd-DTPA enhancement, solid and cystic components, vasogenic edema, and mass effect. Although ependymomas and lymphomas are more common than GBMs in sites of previous irradiation, they do not typically have this cystic appearance. The probability of a primary GBM occurring in the radiation bed of a benign AVM is very low.

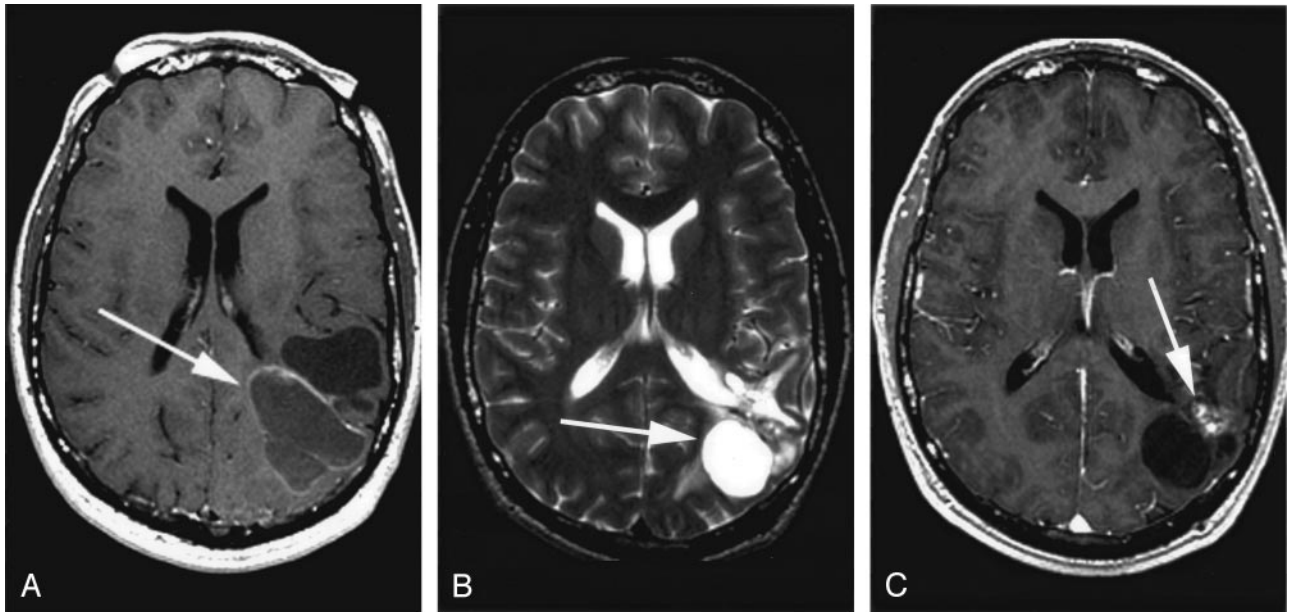


FIG 5. MR image obtained 36 months after AVM ablation.

A, Contrast-enhanced axial T1-weighted image shows a peripherally enhancing, multiloculated cyst in the left parietal lobe.

B and C, T2-weighted and post-contrast T1-weighted images obtained after cystoperitoneal shunting show residual cyst and enhancement (arrows).

The clinical history of prior radiation therapy for AVM ablation and awareness of this late complication are critical to making the diagnosis of a radiation therapy-induced cyst.

Conclusion

Years after radiosurgery for the treatment of intracranial AVM, some patients will develop symptomatic, complex cysts in the postradiation bed. These cysts are benign despite having malignant features that include complex structure, thin enhancing wall, adjacent heterogeneous nodular enhancement, white matter T2 hyperintensity, mass effect, and neurologic symptoms. If symptoms of mass effect develop, these lesions are treated effectively by shunt surgery or excision. Familiarity with the appearance and temporal evolution of these cysts should enable the radiologist to make the proper diagnosis and avoid unnecessary biopsy, surgery, or patient concern.

References

1. Karlsson B, Lax I, Soderman M. Factors influencing the risk for complications following Gamma Knife radiosurgery of cerebral arteriovenous malformations. *Radiother Oncol* 1997;43:275-280
2. Plowman P. Stereotactic radiosurgery. VIII. The classification of postradiation reactions. *Br J Neurosurg* 1999;13:256-264
3. Pollock BE, Brown RD Jr. Management of cysts arising after radiosurgery to treat intracranial arteriovenous malformation. *Neurosurgery* 49:259-264
4. Hara M, Nakamura M, Shiokawa Y, et al. Delayed cyst formation after radiosurgery for cerebral arteriovenous malformation: two case reports. *Minim Invas Neurosurg* 1998;41:40-45
5. Yamamoto M, Jimbo M, et al. Gamma knife radiosurgery for arteriovenous malformations: long-term follow-up results focusing on complications occurring more than 5 years after irradiation. *Neurosurg* 1996;38:906-914
6. Kihlstrom L, Guo W, Karlsson B, et al. Magnetic resonance imaging of obliterated arteriovenous malformations up to 23 years after radiosurgery. *J Neurosurg* 1997;86:589-593
7. Yamamoto M, Ide M, Jimbo M, et al. Late cyst convolution after gamma knife radiosurgery for cerebral arteriovenous malformations. *Stereotact Funct Neurosurg* 1998;70:166-178
8. Kihlstrom L, Hindmarsh T, Lax I, et al. Radiosurgical lesions in the normal human brain 17 years after gamma knife capsulotomy. *Neurosurgery* 1997;41:396-402
9. Kim MS, Lee SI, Sim JH. A case of very large cyst formation with gamma knife radiosurgery for an arteriovenous malformation [Suppl]. *Stereotact Funct Neurosurg* 1999;2:168-174
10. Radanowicz-Hartmann V, Bachli H, Gratzl O. Late complication of radiosurgery of AVMs with the gamma knife: a case report. *Acta Neurochir (Wien)* 1998;140:194-195
11. Forster DMC. Complication management. Paper presented at the 2nd Congress of the International Stereotactic Radiosurgery Society, Boston, MA, June 14-17, 1995
12. Gardner WJ, Collis JS, Lewis LA. Cystic brain tumors and blood brain barrier. *Arch Neurol* 1963;8:291-298
13. Hara M, Moeda R, Takeuchi K, Kitamura M. Biochemical analysis of cyst fluid of brain tumor. *Brain Nerve* 1974;26:1075-1082
14. Flickinger JC, Kondziolka D, Lunsford LD, et al. A multi-institutional analysis of complication outcomes after arteriovenous malformation radiosurgery. *Int J Radiat Oncol* 1999;44:67-74
15. Kwon Y, Khang SK, Kim CJ, et al. Radiologic and histopathologic changes after gamma knife radiosurgery for acoustic schwannoma [Suppl]. *Stereotact Funct Neurosurg* 1999;72:2-10
16. Yu JS, Yong WH, Wilson D, Black KL. Glioblastoma induction after radiosurgery for meningioma. *Lancet* 2000;356:1576-1577