AJNR

Nocardial Endophthalmitis and Subretinal Abscess: CT and MR Imaging Features with Pathologic Correlation: A Case Report

Eugene Yu, Suzanne Laughlin, Edward E. Kassel, Hans A. Messner and Yeni H. Yucel

AJNR Am J Neuroradiol 2005, 26 (5) 1220-1222
http://www.ajnr.org/content/26/5/1220

AJNR Am J Neuroradiol 26:1220–1222, May 2005

Case Report

Nocardial Endophthalmitis and Subretinal Abscess: CT and MR Imaging Features with Pathologic Correlation: A Case Report

Eugene Yu, Suzanne Laughlin, Edward E. Kassel, Hans A. Messner, and Yeni H. Yucel

Summary: Ocular nocardiosis is a rare but potentially aggressive process. Clinically, it can mimic other disease entities, including neoplasia and other types of infection. We present a case of nocardial panophthalmitis progressing to subretinal abscess and emphasize the radiologic and clinical features.

Intraocular nocardial infection is most commonly caused by an aerobic, filamentous, branching bacterium called *Nocardia asteroides* (1). Ocular infection can manifest in many forms corresponding to the area of the globe that is involved. Aggressive disease can lead to the development of endophthalmitis and intraocular abscess formation. To the best of our knowledge, this is the first case in the literature demonstrating the CT and MR imaging features of an intraocular nocardial abscess.

Case Report

A 41-year-old woman presented with redness, pain, and decreased visual acuity in the left eye. The patient had undergone an unrelated bone marrow transplant 7 months prior. Her medications at the time included cyclosporine and prednisone. Ophthalmologic examination of the affected eye revealed a small hypopyon, vitreal haze, and only the visual perception of hand motion. An urgent MR imaging revealed generalized scleral thickening, edema and small, irregular enhancing foci in the vitreous (Fig 1A, -B). The presumptive diagnosis of a likely viral uveitis and vitreitis was made, and the patient was started on antiviral therapy. The possibility of an ocular leukemic relapse was also kept in mind, and the patient underwent a pars plana vitrectomy, conjunctival biopsy, and blood cultures. The vitrectomy samples yielded negative cultures, with no evidence of bacteria. Viral polymerase chain reaction for herpes simplex virus, cytomegalovirus, Epstein-Barr virus, and human herpes virus (HHV) and blood cultures and toxoplasma IgG were also negative. In the weeks that followed, the patient's vision continued to deteriorate and the left eye became completely blind. A second MR imaging and a CT scan of the orbits were performed. CT imaging (Fig 2) revealed progression of disease with marked irregular wall thickening of the left globe and irregularity along the optic nerve. Inflammatory changes within the retroorbital fat, proptosis, and preseptal edema was also noted. An MR image was obtained the same day (Fig 3A–D), which confirmed the presence of disease progression. Folded leaves of the detached left retinal were clearly visible on the T2-weighted scans. MR imaging also showed evidence of early inflammatory change involving the right globe and lateral rectus musculature. Diffusion-weighted and apparent diffusion coefficient (ADC) images showed restricted diffusion in the left-side subretinal fluid, compatible with an abscess collection.

Because of the severe damage to the left eye, a decision was made to enucleate the globe.

Two days before surgery, the patient developed a pustule on her left forearm. This was sampled, and histology and culture revealed *N. asteroides.* The pathologic examination of the globe revealed a panophthalmitis with inflammatory infiltration of the sclera and choroid. Scleral perforation and a retinal detachment were also present. Purulent material was also filling the vitreous and subretinal space (Fig 4), which nicely correlated with the finding on MR imaging. Gram stains revealed the presence of filamentous, Gram-positive bacteria (Fig 5). Aggressive antimicrobial therapy was instituted. The vision in the remaining eye was 20/20 following surgery. Shortly thereafter, the patient's condition deteriorated and was complicated by the development of a generalized seizure and subdural fluid collections. The patient also developed skin and flank nodules, which were attributed to nocardia. Acute respiratory distress syndrome then developed, and the patient died approximately 3 weeks following surgery.

Discussion

Nocardia is an aerobic, Gram-positive bacterium that is of the order Actinomycetales, which is ubiquitous in soil. It is characterized by the formation of branching filamentous chains and acid fast staining (2). The organism can affect the skin, upper respiratory tract, and lungs as well as the pharyngeal mucosa. Ninety percent of human infections are caused by *N. asteroides* (3), with pulmonary disease being the most common form of infection (4). Ocular infection can manifest in various forms including keratitis, conjunctivitis, scleritis, and endophthalmitis. The preseptal soft tissues, as well as the lacrimal system, can also be affected (2, 5). Ocular disease can develop from exogenous routes such as following ocular surgery or direct trauma and inoculation. Endogenous/hematogenous spread, especially from a pulmonary source, can also lead to ocular and CNS seeding. Predisposing conditions to infection include patient immunosuppression following organ transplantation or chemotherapy. Cases of ocular nocardia infection in patients with systemic lupus erytnematosus (SLE) and Behcet disease have also been documented (6, 7).

Received July 13, 2004; accepted July 18.

From the Departments of Neuroradiology (E.Y., S.L., E.E.K.) and Hematology (H.A.M.), University Health Network, Department of Neuroradiology, Mount Sinai Hospital (S.L.), and Department of Ophthalmology, St. Michael's Hospital (Y.H.Y.), Toronto, Ontario, Canada.

Address correspondence to Eugene Yu, MD, Department of Medical Imaging, Princess Margaret Hospital, 610 University Avenue Room 3-922, Toronto, Ontario, Canada, M5G 2M9.

FIG 1. *A,* Axial T1-weighted, postcontrast, fat-saturated image (350/20 [TR/TE]) through the orbits shows generalized scleral thickening involving the left eye. Small irregular enhancing foci are evident posteriorly within the vitreous chamber.

B, Axial T2-weighted, fat-saturated image (3,050/106.2 [TR/TE]) shows a lentiform area of low signal intensity posteromedialy within the left vitreous chamber. The diagnostic considerations included a scleritis with possible subretinal or subchoroidal effusion as well as the possibility of ocular leukemic infiltration.

FIG 2. Unenhanced axial CT image of the orbits demonstrates marked inflammatory changes involving the globe and extending along the optic nerve. Proptosis and preseptal edema is also evident.

As seen in this case report, ocular nocardiosis can be notoriously difficult to diagnose. Cultures and smears can be negative in approximately one-third of cases (8). Furthermore, systemic and ocular manifestations of nocardia can resemble that of fungal infections (6). Prompt diagnosis is necessary to ensure to commencement of appropriate antibacterial therapy. Reports have shown the benefits of vitrectomy or fine needle aspiration (FNA) vitreal specimens in aiding diagnosis (3, 6, 9). Treatment of ocular infection will vary with the location and severity of disease. Whereas a superficial nocardial keratitis can be treated with the use of topical sulfacetamide drops, a more aggressive infection will require systemic therapy and possibly surgical intervention.

In this case, the patient developed an enophthalmitis without another obvious primary source. The patient was immunocompromised secondary to her medications following bone marrow transplant. The clear diagnosis of ocular nocardia infection was made only after enucleation and subsequent pathologic examination. To the best of our knowledge, this is the first report in the literature documenting the radiographic evolution of nocardia endophthalmitis progressing to subretinal abscess formation.

Conclusion

Intraocular nocardial infection is a rare disease that can cause severe patient morbidity and mortality. Successful treatment requires a high index of suspicion, particularly in the immunocompromised patient population.

References

1. Rogers SJ, Johnson BL. **Endogenous nocardia endophthalmitis: report of a case in a patient treated for lymphocytic lymphoma.** *Ann Ophthalmol* 1977;9:1123–1131
2. Sridhar MS, Gopinathan U, Garg P, et al. **Ocular nocardia infections with special emphasis on the cornea.** *Surv Ophthalmol* 2001;45:361–378
3. Phillips WB, Shields CL, Shields JA, et al. **Nocardia choroidal abscess.** *Br J Ophthalmol* 1992;76:694–696
4. Suppiah R, Abraham G, Sekhar U, et al. **Nocardial endophthalmitis leading to blindness in a renal transplant recipient.** *Nephrol Dial Transplant* 1999;14:1576–1577
5. Climenhaga DB, Tokarewicz AC, Willis NR. **Nocardia keratitis.** *Can J Ophthalmol* 1984;19:284–286
6. Yap EY, Fam HB, Leong KP, Buettner H. **Nocardia choroidal abscess in a patient with systemic lupus erythematosus.** *Aust N Z J Ophthalmol* 1998;26:337–338
7. Korkmaz C, Aydinli A, Erol N, et al. **Widespread nocardiosis in two patients with Behcet's disease.** *Clin Exp Rheumatol* 2001;19:459–462
8. Ng EW, Zimmer-Galler IE, Green WR. **Endogenous *Nocardia asteroides* endophthalmitis.** *Arch Ophthalmol* 2002;120:210–213
9. Bozbeyoglu S, Yilmaz G, Akova YA, et al. **Choroidal abscess due to nocardial infection in a renal allograft recipient.** *Retina* 2004;24:164–166

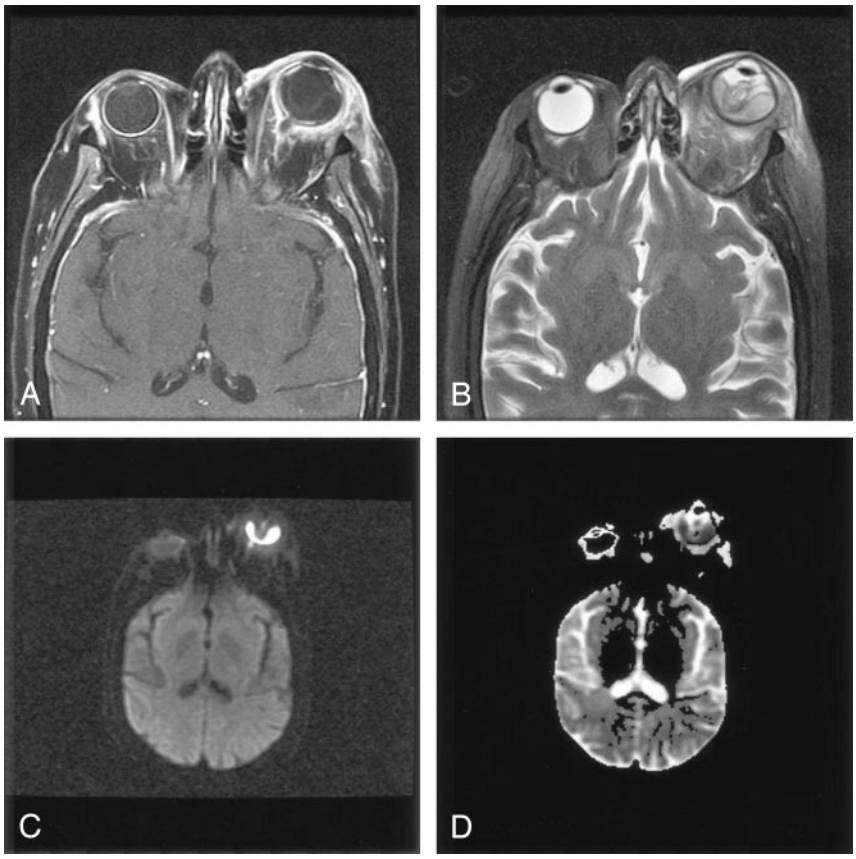

FIG 3. *A,* Axial T1-weighted, postcontrast, fat-saturated image (350/20 [TR/TE]) more clearly shows the marked left scleral wall thickening and orbital inflammatory change. A thin curvilinear enhancing membrane is also seen in the vitreous. Early wall thickening involving the right globe and enhancement along the right lateral rectus musculature is also seen.

B, Axial T2-weighted, fat-saturated imaging (3,516.7/85.6 [TR/TE]) shows folded curvilinear membranes situated within the vitreous consistent with retinal detachment.

C and *D,* Diffusion and ADC images demonstrates restricted diffusion within the left-side subretinal collection, which was consistent with abscess.

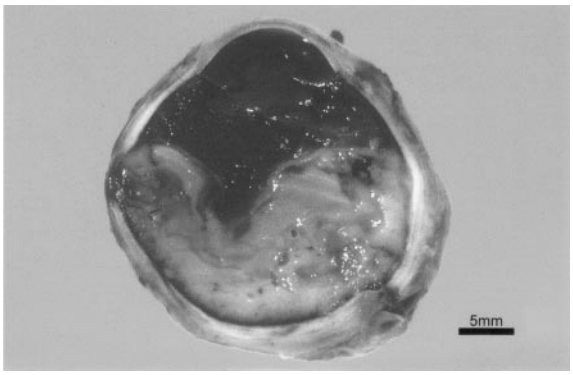

FIG 4. Axially sectioned macroscopic image of the left eye shows evidence of a purulent subretinal collection. Hemorrhage within the vitreous chamber is also evident.

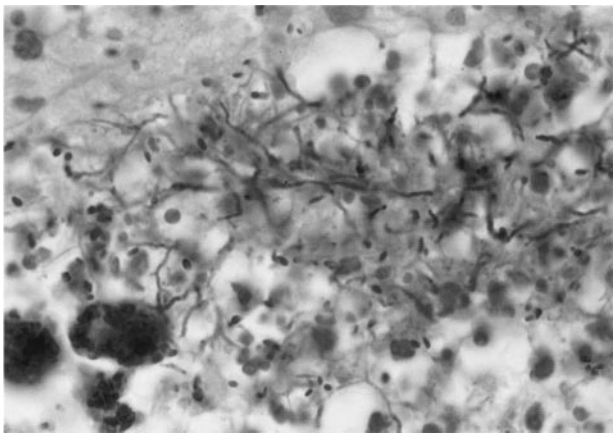

FIG 5. Gram-stain image shows branching filamentous bacteria. Cultures revealed the presence of *N. asteroides.*