

Are your **MRI contrast agents** cost-effective?

Learn more about generic **Gadolinium-Based Contrast Agents**.



AJNR

Stereolithographic Vascular Replicas from CT Scans: Choosing Treatment Strategies, Teaching, and Research from Live Patient Scan Data

Kimberly Knox, Charles W. Kerber, Soren A. Singel, Michael J. Bailey and Steven G. Imbesi

This information is current as of April 17, 2024.

AJNR Am J Neuroradiol 2005, 26 (6) 1428-1431
<http://www.ajnr.org/content/26/6/1428>

Stereolithographic Vascular Replicas from CT Scans: Choosing Treatment Strategies, Teaching, and Research from Live Patient Scan Data

Kimberly Knox, Charles W. Kerber, Soren A. Singel, Michael J. Bailey, and Steven G. Imbesi

Summary: Our goal was to develop a system that would allow us to recreate live patient arterial pathology by using an industrial technique known as stereolithography (or rapid prototyping). In industry, drawings rendered into dicom files can be exported to a computer programmed to drive various industrial tools. Those tools then make a 3D structure shown by the original drawings. We manipulated CT scan dicom files to drive a stereolithography machine and were able to make replicas of the vascular diseases of three patients.

Rapid prototyping (RP), also known as stereolithography, has wide application in industry. The technique uses computer data generated from either a drawing or 3D object to drive a computer-controlled machine that either mills away unwanted portions of a solid (as Michelangelo removed portions of a marble block to reveal David) or deposits or builds up focal accretions, usually of plastic, thus recreating the 3D original (much as a modern sculptor would add bits of clay to an armature, eventually resulting in a completed sculpture). Unfortunately, as Webb has noted, “the use of RP technology has been slow arriving in the medical arena.” (1) Nonetheless, the technique has found use in orthopedic trauma surgery (2–4), but more commonly in maxillofacial work (4). Webb (1) and by Petzold et al (5) have written good review articles on the medical use of RP.

There has been a steady progression in quality of in vitro models during the past decade, and it is now possible to obtain models and actual replicas of many arterial diseases (6–20). The replicas have been created from a variety of sources, usually fresh cadavers. We have come to distinguish models (created from some idealized system, whether bench top or animal) from replicas (anatomically correct recreations of actual patient anatomy).

Description of the Technique

As part of their normal clinical evaluations, we examined three patients with arterial anomalies on a Lightspeed plus CT

scanner (General Electric Medical Systems, Waukesha, WI). CT angiography at 1.25-mm section thickness, pitch of 1.5–1 at 140 kVp, 350 mA, during injection of 125 mL of ioversol 320 at 4 mL/s yielded basic imaging data in a dicom compatible format. This data were used to develop 3D scans on a Vitrea workstation with software version 3.1 (Fig 1).

We transferred the same data to the Center for Visualization Prototypes, San Diego Supercomputer Center, University of California at San Diego, where one of us (M.J.B.), by using proprietary software, rendered the sections into manufacturable volumes on a prototyping machine (model 402C; Z Corporation, Burlington, MA), which, using its proprietary software, reproduced the vessel lumen in a solid, plaster-like material. A master mold of the lumen replica was created, the plaster positive was removed from the mold, and numerous wax reproductions of the lumen replica were made in the mold (Fig 2). Several of these waxes were coated with a clear silicone elastomer (12), and the wax was then removed thermally and chemically, leaving a replica of the arterial wall (Fig 3).

Artery replicas were placed in a neck-like water bath, the water rendered isoattenuated to the silicone by the addition of ioversol (9 mg iodine/mL). With contrast agent (ioversol at 90 mg iodine/mL) within the replica lumen, we scanned the system with the same parameters as the patient. The data were then sent to the Vitrea workstation, 3D imaging was performed, and the patient image was compared with the replica image (Fig 4), measurements being made at key points.

The second patient had a complex basilar tip aneurysm and was examined with both CT angiography and conventional angiography. The third patient had an abdominal aortic aneurysm (Figs 5 and 6).

We found that making precise measurements on the workstation either from source data or from the reconstructions was difficult. For maximum reproducibility and accuracy, we enlarged the JPEG images of the reconstructions photographically to a large enough size that two observers could make nearly identical measurements of the internal carotid. We then measured the other areas of interest, assumed the internal carotid artery to be a 4-mm vessel, and calculated the comparisons.

Discussion

Visually analyzing the images obtained from the first patient and her replica shows the degree of detail and relationships possible at present. Measurements taken from six regions—the internal carotid artery seven vessel diameters beyond the plaque where arterial walls were parallel, similar to North American Symptomatic Carotid Endarterectomy Trial criteria; the bulb dilatation; through the maximal narrowing; the proximal external carotid artery stenosis; the large posterior ulcer, in its craniocaudal dimension; and the common carotid artery—are shown in Table 1. Measurements, except for the ulcer were taken perpen-

Received May 17, 2004; accepted after revision January 28, 2005.

From the Department of Radiology, University of California at San Diego Medical Center, San Diego, CA.

Address correspondence to Charles W. Kerber, Department of Radiology, University of California at San Diego Medical Center, 200 West Arbor Drive, San Diego, CA 92103.

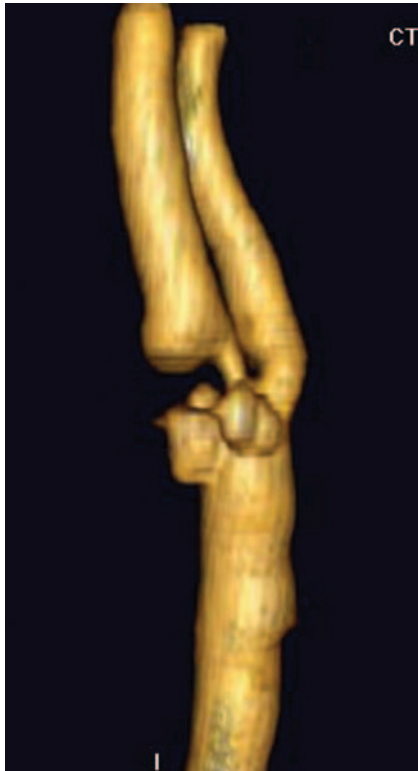

FIG 1. Patient 1. Vitrea workstation reconstruction of right common carotid bifurcation. The high-grade stenosis and multiple proximal complex ulcerations in the bulb are evident.



FIG 2. After reconstruction of the study segment on the Z Corporation RP machine, the plaster-like reproduction of the vessel lumen was used to make a master mold. Here the mold has been opened, revealing the wax model that reproduces the complex configuration and size of the original.



FIG 3. Silicon replica made by the lost-wax technique. This replica was then used to study the flow dynamics of this patient by placing it in a neck phantom and perfusing non-Newtonian fluids while injecting isobaric dyes into the slipstreams (not shown here). The replica was next placed into the scanner, the fluid in the phantom was made isoattenuated to the silicon with contrast agent, and the entire phantom was scanned by using the same scan parameters as were used to scan the patient.

dicular to the long axis of the vessel at the point of measurement.

Figures 5 and 6, images from the third patient with abdominal aortic aneurysm, provide another opportunity to judge the quality of reproduction.

With currently available CT technology, reproductions of live patient pathologic vessels have been created. At present, the time taken for the creation, as well as the energy required, precludes our technique from having immediate clinical use—the *rapid* in the term *rapid prototyping* uses an industrial rather than a medical timescale. But, to recall our history, early CT scans and early MR images were similarly time- and energy-intensive.

Our quest for good simulators began with physiologically inaccurate glass models, progressing through surgically created pathology in live animals, next to more physiologically accurate and lifelike models created from fresh cadavers. This newest step—no longer needing cadaver source material but able to




FIG 4. Workstation 3D reproduction of the CT angiogram made from the replica. These images were then compared with the images in Figure 1. Although there was some slight change in dimensions, and modest smoothing became evident, the overall appearance remained similar.

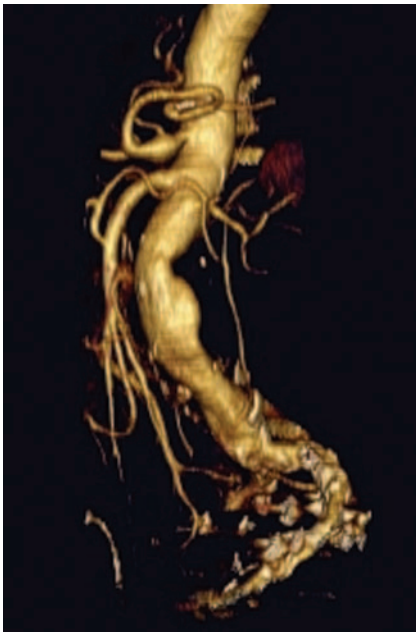

FIG 5. CT angiogram reconstructed on the Vitrea workstation shows the abdominal aortic aneurysm in patient 3.

study the live patient has required, first, access to the advanced imaging capability now routinely found in most departments with the CT scanner and its angiography algorithm and, second, the combination of locally developed and proprietary computer algorithms

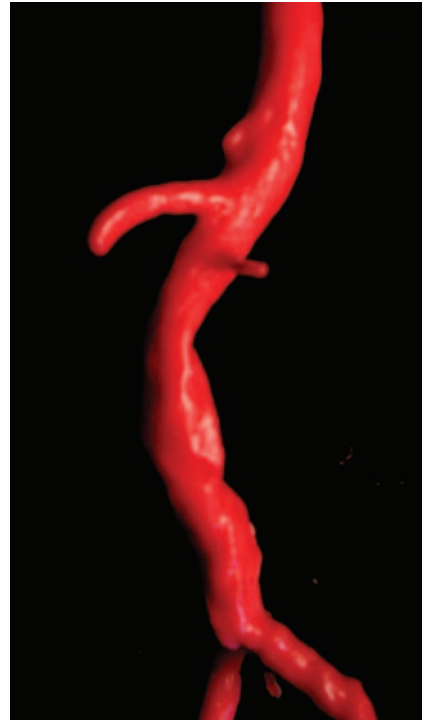

FIG 6. Molded wax replica created from his CT angiographic data.

to drive the stereolithography machine. With this capability, we have been able to reproduce even complex vascular pathology.

The major limitation of our technique appears to be the molding process. Molding complex vascular structures requires an experienced mold maker who is willing to spend time in opening the mold in such way as to allow unskilled labor to make the subsequent waxes. The basic principles of this technique have been described by Liepsch (21) and by Kerber et al (12). This lost-wax technique allows for an almost unlimited number of reproductions to be made, making available to the interventionalist multiple replicas on which to practice.

Conclusion

Creating accurate replicas of arterial pathology in the live patient is feasible, although presently time-consuming and energy-intensive. The replicas created allow physiologically accurate, flow dynamic study of the altered anatomy. In addition, being able to hold a wax replica of the pathology in one's hands, rotating it in any direction desired, allows both surgeons and interventionists to develop a haptic intuition about the best surgical approach, what can be expected when a particular pathology is viewed through the operating microscope or fluoroscope, and what problems to expect. As Petzold et al note, the 3D model "gives the surgeon a realistic impression of complex structures . . . the shift from the visual to the visual-tactical representation . . . introduces a new kind of interaction called "touch to comprehend" (5).

Measurements from six regions

Vessel	Patient vessel, workstation (see Fig 1) in mm	Wax from mold (see Fig 2) in mm	Recreated vessel, workstation (see Fig 4) in mm	Variance, percent, column 1 to column 3 measurement
Internal carotid artery	4.0	4.0	4.0	N/A
Carotid bulb dilatation	5.1	4.7	5.0	-2%
Stenosis, bulb	1.5	1.5	1.7	+12%
External carotid artery	2.4	2.2	2.4	0%
Common carotid artery	5.5	5.6	5.9	+7%
Ulcer, cranio-caudal	4.2	4.2	4.2	0%

Note.—For more accuracy, we enlarged the JPEG images photographically to a point where two observers made nearly identical measurements. We then assumed the internal carotid artery to be a 4 mm vessel, and used that as the baseline comparison for variance.

We expect that, as the techniques are refined and simplified, the availability of arterial replicas will become commonplace, being especially valuable to interventionalists, teachers, and researchers.

References

- Webb PA. A review of rapid prototyping (RP) techniques in the medical and biomedical sector. *J Med Eng Technol* 2000;24:149-153
- Brown GA, Firoozbakhsh K, DeCoster TA, et al. Rapid prototyping: the future of trauma surgery? *J Bone Joint Surg Am* 2003;85-A (suppl 4):49-55
- Potamianos P, Amis AA, Forester AJ, et al. Rapid prototyping for orthopaedic surgery. *Proc Inst Mech Eng [H]*. 1998;212:383-393
- Girod S, Teschner M, Schrell U, et al. Computer-aided 3-D simulation and prediction of craniofacial surgery: a new approach. *J Craniomaxillofac Surg* 2001;29:156-158
- Petzold R, Zeilhofer H, Kalender WA. Rapid prototyping technology in medicine: basics and applications. *Comput Med Imaging Graph* 1999;23:277-284
- Liepsch DW, Zimmer R. The dynamics of pulsatile flow in distensible model arteries. *Technol Health Care* 1995;3:185-199
- Chong BW, Kerber CW, Buxton RB, et al. Blood flow dynamics in the vertebrobasilar system: correlation of a transparent elastic model and MR angiography. *AJNR Am J Neuroradiol* 1994;15:733-745
- Foutrakis GN, Yonas H, Scلابassi RJ. Saccular aneurysm formation in curved and bifurcating arteries. *AJNR Am J Neuroradiol* 1999;20:1309-1317
- Imbesi SG, Kerber CW. Analysis of slipstream flow in a wide-necked basilar artery aneurysm: evaluation of potential treatment regimens. *AJNR Am J Neuroradiol* 2001;22:721-724
- Imbesi SG, Kerber CW. Analysis of slipstream flow in two ruptured intracranial cerebral aneurysms. *AJNR Am J Neuroradiol* 1999;20:1703-1705
- Kerber CW, Heilman CB. Flow dynamics in the human carotid artery: I. Preliminary observations using a transparent elastic model. *AJNR Am J Neuroradiol* 1992;13:173-180
- Kerber CW, Heilman CB, Zanetti PH. Transparent elastic arterial models. I. A brief technical note. *Biorheology* 1989;26:1041-1019
- Kufahl RH, Clark ME. A circle of Willis simulation using distensible vessels and pulsatile flow. *J Biomech Eng* 1985;107:112-122
- Liepsch D. An introduction to biofluid mechanics: basic models and applications. *J Biomech* 2002;35:415-435
- Liepsch D, Moravec S, Baumgart R. Some flow visualization and laser-Doppler-velocity measurements in a true-to-scale elastic model of a human aortic arch: a new model technique. *Biorheology* 1992;29:563-580
- Mijovic B, Liepsch D. Experimental flow studies in an elastic Y-model. *Technol Health Care* 2003;11:115-141
- Reul H. Cardiovascular simulation models. *Life Support Syst* 1984;2:77-97
- Sugiu K, Martin JB, Jean B, et al. Artificial cerebral aneurysm model for medical testing, training, and research. *Neurol Med Chir (Tokyo)* 2003;43:69-72; discussion 73
- Yedavalli RV, Loth F, Yardimci A, et al. Construction of a physical model of the human carotid artery based upon in vivo magnetic resonance images. *J Biomech Eng* 2001;123:372-376
- Gailloud P, Muster M, Piotin M, et al. In vitro models of intracranial arteriovenous fistulas for the evaluation of new endovascular treatment materials. *AJNR Am J Neuroradiol* 1999;20:291-295
- Liepsch D. Fundamental flow studies in models of human arteries. *Front Med Biol Eng* 1993;5:51-55