

## Case Report

# Application of Transcranial Doppler Sonography in Children with Acute Neurologic Events due to Primary Cerebral and West Nile Vasculitis

Lisa H. Lowe, Frank P. Morello, Mary A. Jackson, and Andrew Lasky

**Summary:** We describe the use of serial transcranial Doppler studies to evaluate neurovascular disease in three girls presenting with acute stroke due to primary cerebral vasculitis ( $n = 2$ ) and West Nile vasculitis ( $n = 1$ ). Correlation of abnormal findings on transcranial Doppler sonography was compared with those of MR angiography and conventional angiography in each child. All three girls had left middle cerebral artery infarcts on MR imaging, with an abnormal left middle cerebral artery detected by MR angiography, conventional angiography, and transcranial Doppler sonography in each child. In all three cases, findings of the transcranial Doppler sonography, MR imaging, and catheter angiography were concordant.

The use of transcranial Doppler sonography is well established in the evaluation of many neurovascular conditions ranging from sickle cell vasculopathy to brain death. However, its use in cerebral vasculitis is less well documented, particularly in the pediatric population (1–3). Cerebral vasculitis (or small-vessel vasculopathy) presents most often with headache or acute stroke. Although these causes are rare in children, cerebral vasculitis can be due to postinfectious, autoimmune, idiopathic causes; connective tissue disorders; or hypercoagulable states (4). Furthermore, to our knowledge, cerebral vasculitis with acute stroke due to West Nile virus has never been previously reported in the pediatric population (5–7). Anatomical vascular changes are best characterized with conventional catheter angiography or MR angiography, procedures that can be invasive and may require sedation (8). Adjunctive performance of transcranial Doppler sonography provides physiologic information regarding neurovascular velocity measurements, which are not available using other radiologic procedures.

Received September 30, 2004; accepted after revision October 12.

From the Departments of Radiology (L.H.L., F.P.M.), Infectious Diseases (M.A.J.), and Rheumatology (A.L.), Children's Mercy Hospitals & Clinics, University of Missouri–Kansas City, 2401 Gillham Road, Kansas City, MO 64108.

Presented at the annual meeting of the American Society of Neuroradiology, Seattle, June 2004.

Address correspondence to Lisa H. Lowe, Department of Radiology, Children's Mercy Hospitals & Clinics, University of Missouri–Kansas City, 2401 Gillham Road, Kansas City, MO 64108 (e-mail: lhlowe@cmh.edu or lhl@kc.rr.com).

Aggressive therapy is implemented with the goal of preventing recurrence or progression of stroke, and treatment may include aspirin, high-dose steroids, and cyclophosphamide (9). Because progression of stroke or recurrent stroke is the only measure of failed therapy or worsening disease, monitoring these children closely with transcranial Doppler sonography is useful (1, 2).

## Case Reports

### Case 1

A 7-year-old girl presented with headache, right hemiparesis, aphasia, and facial droop. History and physical examination were remarkable only for findings consistent with acute stroke. Findings of emergent outside CT without contrast material were normal. Acute left middle cerebral artery stroke was identified the following day with MR imaging performed at 1.5T (spin-echo sagittal and axial T1-weighted, axial T2-weighted, coronal fluid-attenuated inversion recovery, axial diffusion-weighted b-1000 images, and apparent diffusion coefficient mapping). Standard 3D time-of-flight MR angiography (TR/TE, 45/5.8 or 5; section thickness, 0.8 or 1 mm) and transcranial Doppler sonography (5.3- and 4.2-MHz phased-array transducers, transtemporal approach, color and spectral Doppler without angle correction) were also performed, followed by conventional angiography 2 days after presentation. Findings of MR angiography, transcranial Doppler sonography, and conventional angiography were all abnormal in the left middle cerebral artery and internal carotid artery distributions. Transcranial Doppler sonography revealed increased peak systolic velocities, whereas MR and conventional angiography demonstrated vascular irregularity (Fig 1). Left anterior cerebral artery disease was detected on MR and conventional angiography, but not on transcranial Doppler sonography. Results of evaluation for infection (sedimentation rate, C-reactive protein, white blood cell count), collagen vascular disease, hypercoagulable states, and other conditions that may predispose to stroke or vasculitis were unremarkable. A diagnosis of primary (idiopathic) cerebral vasculitis was made, and treatment initially included aspirin, steroids, and cyclophosphamide. A gradual decrease in peak systolic velocity was observed on transcranial Doppler sonography over 28 months, which correlated with improvement on MR and conventional angiography. Cyclophosphamide was stopped February 2002; the child was weaned from steroids June 2002 and is stable without recurrent stroke after 36 months of clinical follow-up.

### Case 2

A 12-year-old girl presented with headache, slurred speech, nausea, and vomiting. As in the first case, history and physical examination were unremarkable other than findings related to

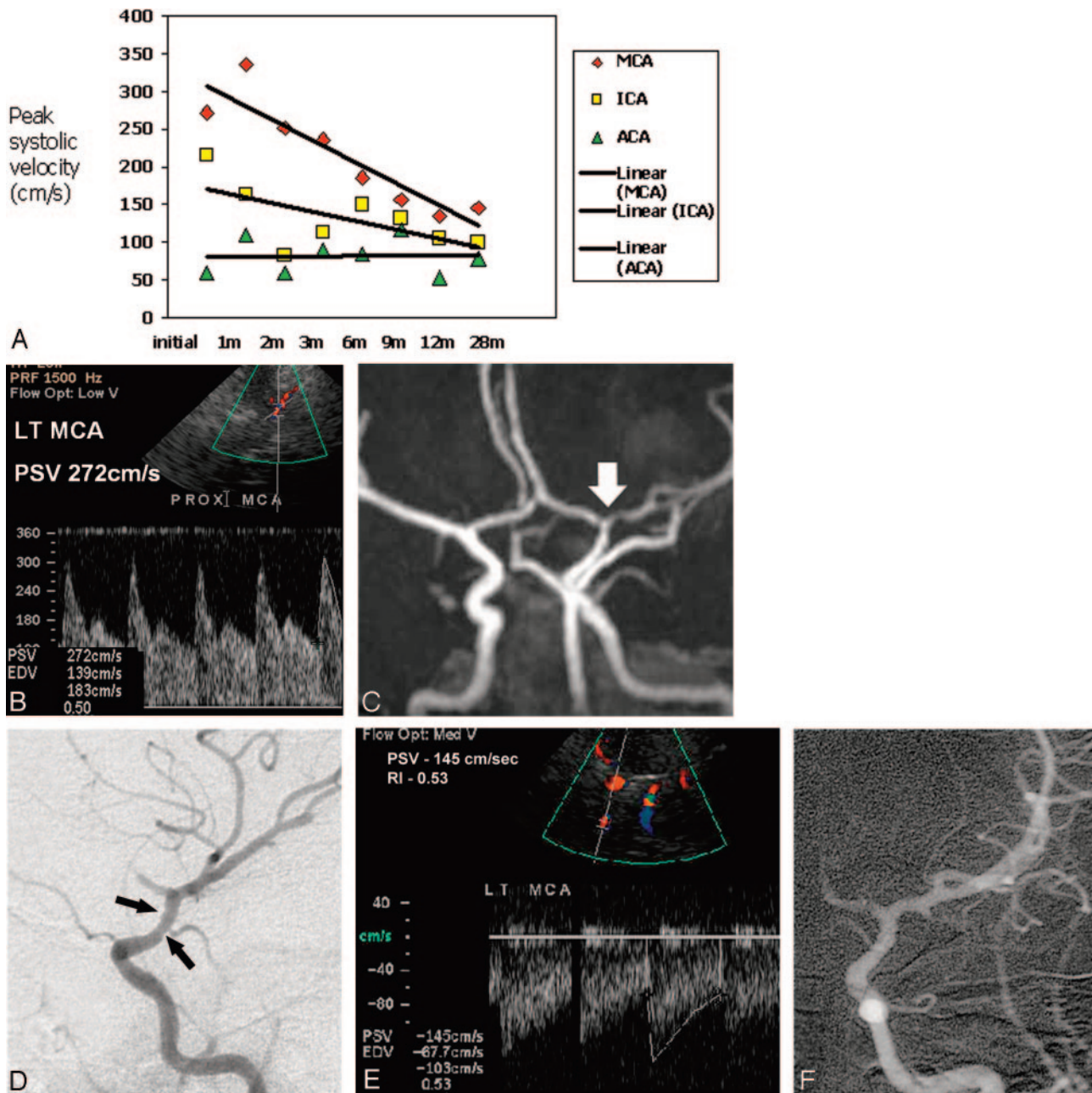


FIG 1. Primary cerebral vasculitis in a 7-year-old girl. PSV indicates peak systolic velocity; MCA, middle cerebral artery; ICA, internal carotid artery, ACA, anterior cerebral artery. (A) Graph of transcranial Doppler sonography results plotted for 28 months show gradual improvement in all left-sided vessels. Note variation of individual measurements compared with trends over time. (B) Transcranial Doppler sonography spectrum shows elevated peak systolic velocities in the left MCA. (C) MR angiogram reveals decreased caliber of slightly irregular distal left ICA, A1 segment of the ACA, and M1 of the MCA (arrow). (D) Catheter angiogram obtained 2 days after initiation of therapy demonstrates slight narrowing and irregularity of the distal ICA (arrows). (E) Twenty-eight-month follow-up transcranial Doppler sonogram and (F) catheter angiogram show that the PSV and anatomical appearance of the vessels have returned to near normal.

acute stroke suggested by outside CT and confirmed with MR imaging the following day. MR angiography and transcranial Doppler sonography were also performed, followed by conventional angiography 2 days after presentation. Findings of transcranial Doppler sonography, MR angiography, and conventional angiography were all abnormal in the left middle cerebral artery, internal carotid artery, and anterior carotid artery distributions, showing increased peak systolic velocity and vascular irregularity (Fig 2). Results of evaluation for infection (sedimentation rate, C-reactive protein, white blood cell count), collagen vascular disease, hyperco-

agulable states, and other conditions that may predispose to stroke or vasculitis were unrevealing, and primary cerebral vasculitis was diagnosed. Treatment included aspirin, steroids, and cyclophosphamide. On serial transcranial Doppler studies performed over 14 months, peak systolic velocities in the anterior carotid artery and internal carotid artery returned to normal, but abnormally elevated velocities in the middle cerebral artery persisted. Cyclophosphamide and prednisone were stopped March 2004 and June 2004, respectively. After 18 months of clinical follow-up, the child is stable without medication or recurrent stroke.

FIG 2. Primary cerebral vasculitis in a 12-year-old girl. Graph of transcranial Doppler sonography results plotted for 14 months demonstrates some improvement in the left internal carotid artery (ICA) and anterior cerebral artery (ACA) but persistent disease in the left middle cerebral artery (MCA).

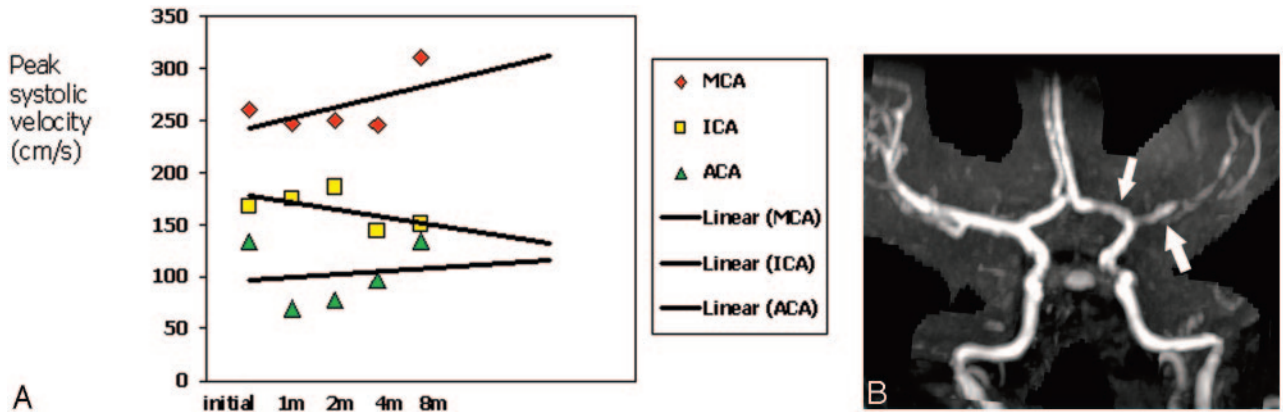
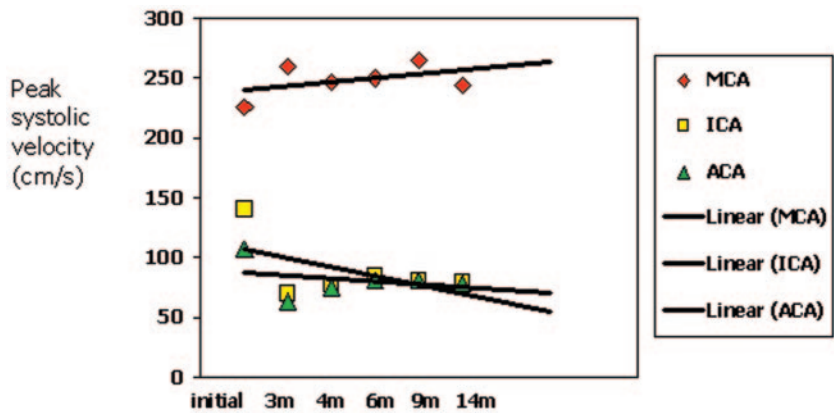


FIG 3. West Nile vasculitis in a 9-year-old girl. MCA indicates middle cerebral artery; ICA, internal carotid artery; ACA, anterior cerebral artery. (A) Graph of transcranial Doppler sonography results plotted for 8 months reveal persistence of elevated peak systolic velocity in the left MCA, ACA, and ICA. (B) MR angiogram reveals decreased caliber and irregularity of the left MCA with slight narrowing of the supraclinoid ICA and A1 segment of the ACA (arrows).

Case 3

A 9-year-old girl presented with a 4-day history of headache, right arm and right leg weakness, and acute aphasia. Similar to the first two cases, history and physical examination were unremarkable other than findings related to acute left middle cerebral artery distribution stroke suggested by CT and confirmed with MR imaging. MR angiography and transcranial Doppler sonography were also performed, followed by conventional angiography 7 days after presentation. Findings of transcranial Doppler sonography (Fig 3), MR angiography, and conventional angiography were all abnormal in the left middle cerebral artery, internal carotid artery, and anterior carotid artery distributions, revealing increased peak systolic velocity and vascular irregularities. At the time of admission, acellular cerebrospinal fluid was noted, polymerase chain reaction study was negative for Herpes simplexvirus and enterovirus, and results of routine bacterial and viral cultures of cerebrospinal fluid were negative as well. The results of evaluation for infection (sedimentation rate, C-reactive protein), collagen vascular disease, hypercoagulable states, and other conditions that may predispose to stroke or vasculitis were otherwise normal. A definitive diagnosis was made 6 days into the hospital course when West Nile virus immunoglobulin M and G antibodies were detected in the cerebrospinal fluid by ELISA testing (IgM 2.79 [normal range, 0–0.9], IgG 1.38 [normal range, 0–0.9]). Similarly, serum IgM and IgG levels obtained 1 week later and then 1 month after the initial diagnosis were elevated. Treatment initially included aspirin, steroids, and cyclophosphamide. On serial transcranial Doppler sonography, peak systolic velocity suggested some early improvement but remained elevated on subsequent examinations during an 8-month follow-up pe-

riod. Cyclophosphamide and steroids were discontinued in July 2004 and April of 2004, respectively. The child is stable on daily aspirin and has not had recurrent stroke after 19 months of clinical follow-up.

Discussion

West Nile encephalopathy, transmitted by mosquitoes and rarely transfusions, is well known. Only recently have reports of neurovascular complications begun to be documented, including those of a 46-year-old man with retinal artery occlusive vasculitis and an adult patient presenting with acute stroke (5–7). Although evaluation of vasculitis with transcranial Doppler sonography is reported in adults (particularly in Takayasu arteritis), it not as well known in children (1, 10).

Unique to this study are the application of transcranial Doppler sonography to evaluate pediatric vasculitis, the comparison over time of the transcranial Doppler findings to MR angiography and conventional angiography, and the documentation of a pediatric patient presenting with acute stroke due to West Nile virus.

Similar to those in prior studies, peak systolic velocities obtained in the middle cerebral and internal carotid arteries were more reliable than those obtained from the anterior cerebral arteries; this finding

may be due to the close proximity of the right and left anterior cerebral arteries, making individual distinction of each vessel difficult (11). Conventional angiography and MR angiography were more likely to definitively demonstrate anterior carotid artery disease than transcranial Doppler sonography in our limited series. Specifically, although angiography findings were abnormal in the anterior carotid artery on the initial evaluation of case 1, the transcranial Doppler findings were normal. In the same case, the plotted peak systolic velocity measurements of the anterior carotid artery were noted to vary more than those of the internal carotid artery and middle cerebral artery.

In all three girls, trends toward improvement versus persistent disease found with transcranial Doppler sonography correlated with those of MR angiography and conventional angiography. On transcranial Doppler sonography, these trends were best demonstrated over a series of examinations rather than on evaluation of a single peak systolic velocity measurement, as has been previously noted in the adult literature (12). The ability of transcranial Doppler sonography to predict trends found on MR angiography and conventional angiography in children with cerebral vasculitis may allow frequent evaluation of neurovascular velocities during acute and follow-up stages of evaluation.

## References

1. Cantu C, Pineda C, Barinagarrementeria F, et al. **Noninvasive cerebrovascular assessment of Takayasu arteritis.** *Stroke* 2000;31:2197-2202
2. Morgenlander JC, McCallum RM, Devlin T, et al. **Transcranial Doppler sonography to monitor cerebral vasculitis.** *J Rheumatol* 1996;23:561-563
3. Razumovsky AY, Wityk RJ, Geocadin RG, et al. **Cerebral vasculitis: diagnosis and follow-up with transcranial Doppler ultrasonography.** *J Neuroimaging* 2001;11:333-335
4. Sarwar H, McGrath H Jr, Espinoza LR. **The differential diagnosis of central nervous system lupus has expanded.** *Lupus* 2003;12:422
5. Kaiser PK, Lee MS, Martin DA. **Occlusive vasculitis in a patient with concomitant West Nile virus infection.** *Am J Ophthalmol* 2003;136:928-930
6. Armstrong WS, Bashour CA, Smedira NG, et al. **A case of fatal West Nile virus meningoencephalitis associated with receipt of blood transfusions after open heart surgery.** *Ann Thorac Surg* 2003;76:605-607
7. Kulstad EB, Wichter MD. **West Nile encephalitis presenting as a stroke.** *Ann Emerg Med* 2003;41:283
8. Wiznitzer M, Masaryk TJ. **Cerebrovascular abnormalities in pediatric stroke: assessment using parenchymal and angiographic magnetic resonance imaging.** *Ann Neurol* 1991;29:585-589
9. Baca V, Lavalle C, Garcia R, et al. **Favorable response to intravenous methylprednisolone and cyclophosphamide in children with severe neuropsychiatric lupus.** *J Rheumatol* 1999;26:432-439
10. Ameriso S, Bernard JT, Weaver F, Fisher M. **"Pulseless" transcranial Doppler findings in Takayasu's arteritis.** *J Clin Ultrasound* 1990;18:592-596
11. Wozniak MA, Sloan MA, Rothman MI, et al. **Detection of vasospasm by transcranial Doppler sonography: the challenges of the anterior and posterior cerebral arteries.** *J Neuroimaging* 1996;6:87-93
12. Giller CA, Lam M, Roseland A. **Periodic variations in transcranial Doppler mean velocities.** *J Neuroimaging* 1993;3:160-162