

Are your MRI contrast agents cost-effective?

Learn more about generic Gadolinium-Based Contrast Agents.



FRESENIUS  
KABI

caring for life

**AJNR**

## Bioimaging in Neurodegeneration

*AJNR Am J Neuroradiol* 2005, 26 (8) 2161-2162  
<http://www.ajnr.org/content/26/8/2161>

This information is current as  
of April 23, 2024.

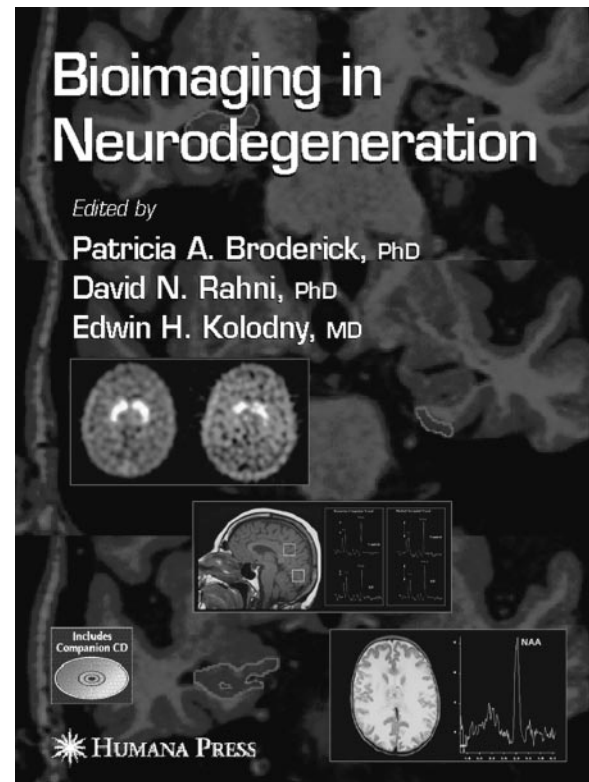
***Bioimaging in Neurodegeneration***

edited by Patricia A. Broderick, David N. Rahni, and Edwin H. Kolodny. Totowa, NJ: Humana Press; 2005. 313 pages, \$165.00

One should not judge a book by its title, and this is absolutely the case for *Bioimaging in Neurodegeneration*, edited by Broderick, Rahni, and Kolodny. “Bioimaging” suggests that the book contains a substantial number of images that directly or indirectly capture biologic processes. “Neurodegeneration” implies that a variety of heterogeneous central nervous system diseases that share one unifying pathologic process—namely, progressive neuronal damage or death—will be discussed. Combining the terms would lead one to expect to learn about the rapidly advancing knowledge of pathogenesis, treatment, and state-of-the-art imaging of a variety of neurodegenerative diseases in the context of a comprehensive survey of each disease, as well as its clinical features and therapeutic modalities, standard and experimental imaging techniques for early detection, monitoring of therapeutic response, and assessing short- and long-term prognosis of patients. This volume, however, delivers only marginally on what its title suggests, in that it unacceptably lacks sufficient images pertaining to bioimaging, the subject of neurodegenerative disease is inadequately covered, and a large portion of the book covers diseases that are not properly considered neurodegenerative.

The misleading nature of this book is not limited to the title; it is also seen within individual chapters. The title of chapter 1, “Magnetic Resonance (MR) Imaging and MR Spectroscopy in Parkinson’s Disease (PD),” would lead the reader to anticipate at least one—and possibly more—MR spectroscopic image of PD, but none are present. Instead, the chapter contains 5 anatomic MR images of a patient with progressive supranuclear palsy. Another example is chapter 7, “Functional Imaging and Psychopathological Consequences of Inflammation in Alzheimer’s Dementia.” Other than one schematic cartoon image (Fig 1), there is not a single CT, MR, or radioisotope image that corresponds to the text. Furthermore, throughout the book most images are either reprints from previously published books or journals or anatomic MR images. Again, there is a distinct paucity of illustrations, especially of bioimaging and the overall quality of images in the book is fair to poor.

The book is organized into 4 main sections—PD, Alzheimer’s disease (AD), epilepsy, and leukodystrophy—with 5–7 relatively short chapters in each section. The first 2 sections are focused on the application of positron-emission tomography (PET) and single photon emission CT (SPECT) imaging methods in PD and AD for early detection and monitoring disease progression. The third section deals with imaging of epilepsy, including a brief overview of surgical treatment and the role of intraoperative MR scan-



ning. The fourth and final section covers a hodgepodge of topics on leukodystrophies and mitochondrial/storage diseases with illustrations mostly of anatomic but also of single-voxel spectroscopic MR images. There are 3 editors and 49 contributing authors for a total of 23 chapters in this book.

The overall organization of the book lacks natural flow, cohesiveness, and careful editing. Section I, on PD, starts with MR imaging and MR spectroscopy of PD without any pertinent images of PD followed by 4 consecutive chapters on PET imaging of PD. Similarly section II, on AD, includes a confusing mixture of 5 chapters that deal with volumetric anatomic MR imaging of hippocampus to postmortem studies of AD. Section III, on epilepsy, contains chapters that are poorly interconnected and edited. Section IV, on leukodystrophy, a primary disease of myelin and not of neurons, seems completely out of place and is included as one of the major categories of neurodegenerative disease when other important neurodegenerative diseases such as dementias, prion diseases, neurodegenerative ataxias, motor neuron diseases, degenerative diseases with chorea, and iron and copper disorders are completely missing from the book. Even the inclusion of epilepsy as an entire section in this book seems odd and out of place.

The book reads more like a collection of original or review journal articles hastily collected and forced into a single category of bioimaging in neurodegenerative diseases. In fact, chapters 13 and 15 are written in the same format as a journal article. There are several chapters with the word "imaging" in the title (eg, chapters 7, 13, 17, and 23) in which there are absolutely no images at all. The overall design of the book may have intended to give researchers in the neuroscience, psychiatry, or molecular imaging fields an overview of the conventional and experimental imaging techniques to plan their in vivo research projects. The content of the book, however, is only partially relevant to such research scientists and may not be appropriate or relevant to clinical neuroradiologists. The book lacks relevant background information on clinical and pathophysiologic features of neurodegenerative diseases and comprehensive overview in current standard imaging methods, as well as rapidly evolving biology-based imaging methods such as receptor ligand-based imaging techniques by using PET and SPECT.

Although the book's main bioimaging methods are PET and SPECT modalities, the major areas essential to in vivo biochemical studies with PET and SPECT—synthesis of radiopharmaceuticals, biologic modeling, and clinical applications—are incomplete at best and entirely missing in most chapters. The third and fourth section on epilepsy and leukodystrophy, respectively, do not seem to fit in with the first 2 parts and in fact the leukodystrophy section seems at odds with the main theme of the book—namely, imaging of brain disease with specific biomarkers. The leukodystrophy section is similar in content and organization to any other general neuroradiology textbook and, aside from a few single-voxel MR spectroscopic images, the rest are conventional anatomic images with which we are all familiar from other more comprehensive neuroradiology textbooks.

In summary, *Bioimaging in Neurodegeneration* is a

book with a promising title, but it delivers poorly on content and substance. I do not recommend this book to neuroradiologists and suggest it only with modest enthusiasm to research scientists studying PET and SPECT imaging of PD or AD. There is a limited amount of new and practical information on neuro-radiology one can derive from the book. The book is also of limited value for research scientists with special interest in PET/SPECT imaging methods for in vivo ligand imaging, because of the lack of in-depth overview of the imaging methodology such as instrumentation and image analysis, biologic modeling and compartment kinetics, and pharmacokinetics of dopamine and other transmitter enzymes.

The editors boldly state in the preface that this book "fulfills the current need to bring together neurodegeneration with bio- and neuroimaging technologies that actually enable diagnosis and treatment." Yet, after I have read the book, most experimental imaging modalities it presents seem far from close to being incorporated into a practical and reliable clinical imaging protocol for early detection and differentiation of many different types of neurodegenerative disease.

Readers interested in learning more about imaging of neurodegenerative diseases would do better to consult any of the following 4 books: *Neurodegenerative Diseases: Neurobiology, Pathogenesis and Therapeutics*, by M. Flint Beal, Anthony E. Lang, and Albert C. Ludolph (Cambridge, England: Cambridge University Press, 2005); *Radiopharmaceuticals and Brain Pathophysiology Studied with PET and SPECT*, edited by Mirko Diksic and Richard C. Reba (Boca Raton, FL: CRC Press, 1991); *Physiologic Imaging of the Brain with PET*, by Albert Gjedde, Soren B. Hansen, Gitte M. Knudsen (London: Academic Press, 2000); and *Brain Imaging Using PET*, by Michio Senda, Yuichi Kimura, and Peter Herscovitch (London: Academic Press, 2002).