Are your MRI contrast agents cost-effective?
Learn more about generic Gadolinium-Based Contrast Agents.
FRESENIUS KABI
caring for life

AJNR

Direct Visualization of the Human Subthalamic Nucleus with 3T MR Imaging

K.V. Slavin, K.R. Thulborn, C. Wess and H. Nersesyan

AJNR Am J Neuroradiol 2006, 27 (1) 80-84
http://www.ajnr.org/content/27/1/80

This information is current as of April 19, 2024.

ORIGINAL RESEARCH

Direct Visualization of the Human Subthalamic Nucleus with 3T MR Imaging

K.V. Slavin
K.R. Thulborn
C. Wess
H. Nersesyan

BACKGROUND AND PURPOSE: Electrical stimulation of the subthalamic nucleus (STN) is an accepted treatment for advanced Parkinson disease (PD). Although procedural details are well established, targeting STN remains problematic because of its variable location and relatively small size (20–30 mm^3). A combination of anatomic imaging with a stereotactic frame, atlas coordinates, and intraoperative neurophysiology is currently considered the most reliable approach for STN targeting. CT imaging is dependent on atlas coordinates, because the STN is not visualized. The STN is also difficult to visualize directly by using MR imaging at 1.5T.

METHODS: We performed preoperative stereotactic MR imaging at 3T to visualize the STN in 13 patients undergoing deep-brain stimulation for PD. With the patient positioned within a standard Leksell type G stereotactic frame localizer, rapidly acquired scout images are used to prescribe volumes of contiguous high-resolution T2-weighted fast spin-echo images in the axial, sagittal, and coronal planes through the midbrain and basal ganglia. The STN is identified in all 3 planes by cross-referencing in a 3-plane viewer. These coordinates are used for surgical targeting.

RESULTS: At 3T, the STN was visualized as a small, hypointense, almond-shaped structure in 3 planes located immediately lateral to the anterior edge of the red nucleus, medial to the internal capsule, about 5 mm inferior, 1–2 mm posterior, and 9–12 mm lateral to the midcommissural point. Intraoperative microelectrode recordings confirmed these coordinates in all cases from the first microelectrode pass, thereby eliminating prolonged intraoperative electrophysiological STN searching and tissue disruption that may occur from multiple passes.

CONCLUSION: 3T MR imaging appears to be an excellent tool for reliable and accurate direct visualization of the human STN, necessary for precise surgical targeting.

As clinical experience with deep-brain stimulation (DBS) of the subthalamic nucleus (STN) in treatment of advanced Parkinson disease (PD) increases and the procedure becomes more accepted among neurologists, neurosurgeons, and patients, more attention is being paid to the accuracy of surgical targeting[1,2] to decrease morbidity associated with this operative procedure.[3,4] The protocols vary significantly from center to center.[5-7] Some routinely perform ventriculography,[8,9] whereas others use fusion of MR and CT images.[2,5] Few centers use MR imaging alone to calculate anatomic targets.[6,10,11] With regard to the physiologic localization, intraoperative macrostimulation is enhanced in many centers by microelectrode recording (MER).[2,10] To delineate the borders of the STN precisely, the insertion of 5 microelectrodes simultaneously has been advocated,[8] with repeated MER (making as many as 10 parallel passes) if more information is required. The need for this time-consuming (and definitely more traumatic) protocol is justified by the high variability of the human STN location in individual patients relative to the established anatomic landmarks (eg, anterior and posterior commissures) and relative to widely accepted anatomic atlases by using other stereotactic targets (eg, ventral intermedius nucleus of the thalamus or internal segment of the globus pallidus).[12-15]

Continuous advances in MR technology increase resolution and precision of this imaging technique. Clinical 3T scanners now enable clinicians to obtain high-resolution images of the deep cerebral structures in multiple projections for use in targeting the STN.[16,17] This approach directly visualizes the STN and allows targeting without the use of atlases and predetermined landmark-based coordinates. Such customized targeting for individual patients reduces uncertainty of initial localization and subsequently eliminates any need for multiple passes of the microelectrode through this small cerebral region.[13] Our experience with the use of 3T MR imaging for STN localization is described below.

Received March 10, 2005; accepted after revision June 6.

From the Department of Neurosurgery (K.V.S., C.W., H.N.) and the Magnetic Resonance Research Center (K.R.T.), University of Illinois at Chicago, Chicago, Ill.

Address correspondence to Konstantin V. Slavin, MD, Department of Neurosurgery, University of Illinois at Chicago, 912 South Wood St, M/C 799, Chicago, IL 60612.

Methods

Frame-based stereotactic neurosurgical procedures were performed with 3T MR imaging–based planning in 40 procedures during the period 2001–2004. In 13 cases in which STN was the ultimate target of the surgery, the STN location determined from MR imaging was verified by using single-cell MER during an intraoperative mapping session. The patients included 8 men and 5 women whose ages ranged from 33 to 76 years (mean, 60 years; median, 63 years). The Leksell stereotactic frame type G (Elekta Instruments, Atlanta, Ga) was applied to each patient immediately before MR imaging with the frame balanced appropriately by using ear bars. The MR localizer was attached to the frame for coordinate calculation. The scanning was done on 3T Signa MR scanner (Signa 3T94 VHi; General Electric Medical Systems, Milwaukee, Wisc) with the following protocol.

A rapid 3D image localizer covering the entire brain was used to prescribe volumes of high-resolution, contiguous, T2-weighted, fast spin-echo imaging (section thickness, 1.5 mm; matrix size, 512×512; field of view, 26 cm^2; TR, 4600–6200 milliseconds; TE, 95–108 milliseconds; acquisition time, <5 minutes). TR values varied for different patients and for each of 3 planes, whereas all other imaging parameters remained constant throughout the study. The images were acquired in the axial, sagittal, and coronal planes through the region of the midbrain and basal ganglia. Spe-

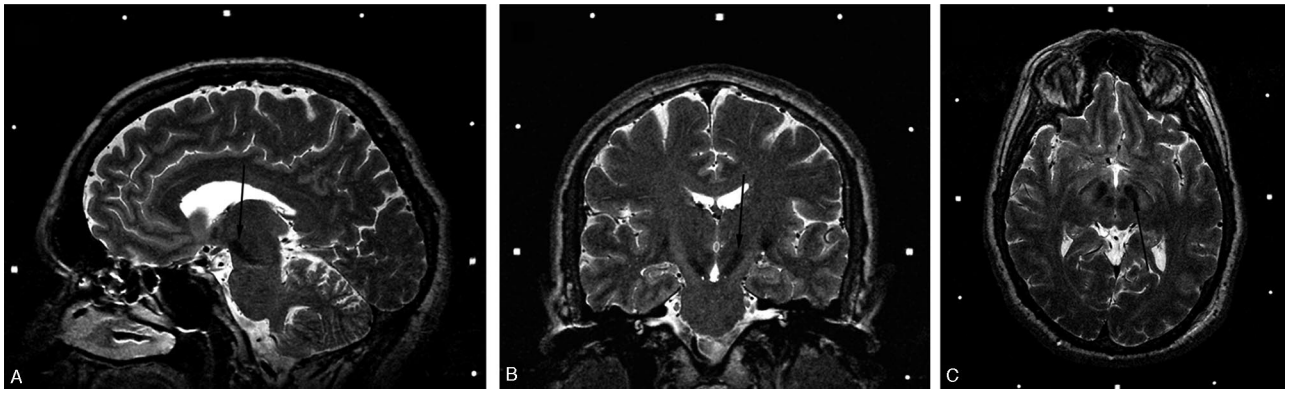

Fig 1. T2-weighted fast spin-echo images in the sagittal (*A:* TR, 6200 milliseconds; TE, 108 milliseconds), coronal (*B:* TR, 5650 milliseconds; TE, 95 milliseconds), and axial (*C:* TR, 6117 milliseconds; TE, 95 milliseconds) planes through the subthalamic nucleus. The stereotactic target is marked with a black *arrow*.

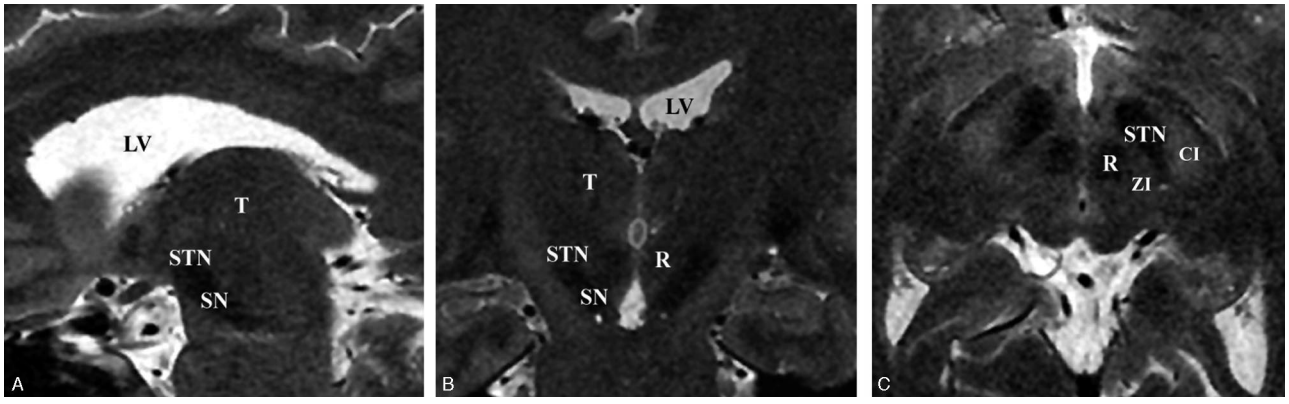

Fig 2. Magnified area of interest from Fig 1 in the sagittal (*A*), coronal (*B*), and axial (*C*) planes. R, red nucleus; SN, substantia nigra; ZI, zona incerta; CI, capsula interna; T, thalamus; LV, lateral ventricle; STN, subthalamic nucleus.

cial attention was paid to visualize the red nucleus, substantia nigra, and anterior (AC) and posterior commissures (PC). The images were then examined on a PACS (GE Healthcare) to allow cross-referencing in 3 planes. The coordinates of the center of the STN were established once it was visualized on all 3 planes. These coordinates were translated into stereotactic frame space by using a simple series of calculations.

After MR imaging, the patients were taken directly to the operating room, where intraoperative MER was performed by using the MicroGuide MER system (Nicolet Biomedical, Madison, Wisc). A single microelectrode setup was used in each case, with recording started 25 mm above the target point and continued all the way to 5 mm below the target. By using various on-line analysis tools,[18] the pattern of discharge, frequency, shape, and amplitude of discharges was analyzed as neurons were encountered while the microelectrode was advanced. After delineation of STN superior and inferior borders along the track, the microelectrode was replaced with a stimulation electrode for a trial of macrostimulation. On the basis of the results of stimulation, the proximity of motor pathways was defined and, subsequently, a final position and depth of insertion for permanent electrode were chosen.

Each patient was clinically evaluated during the immediate postoperative period while the electrodes remained externalized and then again after internalization of the system. In each case, changes in Parkinsonian symptoms with STN stimulation were evaluated by an independent neurologist.

Results

Total time in 3T scanner was <30 minutes with an even shorter image-acquisition time. The 26-cm^2 field of view provided excellent visualization of all 12 markers of the MR localizer that was attached to the stereotactic frame. This information was necessary for correct stereotactic coordinate calculations after the anterior and posterior commissures were identified and the coordinates of midcommissural point were recorded for target referencing.

In all patients who underwent stereotactic MR imaging at 3T, we were able to visualize the STN (Figs 1 and 2). It was seen as a small almond-shaped entity about 6 mm in maximal dimension that was hypointense (dark) on T2-weighted sequences. The longest axis of STN was aimed from medial-ventral-posterior to lateral-dorsal-anterior. This structure was located immediately lateral to the anterior aspect of the red nucleus in the axial plane, medial to the internal capsule, and dorsal to the substantia nigra (Fig 2). Mean coordinates for the center-of-left STN throughout our series were 4.7 ± 1.9 mm inferior, 1.1 ± 2.3 mm posterior, and 11.4 ± 1.3 mm lateral of the midcommissural point. Mean coordinates for the center-of-right STN throughout our series were 5 ± 1.7 mm inferior, 0.6 ± 1.8 mm posterior, and 11.5 ± 0.9 mm lateral of the midcommissural point. In all cases, the MR imaging–calculated coordinates of STN on both sides were confirmed with intraoperative MERs (Fig 3). In addition, the correct place-

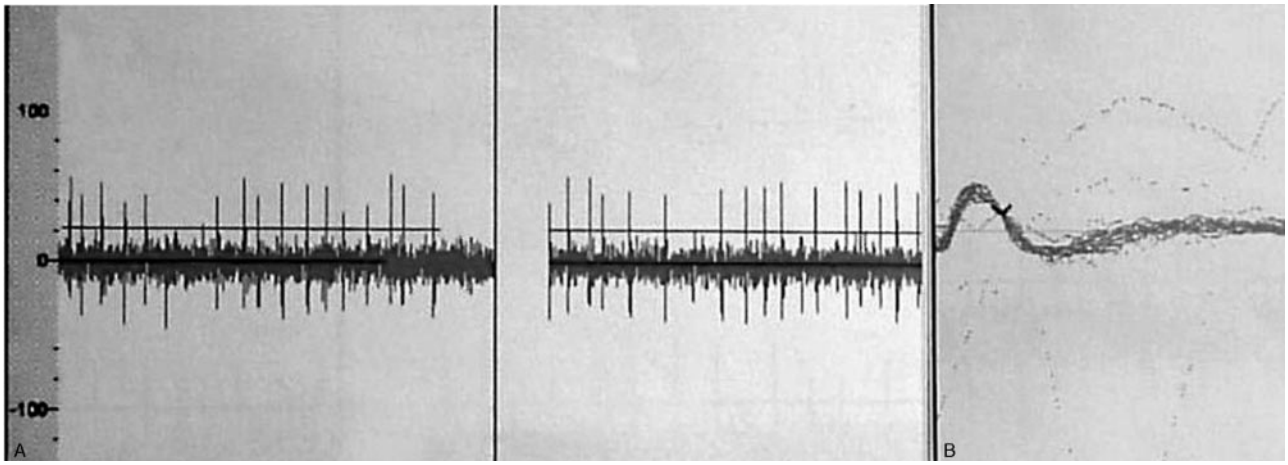

Fig 3. Sample intraoperative microelectrode recording from a single neuron at the center of the STN calculated with preoperative 3T MR imaging. *A,* Real-time electrophysiologic recording. *B,* Single-cell spike registration screen.

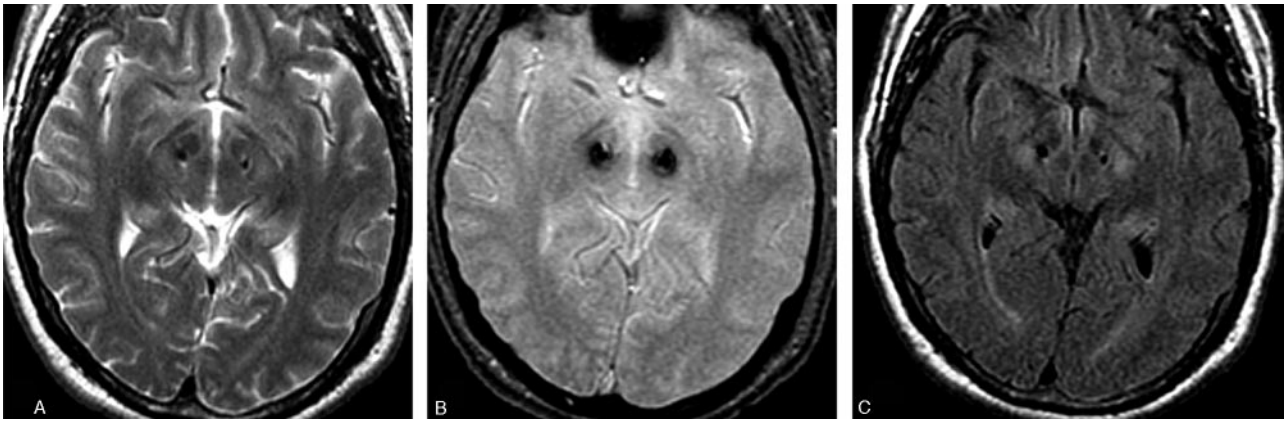

Fig 4. MR imaging in early follow-up period after the placement of deep-brain stimulation electrode in the STN documented at 1.5T. *A,* T2-weighted fast spin-echo image. *B,* Gradient recalled echo image. *C,* Fluid-attenuated inversion recovery image. The susceptibility artifacts from the electrodes are obscuring the STN contours.

ment of the electrodes was confirmed in all cases with postoperative MR imaging performed in a 1.5T scanner during early follow-up (Fig 4). For the sake of safety, 1.5T MR imaging was used, because the electrodes have not yet been extensively tested for 3T MR imaging compatibility.

MER revealed the electrophysiologic characteristics of the STN neuronal activity on the first pass of the microelectrode in all 13 cases (26 operated sides). The distinct difference in signal intensity pattern observed upon microelectrode entrance into STN (Fig 3) was noted 2–4 mm short of the target location and persisted for 4–6 mm until replaced by a "quiet" zone. In 2 cases, further advancement of the microelectrode resulted in penetration of the substantia nigra.

In 23 of 26 trajectories, macrostimulation did not indicate a low threshold of motor response, which is suggestive of inappropriate proximity to the corticospinal and corticobulbar tracts. In the other 3 cases, the microelectrode had to be reinserted into a more medial location. In all patients, stimulation at the MER-determined center of STN resulted in neurologic improvement, particularly of tremor and rigidity, but its degree varied from patient to patient.

Discussion

Chronic stimulation of the STN is gradually becoming accepted as a long-term therapeutic option for patients with advanced PD.[1,6,7,19] Recent approval of this procedure by the US Food and Drug Administration resulted in a significant increase in interest in this procedure among physicians and patients alike. Although quite safe and frequently very successful, this procedure remains challenging for neurosurgeons, mainly because of the small size of the target deep inside the human brain, where it is surrounded by various vital structures.[10] Different approaches are used to increase accuracy of STN targeting.[2,6] Anatomic targeting employing various imaging modalities, such as ventriculography, CT and MR imaging, and intraoperative electrophysiologic testing are combined with information from time-tested autopsy-based atlases. These atlases provide the coordinates of the STN and other structures relative to the established anatomic landmarks, primarily the commissures and ventricles.[13]

In case of thalamic localization, where borders of nuclei are variable and essentially indeterminable with current anatomic imaging, this atlas-based approach remains the gold standard.[12] In the case of STN localization, this barrier may be overcome by direct visualization of this small but clearly defined anatomic structure.[15,17] The combination of 1.5T MR imaging with intraoperative MER mapping of STN borders has proven to be the most reliable technique for the best DBS targeting of STN.[20] In the same study, however, the authors found discrepancies of >2 mm in anteroposterior axis of STN

between the position of STN seen on the 1.5T MR imaging and that defined during the MER, which was related mostly to relatively low resolution of STN on imaging.[20] In fact, it was estimated in another study that, in approximately 10% of cases, the definition of the STN cannot be fully appreciated with 1.5T MR imaging.[11] Moreover, according to a recent postmortem anatomic study performed by den Dunnen and Staal, the STN tends to change its borders, size, and shape significantly with age, whereas the distance between the anterior and posterior commissures, used as the main references for all atlas-based stereotactic procedures for STN targeting, is almost constant during life.[21] These findings once again confirm variability of STN in relation to the commissures and support the need in direct STN visualization as opposed to the atlas-based coordinates.

With commercial availability of clinical 3T scanners.[22] the improved contrast resolution from magnetic susceptibility effects at high magnetic field from iron storage in the structures of basal ganglia, substantia nigra, and red nucleus, and STN can be used to better visualize the target (Fig 2), which may reduce the need for detailed intraoperative MER mapping. In addition, the improved signal intensity-to-noise performance at the higher magnetic field provides for higher spatial resolution in a shorter acquisition time than is available at 1.5T or lower.

One of the approaches that has been described specifically to increase accuracy of the procedure is to insert 5 microelectrodes parallel to each other covering a 4-mm-diameter circle.[8] Although this technique does not seem to increase the risk of hemorrhagic complications significantly, a lower number of passes through the diseased brain may be potentially beneficial in terms of the patient's outcome.[23] The significant time saved in searching for the STN during surgery, especially if it is done bilaterally in single setting,[5] can avoid morbidity associated with extended procedures. The long surgical time and multiple passes of microelectrodes through the thalamus and other deep brain structures, as well as ventriculography, may be reasons for postoperative delirium and other behavioral changes in patients undergoing stereotactic functional procedures for PD.[6,16,24-26]

On the basis of preoperative 3T MR imaging planning, we were able to achieve very high precision in targeting the STN bilaterally in all 13 patients from our series, which allowed us to avoid multiple passes of microelectrodes for electrophysiologic confirmation of correct target location, because intraoperative MER revealed the electrophysiologic characteristics of the STN neuronal activity (Fig 3) on the first pass of microelectrode in all 26 cases. In turn, this has shortened the overall time of the surgical intervention and somewhat reduced the risk of possible complications related to brain tissue trauma from passing the electrodes during electrophysiologic mapping of the STN.

Each patient was evaluated clinically and with 1.5T MR imaging for correct placement of the electrode during the immediate postoperative period while the electrodes remained externalized and then again after internalization of the system (Fig 4). The dynamics of Parkinsonian symptoms in each case were evaluated by an independent neurologist, and evident neurologic improvement has been documented in all patients, particularly related to incontrollable tremor and rigidity. The degree of clinical improvement with stimulation varied from patient to patient, however, and the small sample size made it impossible for us to find a statistically significant correlation between our approach and the detailed clinical outcome of DBS. In the future, a larger, longer, and perhaps randomized blinded study will be needed to explore whether introduction of high-power MR imaging planning for STN targeting in PD results in better clinical outcome.

Thus, in current study, we have shown that the STN is visualized by 3T MR imaging in patients as a discrete anatomic target (Fig 2) and its location may be confirmed with a single-pass intraoperative single-cell MER, the technique that is widely used to establish accurate STN localization before macroelectrode positioning.[1] STN localization by 3T MR imaging reduces the intraoperative time for electrode placement. In addition, use of 3T MR imaging as a single imaging technique eliminates the need for image fusion, additional CT imaging, and ventriculography.

Conclusion

High-field MR imaging is both practical and useful in surgical planning of stereotactic interventions on the human STN. Rapid MR imaging acquisition at high spatial and contrast resolution to directly visualize and locate the STN shortens the procedural time by significantly increasing target calculation precision, which requires only a single pass of the microelectrode. Frame-based 3T MR imaging appears to be an excellent tool for stereotactic neurosurgery, particularly when small anatomic entities, such as the STN, are being targeted.

Acknowledgments

We are grateful for the assistance of Donna Shobat and Michael Flannery in acquisition of all MR imaging studies.

References

1. Bejjani BP, Dormont D, Pidoux B, et al. **Bilateral subthalamic stimulation for Parkinson's disease by using three-dimensional stereotactic magnetic resonance imaging and electrophysiological guidance.** *J Neurosurg* 2000;92:615–25
2. Aziz TZ, Nandi D, Parkin S, et al. **Targeting the subthalamic nucleus.** *Stereotact Funct Neurosurg* 2001;77:87–90
3. Starr PA. **Placement of deep brain stimulators into the subthalamic nucleus or Globus pallidus internus: technical approach.** *Stereotact Funct Neurosurg* 2002; 79:118–45
4. Terao T, Okiyama R, Takahashi H, et al. **[Comparison and examination of stereotactic surgical complications in movement disorders].** *No Shinkei Geka* 2003;31:629–36
5. Liu X, Rowe J, Nandi D, et al. **Localisation of the subthalamic nucleus using Radionics Image Fusion and Stereoplan combined with field potential recording. A technical note.** *Stereotact Funct Neurosurg* 2001;76:63–73
6. Ostergaard K, Sunde N, Dupont E. **Effects of bilateral stimulation of the subthalamic nucleus in patients with severe Parkinson's disease and motor fluctuations.** *Mov Disord* 2002;17:693–700
7. Valldeoriola F, Pilleri M, Tolosa E, et al. **Bilateral subthalamic stimulation monotherapy in advanced Parkinson's disease: long-term follow-up of patients.** *Mov Disord* 2002;17:125–32
8. Benabid AL, Koudsie A, Benazzouz A, et al. **Imaging of subthalamic nucleus and ventralis intermedius of the thalamus.** *Mov Disord* 2002;17(suppl 3): S123–29
9. Krack P, Batir A, Van Blercom N, et al. **Five-year follow-up of bilateral stimulation of the subthalamic nucleus in advanced Parkinson's disease.** *N Engl J Med* 2003;349:1925–34
10. Sterio D, Zonenshayn M, Mogilner AY, et al. **Neurophysiological refinement of subthalamic nucleus targeting.** *Neurosurgery* 2002;50:58–67
11. Starr PA, Christine CW, Theodosopoulos PV, et al. **Implantation of deep brain stimulators into the subthalamic nucleus: technical approach and magnetic resonance imaging-verified lead locations.** *J Neurosurg* 2002;97:370–87

12. Morel A, Magnin M, Jeanmonod D. **Multiarchitectonic and stereotactic atlas of the human thalamus.** *J Comp Neurol* 1997;387:588–630; erratum in *J Comp Neurol* 1998;391:545
13. Zonenshayn M, Rezai AR, Mogilner AY, et al. **Comparison of anatomic and neurophysiological methods for subthalamic nucleus targeting.** *Neurosurgery* 2000;47:282–92
14. Starr PA, Vitek JL, DeLong M, et al. **Magnetic resonance imaging-based stereotactic localization of the globus pallidus and subthalamic nucleus.** *Neurosurgery* 1999;44:303–13
15. Zhu XL, Hamel W, Schrader B, et al. **Magnetic resonance imaging-based morphometry and landmark correlation of basal ganglia nuclei.** *Acta Neurochir (Wien)* 2002;144:959–69
16. Slavin KV, Thulborn K, Shobat D. **Direct visualization of the human STN with 3T MRI.** *Acta Neurochir (Wien)* 2002;144:1076
17. Slavin KV, Wess C, Thulborn K. **Direct visualization of subthalamic nucleus with stereotactic 3 Tesla magnetic resonance imaging.** *J Neurosurg* 2004;100:796
18. Slavin KV, Burchiel KJ. **MicroGuide microelectrode recording system.** *Neurosurgery* 2002;51:275–78
19. Krack P, Benazzouz A, Pollak P, et al. **Treatment of tremor in Parkinson's disease by subthalamic nucleus stimulation.** *Mov Disord* 1998;13:907–14
20. Hamani C, Richter EO, Andrade-Souza Y, et al. **Correspondence of microelectrode mapping with magnetic resonance imaging for subthalamic nucleus procedures.** *Surg Neurol* 2005;63:249–53
21. den Dunnen WFA, Staal MJ. **Anatomical alterations of the subthalamic nucleus in relation to age: a postmortem study**. *Mov Disord* 2005;20:893–98
22. Thulborn K. **Clinical rationale for very-high-field (3.0 Tesla) functional magnetic resonance imaging.** *Top Magn Reson Imaging* 1999;10:37–50
23. Terao T, Takahashi H, Yokochi F, et al. **Hemorrhagic complication of stereotactic surgery in patients with movement disorders.** *J Neurosurg* 2003;98:1241–46
24. Takeshita S, Kurisu K, Trop L, et al. **Effect of subthalamic stimulation on mood state in Parkinson's disease: evaluation of previous facts and problems.** *Neurosurg Rev* 2005;28:179–86
25. Morrison CE, Borod JC, Perrine K, et al. **Neuropsychological functioning following bilateral subthalamic nucleus stimulation in Parkinson's disease.** *Arch Clin Neuropsychol* 2004;19:165–81
26. Beric A, Kelly PJ, Rezai A, et al**. Complications of deep brain stimulation surgery.** *Stereotact Funct Neurosurg* 2001;77:73–78