

Are your MRI contrast agents cost-effective?

Learn more about generic Gadolinium-Based Contrast Agents.



FRESENIUS
KABI

caring for life

AJNR

Status Epilepticus: A Clinical Perspective

AJNR Am J Neuroradiol 2006, 27 (3) 722
<http://www.ajnr.org/content/27/3/722.1>

This information is current as
of April 19, 2024.

BOOK REVIEW

Status Epilepticus: A Clinical Perspective

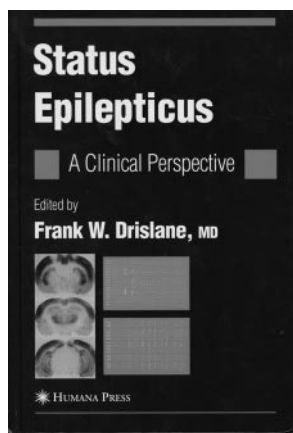
Edited by F.W. Drislane. New York: Humana Press; 2005, \$99.50.

Status epilepticus is an important clinical problem that is common and associated with significant morbidity and mortality. A growing body of literature focusing on both clinical and experimental issues attests to the significance of status epilepticus and its potential for brain injury. There is thus a need to synthesize more recent developments into a single volume. For these reasons, the inclusion of this book in a series of reviews on neurologic disorders within the *Current Clinical Neurology* series is welcome news.

Let me be clear from the start, however, in saying that the book is explicitly oriented toward treating neurologists, not radiologists. Although it covers a range of subjects across a wide clinical spectrum, including the diagnosis, epidemiology, clinical presentations, and treatment of status epilepticus, no chapters are dedicated to neuroimaging. Additional chapters are devoted to age-related differences in status epilepticus in children and neonates, and, though there is some coverage of basic mechanisms and the histopathology, these chapters appear to round out the clinical chapters and do not provide in-depth discussions.

These qualifications aside, the book does an admirable job of describing the clinical features of status epilepticus. The differential diagnosis of convulsive and nonconvulsive forms of status epilepticus are described clearly, and the reader is guided through the list of conditions that may imitate status epilepticus. Chapter 4, which covers the epidemiology of status epilepticus, is particularly well done. It comprehensively and logically examines the entire set of variables associated with status epilepticus and is data driven. The chapter on the electroencephalogram is all well thought out and provides clear description of electroencephalographic (EEG) abnormalities. Although the figures are clear, they are small and somewhat difficult to read. The figure legends provide appropriate description.

Other strengths of the book include a comprehensive reference list and the inclusion of a chapter on historical perspective to complement the current clinical literature. I found the historical annotations, which illustrate the integration of status epilepticus into the realm of general clinical medicine, particularly interesting. The liberal use of tables throughout the book greatly assists the reader in organizing the information contained in the text. The table of contents is logically subdivided into introductory topics, clinical presentations, basic mechanisms, and treatment. The references



supplied at the end of each chapter are comprehensive, and the final index is easy to use.

One of the book's major drawbacks is its redundancy. Epidemiologic data are repeated in the chapter on generalized tonic-clonic status, the classification of status epilepticus is reiterated in the chapter on nonconvulsive status epilepticus, and EEG classification is presented in both the EEG and classification chapters. The only neuroimaging figure, on page 152, depicts serial single-photon emission tomographic images in a patient with status epilepticus that reveal an area of hyperperfusion that subsequently resolves. The image quality is poor and will surely disappoint neuroradiologists accustomed to more enhanced resolution.

In summary, this volume is recommended primarily for clinicians, and it is doubtful that radiologists will find much to take away. Although it is well written, well referenced, and easy to use, its adherence to clinical data makes it more suitable for physicians who are treatment oriented.

BOOK REVIEW

Atlas of Sleep Medicine

Edited by Sudhansu Chokroverty, Robert J. Thomas, and Meeta Bhatt. Philadelphia: Elsevier Butterworth Heinemann; 2005, \$95.

The atlas is a substantial work of some 15 contributors that provides examples of clinical sleep recordings and also illustrates techniques used to evaluate sleep and sleep disorders. As the title implies, the work is essentially a collection of data displays from sleep recordings with accompanying explanatory text. In that sense, it is more like an organized album of interesting graphic findings along with descriptions and clinical correlations. As expected, the authors provide abundant examples of polysomnography and other sleep-recorded data. The material is reasonably laid out and logically organized. I found the listed price reasonable at \$95. Readers who have some familiarity with sleep-recording techniques and the format of related data displays are likely to find the material more understandable than those who are new at looking at such representations.

The accompanying text of the atlas for the most part is authoritative and well prepared. In a work of this kind, there is understandably some unevenness of style. Some page numbers are not shown, but the corresponding figures are numbered. The bibliography for some chapters is limited to a few entries, including some of the author's own articles, but other chapter bibliographies are more extensive. I found the index to be well prepared and useful. Unfortunately, the abbreviations table before the first chapter does not include abbreviations used elsewhere in the book. An example is the trade marked

