

# Gadolinium Enhancement of Cauda Equina: A New MR Imaging Finding in the Radiculitic Form of Tick-Borne Encephalitis

## CASE REPORT

S. Marjelund  
A. Jaaskelainen  
T. Tikkakoski  
S. Tuisku  
O. Vapalahti

**SUMMARY:** Tick-borne encephalitis virus is an important human pathogen in Europe. The infection usually presents as meningitis, meningoencephalitis, or meningoencephalomyelitis and only rarely as symptoms of isolated myeloradiculitis. We describe the lumbar MR imaging finding in a 48-year-old man with serologically confirmed tick-borne encephalitis in which there was enhancement of the ventral surface of the conus and the anterior nerve roots from the T12 level extending along the length of the ventral cauda.

Tick-borne encephalitis (TBE) is endemic in many parts of central, eastern, and northern Europe, with about 3000 cases reported annually. It is caused by a flavivirus—the tick-borne encephalitis virus, or TBEv—which is transmitted into humans by tick bites. The clinical spectrum of the infection ranges from subclinical infection to meningitis, meningoencephalitis, and meningoencephalomyelitis.<sup>1,2</sup> In about 5% of cases, the infection presents as myeloradiculitis without obvious symptoms of meningoencephalitis.<sup>3</sup> The diagnosis is made serologically.<sup>1,2</sup> The MR imaging finding of the brain may be normal, but the most frequently reported finding is increased signal intensity in the thalami and basal ganglia in T2-weighted and fluid-attenuated inversion recovery (FLAIR) images.<sup>1,4-7</sup> To the best of our knowledge, only 2 pathologic spinal MR imaging findings of TBE have been reported in the literature, both of them pertaining to the cervical spinal cord.<sup>7,8</sup> We describe the lumbar MR imaging of a 48-year-old man with lumbar radiculitis due to TBE.

## Case Report

A 48-year-old man was admitted into hospital in June 2004 with a fever ( $\leq 39.5^{\circ}\text{C}$ ) of a few days' duration, nausea, back pain, and muscle weakness in the legs. He had previously been healthy, with only simvastatin medication for hypercholesterolemia. The back pain had started from the left side but the following day had migrated to the right side. Clinical examination showed the patient to be alert and oriented. No nuchal rigidity was present. Severe motor weakness was detected, particularly in his right lower extremity, and sensory loss was present in the same thigh and calf laterally. The right patellar tendon reflex was absent. Muscle strength in the upper limbs was normal, and only slight clumsiness in the hands was detected. Urine retention and cauda equina syndrome developed, and catheterization was needed. Lumbar CT was normal. Leukocyte count was  $10.0 \times 10^9/\text{L}$ , and C-reactive protein was 3 mg/L. CSF contained leukocytes ( $145 \times 10^6/\text{L}$ ), with a granulocyte count of 44%, a protein value of 677 mg/L, and a glucose concentration of 3.6 mmol/L. Electrophysiologic studies were consistent with lower motor neuron damage in the right leg. The patient had received several tick bites while staying at his summer cottage on Kupu Island in the Kokkola Archipelago, western

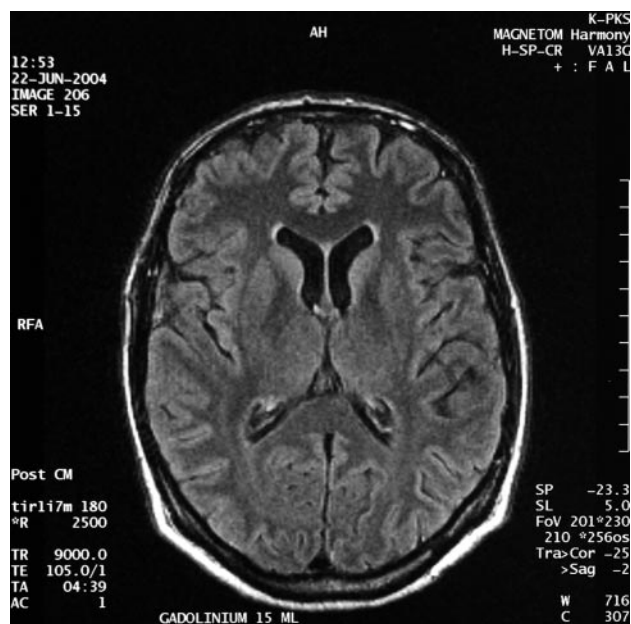
Received May 22, 2005; accepted after revision June 22.

From the Department of Radiology (S.M.), Oulu University Central Hospital, Oulu, Finland; the Haartman Institute (A.J., O.V.), Helsinki University, Helsinki, Finland; and the Departments of Radiology (T.T.) and Neurology (S.T.), Keski-Pohjanmaa Central Hospital, Kokkola, Finland.

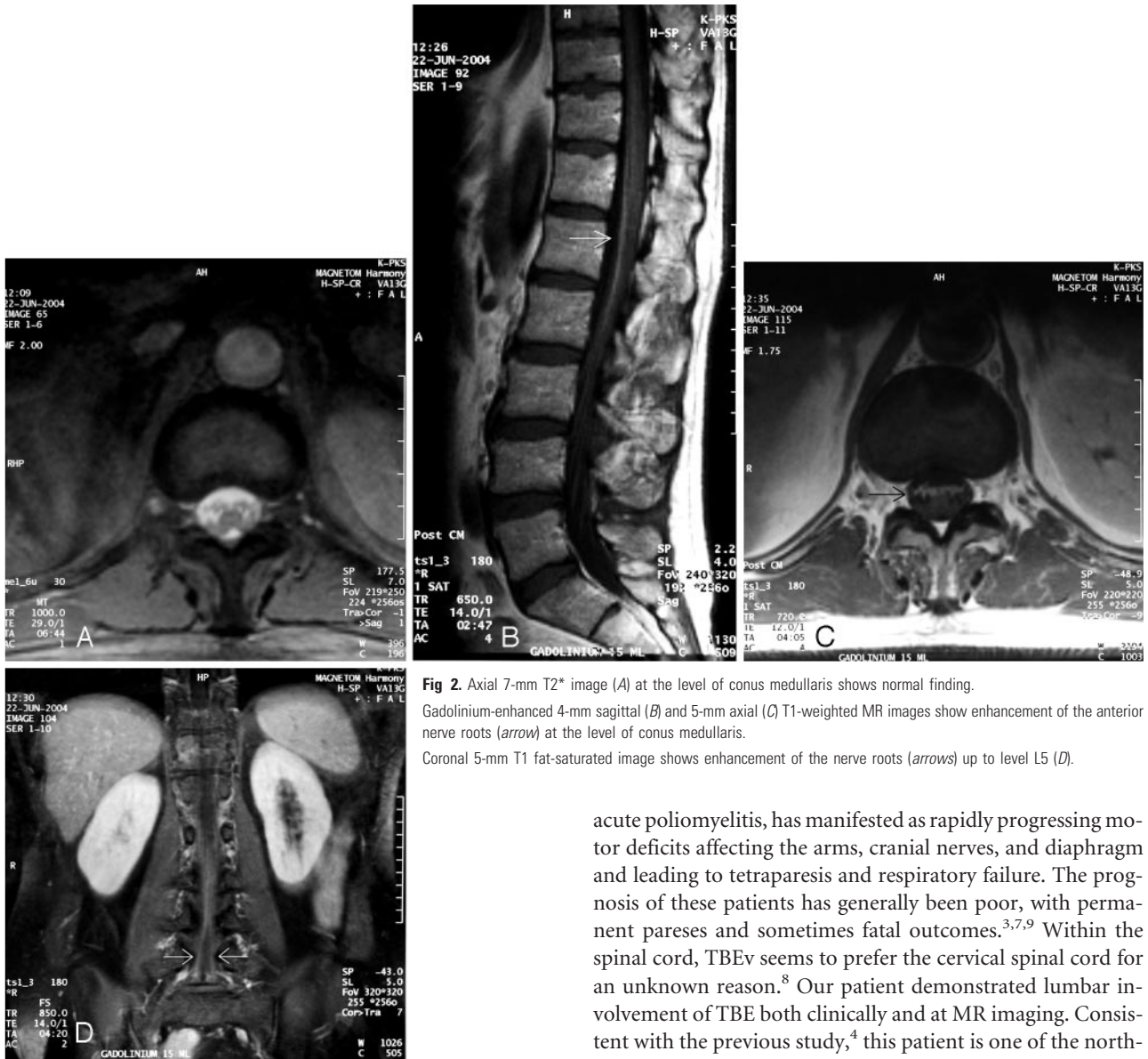Address correspondence to Sari Marjelund, MD, Department of Radiology, Oulu University Central Hospital, PL 50, FIN-90029 OYS, Oulu, Finland.

Finland. No erythema migrans had been detected. Because of suspected Lyme borreliosis, intravenous administration of ceftriaxone ( $4 \text{ g} \times 1$ ) and dexamethasone ( $5 \text{ mg} \times 4$ ) was initiated. The initial gadolinium-enhanced MR imaging of the brain and the spinal cord was performed at 1.5T the day after admission, but no pathologic findings were seen. Blood and CSF cultures and serological tests for herpes simplex, varicella zoster, mycoplasma, listeria, and toxoplasma were negative. Antibodies to *Borrelia burgdorferi* also remained repeatedly negative both in the acute phase and at the 2-month follow-up. Instead, a 4-fold titer rise in the antibodies to TBEv (strain Kumlunge) was detected in the hemagglutination inhibition test, and TBEv-IgM antibodies by using the  $\mu$ -capture IgM technique were positive in both serum and CSF consistent with a recent TBE infection.

MR imaging of the brain and the thoracolumbar spine was repeated 2 weeks after admission (1T). The brain MR was normal (Fig 1). On spinal MR images, enhancement of the ventral surface of the conus and the anterior nerve roots was detected, beginning at the level of T12 and extending throughout the length of the ventral cauda equina (Fig 2). At the same time, as part of a large tick-collecting



**Fig 1.** Gadolinium-enhanced axial 5-mm turbo FLAIR image shows normal basal ganglia and thalami.



**Fig 2.** Axial 7-mm T2\* image (A) at the level of conus medullaris shows normal finding. Gadolinium-enhanced 4-mm sagittal (B) and 5-mm axial (C) T1-weighted MR images show enhancement of the anterior nerve roots (arrow) at the level of conus medullaris. Coronal 5-mm T1 fat-saturated image shows enhancement of the nerve roots (arrows) up to level L5 (D).

research project, 184 ticks were collected from Kupu Island, and 3 of them were positive for TBEv (A. Jaaskelainen et al, unpublished data, 2005).

The patient was discharged after 3 weeks of hospitalization with moderate muscle weakness remaining in his right leg. Eleven months after the onset of symptoms, the motor disturbance is slightly improved, but muscle atrophies are still visible and he has constant pain in the right hip.

## Discussion

TBE infection is characterized by a biphasic course of the disease in 74% of patients, with nonspecific, influenza-like symptoms in the first phase followed by neurologic infection in 20%–30% of infected patients. In this group of patients, the infection presents as meningitis or meningoencephalitis in 90%. The most frequent neurologic symptoms are impaired consciousness, ataxia, and paresis of the extremities and cranial nerves.<sup>1</sup> Myeloradiculitis is usually associated with meningoencephalitis, but it may rarely present as the sole form of the infection. The myeloradiculitic form of TBE, mimicking

acute poliomyelitis, has manifested as rapidly progressing motor deficits affecting the arms, cranial nerves, and diaphragm and leading to tetraparesis and respiratory failure. The prognosis of these patients has generally been poor, with permanent pareses and sometimes fatal outcomes.<sup>3,7,9</sup> Within the spinal cord, TBEv seems to prefer the cervical spinal cord for an unknown reason.<sup>8</sup> Our patient demonstrated lumbar involvement of TBE both clinically and at MR imaging. Consistent with the previous study,<sup>4</sup> this patient is one of the northern-most TBE cases reported in Europe.

Whenever meningoencephalitic symptoms are lacking, as in our patient, the diagnosis of TBE is challenging.<sup>3,9</sup> Demonstration of intrathecal synthesis of IgM and IgG antibodies is the most specific serologic method for a recent TBE infection, and the presence of IgM activity in serum is also sufficient for diagnosis.<sup>1</sup> Our patient had IgM and IgG antibodies to TBE in both serum and CSF, which confirmed the diagnosis.<sup>10</sup>

Brain MR imaging may show increased signal intensity on T2-weighted and FLAIR images in the thalami and basal ganglia, cerebellum, hypothalamus, peduncles, and pons.<sup>4-7</sup> T1-weighted pre- and postcontrast images have usually been normal,<sup>4,6-7</sup> but enhancement of a thalamic lesion was described in one patient<sup>5</sup> and slight leptomeningeal enhancement around the peduncles in another case.<sup>4</sup> Beer et al reported an isolated hyperintense lesion in the anterior part of the cervical cord,<sup>8</sup> and Bender et al described a similar cervical finding accompanied by bithalamic and brain stem signal intensity pathology.<sup>7</sup> According to histologic studies, TBEv affects predominantly the meninges and the gray matter of the CNS. The

basal ganglia, thalami, medulla oblongata, pons, cerebellum, brain stem, and anterior horn cells in the spinal cord are particularly affected.<sup>1</sup> The MR imaging findings previously reported and the present finding support histologic studies.

Contrast enhancement of cauda equina and nerve roots in MR images is a nonspecific finding and suggests breakdown of the blood-nerve barrier.<sup>11</sup> The differential diagnosis of this finding includes Guillain-Barré syndrome, chronic inflammatory demyelinating polyneuropathy, sarcoidosis, lymphoma, meningeal carcinomatosis, AIDS-related cytomegalovirus polyradiculopathy, neuroborreliosis, arachnoiditis, transverse myelitis, spinal cord infarcts, and lumbosacral compression due to disk herniation or stenosis.<sup>11-13</sup> This report demonstrates enhancement of the cauda equina and the anterior nerve roots of the conus in TBE, a finding that may be underdiagnosed because spinal MR imaging is not routinely performed for all suspected TBE patients at the initial phase or on follow-up.

Because  $\leq 46\%$  of TBE patients have permanent neurologic sequelae, mainly cognitive and neuropsychiatric disorders but also paralysis,<sup>2</sup> it is important to recognize this infection. Thus, TBE should be included in the differential diagnosis of enhancement of cauda equina in MR imaging in patients with radiculitic symptoms.

## References

1. Kaiser R. **The clinical and epidemiological profile of tick-borne encephalitis in southern Germany 1994–98: a prospective study of 656 patients.** *Brain* 1999; 122:2067–78
2. Haglund M, Günther G. **Tick-borne encephalitis-pathogenesis, clinical course and long-term follow-up.** *Vaccine* 2003;21:S1/11–S1/18
3. Kollmeier M, Hagemann G, Kunze A, et al. **Problems of differential diagnosis in tick-borne encephalitis-induced polyradiculitis.** *Nervenarzt* 2002;73: 1191–94
4. Marjelund S, Tikkakoski T, Tuisku S, et al. **Magnetic resonance imaging findings and outcome in severe tick-borne encephalitis: report of four cases and review of the literature.** *Acta Radiol* 2004;45:88–94
5. Waldvogel K, Bossart W, Huisman T, et al. **Severe tick-borne encephalitis following passive immunization.** *Eur J Pediatr* 1996;155:775–79
6. Alkadhi H, Kollias SS. **MRI in tick-borne encephalitis.** *Neuroradiology* 2000;42: 753–55
7. Bender A, Schulte-Altendorneburg G, Walther EU, et al. **Severe tick-borne encephalitis with simultaneous brain stem, bithalamic, and spinal cord involvement documented by MRI.** *J Neurol Neurosurg Psychiatry* 2005;76:135–37
8. Beer S, Brune N, Kesselring J. **Detection of anterior horn lesions by MRI in central European tick-borne encephalomyelitis.** *J Neurol* 1999;246:1169–71
9. Schellinger PD, Schmutzhard E, Fiebach JB, et al. **Poliomyelitic-like illness in central European encephalitis.** *Neurology* 2000;55:299–302
10. Jaaskelainen A, Han X, Niedrig M, et al. **Diagnosis of tick-borne encephalitis by a mu-capture immunoglobulin M-enzyme immunoassay based on secreted recombinant antigen produced in insect cells.** *J Clin Microbiol* 2003;41: 4336–42
11. Coşkun A, Kumandaş S, Paç A, et al. **Childhood Guillain-Barré syndrome: MR imaging in diagnosis and follow-up.** *Acta Radiol* 2003;44:230–35
12. Midroni G, de Tilly LN, Gray B, et al. **MRI of the cauda equina in CIPD: clinical correlations.** *J Neurol Sci* 1999;170:36–44
13. Amano Y, Machida T, Kumazaki T. **Spinal cord infarcts with contrast enhancement of the cauda equina: two cases.** *Neuroradiology* 1998;40:669–72