

Are your **MRI contrast agents** cost-effective?

Learn more about generic **Gadolinium-Based Contrast Agents**.



**FRESENIUS  
KABI**

caring for life

**AJNR**

**A Case Meeting Clinical Brain Death Criteria  
with Residual Cerebral Perfusion**

Thomas A. Ala, Matthew J. Kuhn and Anton J. Johnson

*AJNR Am J Neuroradiol* 2006, 27 (9) 1805-1806

<http://www.ajnr.org/content/27/9/1805>

This information is current as  
of April 19, 2024.

## Reply:

I would like to thank Dr. Stasolla for his kind words in reference to my article, "The Many Faces of Facial Nerve Schwannoma."<sup>1</sup> Although the "dural tail" sign has been reported with many pathologies, including acoustic schwannomas, none of the cases in my series demonstrated a dural tail on imaging. It is always difficult to interpret cases solely on the basis of a text description, but the case Dr. Stasolla describes in his letter is consistent with a facial nerve schwannoma. Both the clinical and imaging descriptions are consistent with the findings in my series, with a peripheral facial neuropathy in 10 cases (42%) and some type of hearing loss in 11 cases (46%), and for the radiologic description (benign osseous remodeling on CT and enhancing lesion along the course of the facial nerve on MR imaging).

I agree with Dr. Stasolla that there are a variety of etiologies that can lead to a dural tail sign in MR imaging, and I would be happy to review his case because I am always interested in seeing good head and neck cases.

## Reference

1. Wiggins RH 3rd, Harnsberger HR, Salzman RL, et al. **The many faces of facial nerve schwannoma.** *AJNR Am J Neuroradiol* 2006;27:694–49

Richard H. Wiggins, III  
University of Utah  
Salt Lake City, Utah

## A Case Meeting Clinical Brain Death Criteria with Residual Cerebral Perfusion

Cerebral blood flow (CBF) studies are often used to support the diagnosis of brain death, particularly when certain conditions such as severe facial trauma, drug toxicity, or other factors prevent reliable evaluation of the clinical examination. The absence of cerebral perfusion is consistent with brain death. Exceptional cases have been reported, however, in which CBF studies have documented residual perfusion despite the patients' meeting clinical criteria for brain death.<sup>1</sup> We would like to present to your readers another rare example of this dissociation between cerebral perfusion and neurologic function in which a patient's clinical examination was consistent with brain death, yet a CBF study performed shortly afterward demonstrated prominent hemispheric perfusion.

A 49-year-old man presented to our institution following cardiac arrest after a seizure. He was resuscitated in the field, with the total duration of asystole estimated to be 5 minutes. Results of urine toxicology and alcohol screens were negative. His CSF analysis was nondiagnostic. Electroencephalograms on day 1 and 3 showed low amplitude delta slowing without focality, paroxysmal activity, or interval change. A head MR imaging study on day 2

showed bilateral basal ganglionic and medial temporal lobe lesions consistent with a hypoxic-ischemic injury. He never awakened; and after an initial recovery of brain stem reflexes and respiratory effort, during the following days, he progressively lost neurologic function.

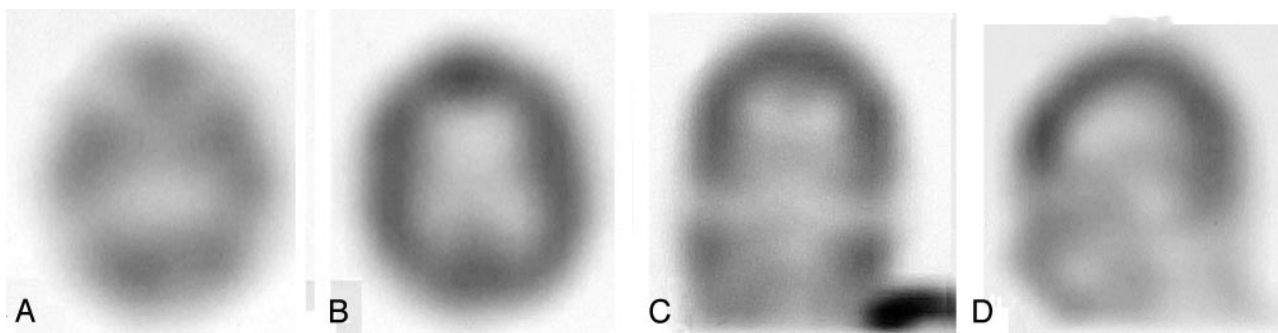
On day 5, a brain death examination was performed. His pupils were nonreactive at 4-mm diameter, and there were no corneal, cough, or gag reflexes and no ocular reflexes to either head movement or to 50 mL of ice water in each ear. He had no respiratory effort during an apnea test with a PaCO<sub>2</sub> of 72 mm Hg. No movements were elicited by nail-bed pressure, sternal rubbing, or supraorbital pressure. The examination was recorded as being consistent with clinical brain death.

Five hours later, a nurse reported that sternal rubbing would elicit movements of the arms, legs, head, and back. Upon the request of the organ donation personnel, a cerebral perfusion scintigraphy single-photon emission CT (SPECT) scan was ordered to confirm brain death, consistent with the policies of our institution. The CBF study unexpectedly demonstrated prominent hemispheric perfusion, and organ donation plans were suspended. See Fig 1 for representative images.

On day 6, his examination continued to show no brain stem function. During 1 of several sternal rubs, the patient's head turned to the left and his left arm rose slightly off the bed, flexed at the elbow approximately 15°, and tremored for several seconds. No other movements were observed. No further CBF, EEG, or head imaging studies were performed upon the request of the patient's family. Later that day the patient's heart was noted to be in asystole. Permission for autopsy was not obtained.

With the exception of the CBF study, the patient's examination on day 5 was consistent with many accepted criteria for the clinical diagnosis of brain death—for example, those defined by the American Academy of Neurology.<sup>2</sup> Coma, absence of brain stem reflexes, and apnea were documented, and the required prerequisites were satisfied, including neuroimaging evidence of an acute central nervous system catastrophe, the exclusion of complicating medical conditions, and a core temperature  $\geq 32^{\circ}\text{C}$ .

The most likely explanation for the dissociation between neurologic function and CBF in this case is that the CBF study was obtained relatively early in the course of brain death, before the intracranial pressure from cerebral edema overcame arterial pressure. A later CBF study would very likely have demonstrated the absence of perfusion. This phenomenon has been described by others,<sup>3</sup> and some have even suggested that CBF studies performed



**Fig 1.** Representative axial (A and B), coronal (C), and sagittal (D) images from the SPECT study obtained 15 minutes after the intravenous injection of 24.5 millicuries of technetium Tc99m ethyl cysteinate dimer. Images demonstrate prominent residual hemispheric perfusion.