

Are your **MRI contrast agents** cost-effective?

Learn more about generic **Gadolinium-Based Contrast Agents**.



**FRESENIUS
KABI**

caring for life

AJNR

Preoperative Embolization of a Cervicodorsal Paraganglioma by Direct Percutaneous Injection of Onyx and Endovascular Delivery of Particles

R.S. Quadros, S. Gallas, C. Delcourt, E. Dehoux, B. Scherperel and L. Pierot

This information is current as of April 18, 2024.

AJNR Am J Neuroradiol 2006, 27 (9) 1907-1909
<http://www.ajnr.org/content/27/9/1907>

CASE REPORT

R.S. Quadros
S. Gallas
C. Delcourt
E. Dehoux
B. Scherperel
L. Pierot

Preoperative Embolization of a Cervicodorsal Paraganglioma by Direct Percutaneous Injection of Onyx and Endovascular Delivery of Particles

SUMMARY: We report the feasibility and efficacy of percutaneous injection of Onyx (Micro Therapeutics, Irvine, Calif.), a nonadhesive liquid embolic agent, into an unusually located paraganglioma, followed by endovascular embolization with particles before surgery.

Paragangliomas or glomus tumors are uncommon neoplasms of the head and neck. They are highly vascular, and surgical resection may be complicated by dramatic blood loss. The endovascular embolization technique was made possible by the same advances in imaging and catheter design as those that allowed the routine endovascular treatment of aneurysms and vascular malformations of the brain. However, the possibilities of this technique for treating paragangliomas are limited because of the presence of very small feeding branches from the internal carotid or vertebral arteries that cannot be directly catheterized. Direct intratumoral embolization is, therefore, a potential option for treating hypervascularized lesions of the head and neck. We report a case of cervicodorsal paraganglioma treated by percutaneous embolization with ethylene vinyl alcohol copolymer (Onyx; Micro Therapeutics, Irvine, Calif) and intravascular embolization with particles, followed by surgical resection.

Case Report

A 52-year-old woman was hospitalized for a voluminous posterior epidural tumor, with severe back pain and insidious pyramidal syndrome. CT showed a well-defined cervicodorsal right lateralized mass, isoattenuated to muscle, located posterior to the spine with invasion of the posterior arch. It exhibited intense contrast enhancement on dynamic scans. MR imaging confirmed the location of this hypervascularized tumor in soft tissue, with intermediate signal intensity on a T1-weighted image (Fig 1) and moderately high signal intensity on a T2-weighted image (Fig 2). Intense homogeneous enhancement occurred after intravenous administration of gadolinium. Preoperatively, a detailed spinal angiography was performed, with examination of the branches of the subclavian arteries, including the vertebral, ascending, and deep cervical arteries, and of the carotid arteries. This examination revealed a hypervascular mass with enlarged feeding vessels and attenuated homogeneous staining. This mass was fed by the ascending cervical, deep cervical, and vertebral arteries (Figs 3 and 4). Biopsy suggested a diagnosis of paraganglioma with an unusual location.

A multidisciplinary team consisting of orthopedists, neurosur-

geons, and neuroradiologists decided to treat this tumor by embolization followed by surgery. Embolization was scheduled in 2 sessions: direct intralesional injection of Onyx in the first session and transarterial delivery of particles in the second session. Because of the prone position of the patient for the percutaneous treatment and the mass effect of the tumor on the spinal cord, it was judged more appropriate to perform embolization in 2 sessions. In the first session, 20-gauge needles were inserted into the tumor via a posterior access route. Before each injection of Onyx, an injection of contrast media was performed to determine the right position for the needle and parenchymography of the tumor was performed. We also verified arterial reflux, venous drainage, the absence of extravasation, and the vascular compartment of the tumor to be filled. Several punctures were done. In all, 8 mL of Onyx was injected into the tumor. No reflux was observed. Polymerization of Onyx was good. The procedure was stopped when the risk of arterial reflux to the spinal arteries was considered high. Bleeding from the puncture sites was easily controlled by manual compression and bandages; no profuse bleeding at the puncture sites was observed.

Secondary, transarterial delivery of polyvinyl alcohol (PVA) particles was achieved. A 5F guiding catheter was placed in the left and right cervical arteries, and a microcatheter was used to perform a distal embolization. PVA particles of 500–700 μm were used to complete tumor devascularization. A final postembolization angiogram revealed only a small amount of residual neovascularity (Fig 5). Surgical conditions were good. The Onyx cast delineated precisely the boundaries of the tumor, thus facilitating its removal (Fig 6). The patient slowly recovered, and definitive histologic study confirmed the diagnosis of cervical paraganglioma.

Discussion

The value of preoperative embolization of hypervascularized tumors has been well established in the literature.^{1–5} Two techniques can be used for this purpose: superselective catheterization of the supplying branches and transarterial embolization with particulate agents or a permanent liquid polymerizing agent, and direct intratumoral injection of a permanent liquid polymerizing agent, a technique initially described in 1990 by Deramond et al.⁶ In 1994, Pierot et al⁵ and Casasco et al⁷ were the first to use direct puncture of hypervascular head and neck tumors with impressive results. By transarterial embolization, complete devascularization of the tumor bed is often not achieved because of the complex angioarchitecture, characterized by multiple small

Received October 4, 2005; accepted after revision October 27.

From the Radiology Department (R.S.Q., S.G., C.D., L.P.), the Orthopaedic Department (E.D.), and the Neurosurgical Department (B.S.), Hôpital Maison Blanche, Reims, France.

Please address correspondence to: Laurent Pierot, MD, Service de Radiologie, Hôpital Maison-Blanche, 45 rue Cognacq-Jay, 51092 Reims Cedex, France; e-mail: lpierot@chu-reims.fr

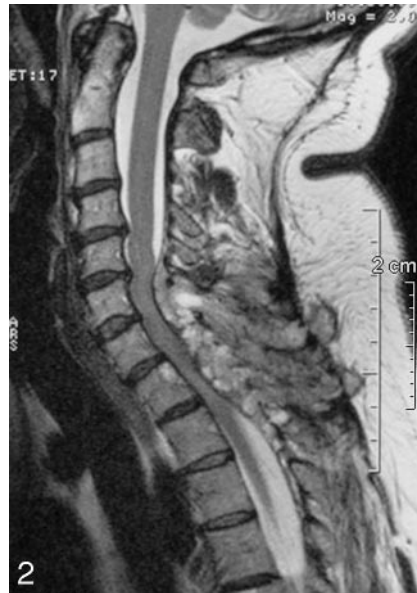
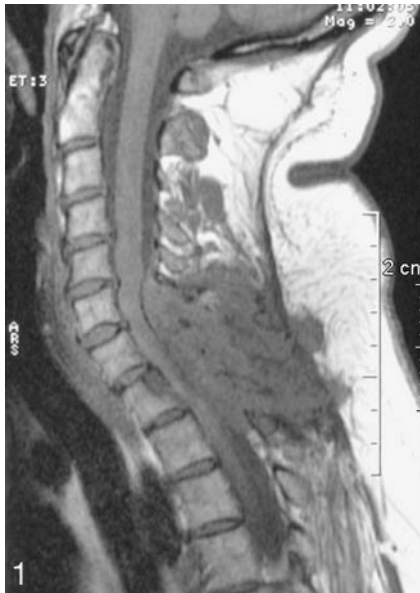
Fig 1. T1-weighted sagittal MR image shows a well-defined heterogeneous mass in the posterior cervical area between C6 and T2, with low signal intensity.

Fig 2. T2-weighted sagittal MR image shows a heterogeneous high-intensity mass.

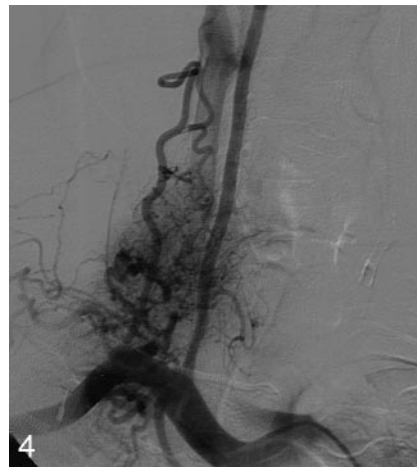
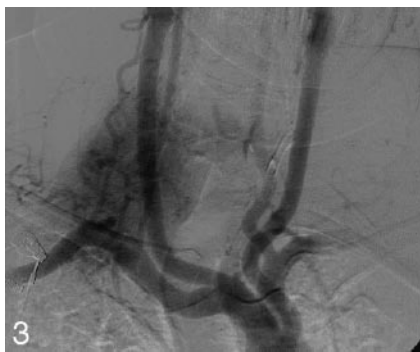


Fig 3. Aortic arch injection reveals a hypervascular mass with enlarged feeding vessels and attenuated homogeneous staining. The mass was mostly fed by branches of the right subclavian artery, especially cervical branches, and muscular branches of the right vertebral artery.

Fig 4. Selective right subclavian angiogram shows the relationship between the tumor and the right vertebral artery.

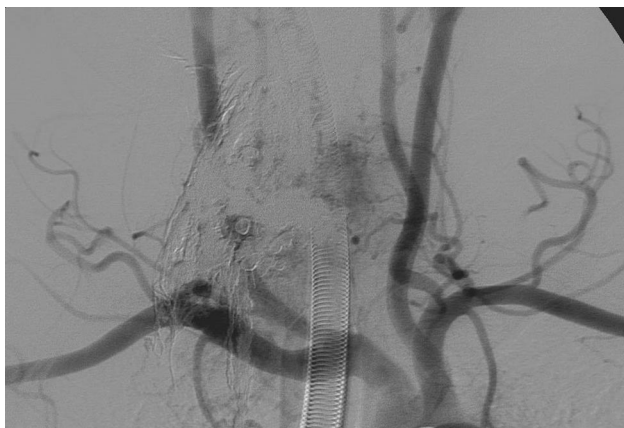

Fig 5. Aortic arch injection—final control showing a small residual blush.

feeding branches, involvement of branches arising from the internal carotid and vertebral arteries, and possible vasospasm.⁸ One of the main advantages of intratumoral injection is easier access to the vascular tumor bed, which is not limited by arterial tortuosities, atherosclerotic disease, or induced vasospasm. However, this does not fully overcome

the complex vascular anatomy and multiplicity of the feeders.

Casasco et al⁷ reported 2 severe complications during intratumoral injection of cyanoacrylate and, therefore, suggested protecting the intracranial branches during the injection with nondetachable balloons, injection of a small amount of intratumoral contrast medium just before the glue injection, and careful image analysis for the detection of dangerous anastomoses.⁹ They also suggested the use of a high concentration of cyanoacrylate (50%), a suggestion not supported by Abud et al,⁸ who believe that a low concentration of cyanoacrylate (20%) would allow homogeneous intratumoral penetration of the embolic agent.^{9,10} Under continuous fluoroscopic control, the use of a low cyanoacrylate concentration seems to be safe.

Embolic agents are classified into 3 categories: mechanical devices, particles, and liquids. The choice of the optimal embolic agent depends on the hemodynamic and angioarchitectural factors. For the present patient, we chose first to inject the liquid agent Onyx by direct tumoral puncture and, subsequently, transarterial particle delivery. This treatment strategy was chosen because direct injection of Onyx allowed gradual slowing down of the blood flow through the tumor and the

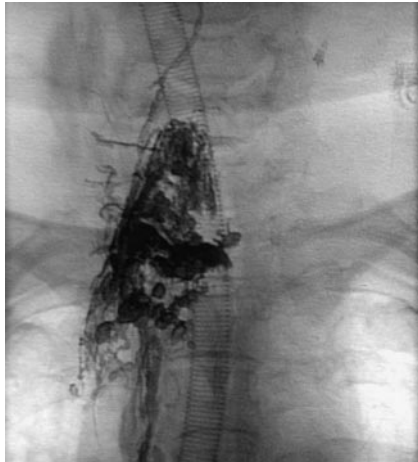

Fig 6. Final Onyx cast.

blocking of numerous small feeding arteries. Because of its epidural component, embolization of the whole tumor by direct puncture was considered too dangerous on account of the mass effect of the tumor on the spinal cord and the risk of a reflux of Onyx into the spinal arteries.

Why do we prefer Onyx instead of the cyanoacrylate used by others? There are no studies in which the use of these 2 agents is compared for the treatment of hypervascular lesions by direct puncture. However, the studies by Casasco et al⁷ showed that cyanoacrylate is not perfect in this respect. In addition, Gobin et al,¹¹ who used Onyx to treat 18 patients with hypervascular lesions (3 of them by direct puncture), evaluated the efficacy of this new agent and its general advantages over cyanoacrylate. Onyx can be injected as slowly as necessary for precise delivery; it can even be stopped to check the degree of embolization and be restarted later. Unlike cyanoacrylate, Onyx advances in a single column, thus reducing the risk of involuntary venous migration.

Spinal paragangliomas are rare, and most are located intradurally and extramedullary in the lumbar spine at the level of the filum terminale. Only a few cases of cervical and thoracic spine paragangliomas have been reported in the literature.^{12,13} Thus, paraganglionic tissue is not, as in the present case, usually found in the cervicodorsal region, and various hypotheses about the origin of spinal paragangliomas have been proposed. Some of them suggest that these tumors may originate from sympathetic neurons in the lumbar and thoracic lateral horns of the spinal cord and may send their axons to the sym-

pathetic trunk through the communicating branches. It is also possible that heterotopic neurons lie along these branches, proximal to the sympathetic trunk and that at this site these neurons may be the original locus of tumor formation.

Conclusion

We report, as far as we know, the first case of preoperative spinal paraganglioma embolization by direct injection of Onyx, followed by transarterial delivery of particles. These procedures allowed a subtotal devascularization of the tumor without worsening symptoms. Surgery was then performed under good conditions. In this instance, the preoperative embolization by direct puncture of hypervascular tumors was safe and effective. However, more studies must be conducted to prove that Onyx is a better embolic agent than cyanoacrylate. Our experience encourages us to continue the use of Onyx to manage these challenging tumors.

References

1. Van den berg R, Rodesch G, Lasjaunias P. **Management of paragangliomas: clinical and angiographic aspects.** *Intervent Neuroradiol* 2002;8:127–34
2. Valavanis A. **Preoperative embolization of the head and neck: indications, patient selection, goals, and precautions.** *AJNR Am J Neuroradiol* 1986;7:943–52
3. Chaloupka JC, Mangla S, Huddle DC, et al. **Evolving experience with direct puncture therapeutic embolization for adjunctive and palliative management of head and neck hypervascular neoplasms.** *Laryngoscope* 1999;109:1864–72
4. Persky MS, Setton A, Niimi Y, et al. **Combined endovascular and surgical treatment of head and neck paragangliomas: a team approach.** *Head Neck* 2002;25:423–31
5. Pierot L, Boulin A, Castaings L, et al. **Embolization by direct puncture of hypervascularized ORL tumors** [in French]. *Ann Otolaryngol Chir Cervicofac* 1994;111:403–09
6. Deramond H, Debuische C, Pruvo JP. **La vertebroplastie.** *Feuillet de Radiologie* 1990;30:262–68
7. Casasco A, Herbreteau D, Houdart E, et al. **Devascularization of craniofacial tumors by percutaneous tumor puncture.** *AJNR Am J Neuroradiol* 1994;15:1233–39
8. Abud DG, Mounayer C, Benndorf G, et al. **Intratumoral injection of cyanoacrylate glue in head and neck paragangliomas.** *AJNR Am J Neuroradiol* 2004;25:1457–62
9. Casasco A, Houdart E, Biondi A, et al. **Major complications of percutaneous embolization of skull-base tumors.** *AJNR Am J Neuroradiol* 1999;20:179–81
10. Derdeyn CP, Neely JG. **Direct puncture embolization for paragangliomas: promising results but preliminary data.** *AJNR Am J Neuroradiol* 2004;25:1453–54
11. Gobin YP, Murayama Y, Milanese K, et al. **Head and neck hypervascular lesions: embolization with ethylene vinyl alcohol copolymer—laboratory evaluation in swine and clinical evaluation in humans.** *Radiology* 2001;221:309–17
12. Sundgren P, Annertz M, Englund E, et al. **Paragangliomas of the spinal canal.** *Neuroradiology* 1999;41:788–94
13. Böker DK, Wasserman H, Solymosi L. **Paragangliomas of the spinal canal.** *Surg Neurol* 1983;19:461–68