

Are your **MRI contrast agents** cost-effective?

Learn more about generic **Gadolinium-Based Contrast Agents**.



**FRESENIUS
KABI**

caring for life

AJNR

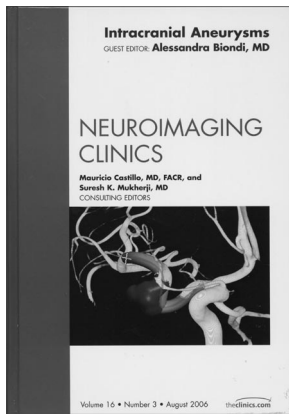
Stroke Treatment and Prevention: An Evidence-Based Approach

AJNR Am J Neuroradiol 2007, 28 (7) 1419-1420

doi: <https://doi.org/10.3174/ajnr.A0579>

<http://www.ajnr.org/content/28/7/1419>

This information is current as
of April 24, 2024.



is shown where a Hunt and Hess Grade II and a Fischer Grade III subarachnoid hemorrhage is mentioned, but nowhere in that chapter are these grading systems described. In fact, if one then goes to the index in hopes of finding where this is discussed in other chapters, one comes up with nothing under those terms. Despite these editorial guffaws, there is good information here, and the imaging is of high quality.

Chapters on unruptured and ruptured intracranial aneurysms give the reader an understanding of aneurysm size and the subsequent chances of rupture/rupture, along with treatment considerations. Both chapters are well written, and this reviewer likes the Socratic manner in which a portion of the material is presented: questions of importance asked and then answered.

The chapter on current diagnostic modalities should be of most interest to the reader. The images are good, and modern techniques (CT angiography, MR angiography, 3D angiography, and various display methods) are described; however, more specifics on CT angiography, for example, could have been included. There is no mention of delays in initiating imaging postinjection, nor is there a discussion of the value of the newer 64–128 multidetector CT scanners. To the author's credit, they describe risks of angiography, importantly including radiation risks. Again, however, the manuscript editing is not up to what one would expect. The term "sensibility" is used time and again, and to this reviewer that is not a recognized statistical term. The probable intent was to use sensitivity, and one wonders why this was not changed. One is left with baffling statements such as, "All teams insisted on the inferior sensibility concerning diagnosis of aneurysms not responsible for the hemorrhage," or "CT angiography, next to considerable improvement in spatial and temporal resolution, has become a high performance diagnostic tool."

A relatively long (40 pages, nearly one quarter of the book) but very worthwhile chapter deals with the endovascular treatment of aneurysms. Here, the radiologist who is unfamiliar with advances in endovascular treatment gets a run down of the various devices used in therapy: different coil types, balloons and stents, liquid embolic material, microcatheters, and wires. What makes for good reading are the sections on the techniques for coiling and stent placement, the strategies and thought processes involved with common and uncommon situations, and the complications involved. There is much to be learned by virtue of this chapter, particularly if one is not involved in interventional neuroradiology—not that reading and digesting this chapter will make the noninterventionalist want to run out and start coiling aneurysms, but at least it will give that person a firm understanding of the field and where it is headed. To this reviewer, this chapter was most interesting, because many previously unappreciated (or forgotten) issues were discussed, among them the reason for the abandonment of tungsten coils, methods of detachment of coils from the pusher wire, the constituents and mechanism of action of bio-

active coils, the different types of stents, and preprocedural/postprocedural care. Specific strategies for coiling large-necked aneurysms (as developed by Dr. Jacques Moret, who is one of the authors) and how to approach confounding or difficult cases are thoroughly described and illustrated. This is an excellent chapter; however, improvement could have been achieved by the use of diagrams, illustrating the devices and their configurations in deployed positions.

The remaining chapters deal with the less common or less frequently treated aneurysms, such as dissecting, atherosclerotic, and fusiform aneurysms; aneurysms seen in association with various disorders, such as neoplasms, trauma, infections, arteriovenous malformations (AVMs), radiation, polycystic kidneys, connective tissue disorders (Ehlers-Daulos and Marfan), vasculitis, and neurofibromatosis; the evaluation and treatment of aneurysmal subarachnoid hemorrhage; which aneurysms require surgery; and follow-up of treated aneurysms.

Most neuroradiologists will find the chapter dealing with nonsaccular aneurysms that arise in the context of accompanying disorders to be of great interest. The case material chosen by the author (Biondi) of this chapter is excellent (in fact, high-quality imaging is present throughout the book) and serves to emphasize the subject's main point. More extensive labeling and an expanded legend in a number of cases would have been helpful, because to many not involved directly in intervention, such labeling and longer description would have cleared up a few figures, as for instance, in a figure that is said to show occlusion of an intranidal aneurysm in an AVM, it may have been helpful to say that the figure showed glue filling the pedicle and the aneurysm.

Although those performing endovascular surgery of intracranial aneurysms will have primary interest in this book, all neuroradiologists should be aware of the material in this book, and it, therefore, is highly recommended.


DOI 10.3174/ajnr.A0578

BOOK REVIEW

Stroke Treatment and Prevention: An Evidence-Based Approach

G.J. Hankey, ed. New York: Cambridge University Press; 2005. 536 pages, \$140.

In his preface, Hankey writes that the aim of his book is, "to provide stroke clinicians (and their patients and families), with ready access to the optimal evidence to guide best practice in acute stroke treatment and (secondary) prevention of recurrent serious vascular events." It is, in my experience, rare that a book so completely meets the author's stated aim as does this immensely informative text. In 400 pages of text and more than 100 pages of references, Hankey provides us with detailed reviews and personal assessments of available literature related to most conditions related to both hemorrhagic and ischemic strokes. As a bonus, there are also excellent chapters dealing



with understanding evidence, organizing acute stroke care, and general supportive acute stroke care.

In 14 chapters organized according to either the major causes of stroke or to therapeutic and preventive issues arising either because of a stroke or with the aim of preventing a stroke, Hankey has compiled a comprehensive data base of available literature. He then provides and analyzes in a meticulous fashion the available

evidence and its quality while also providing, in most cases, Forest plots of the reported studies. For the reader, this greatly simplifies a comparison of the reported results. Along with these clearly presented facts, he then adds his interpretation of the data, as well as a view on their implication for clinical practice. The unusual combination of an inclusive literature review with an analysis by someone with, “clinical experience, acumen and common sense” (from his preface) is rare.

This is not a book for the bedside table; it is packed with facts that, while clearly presented, require concentration and contemplation for full understanding and application. It is a book that should be available in the “trenches” wherever acute stroke diagnosis and care are provided. I would suspect that its value to students and house officers will be clearly demonstrated by the number of copies that mysteriously disappear from departmental libraries, finding their way into on-call rooms and other haunts regularly occupied by those having first-line responsibility for making decisions about the diagnosis and treatment of stroke. No matter what their level of training or experience, this book will be useful to anyone interested in the topic of stroke.

The only meaningful criticism of this book, as recognized by Hankey, is that it will over a relatively short time become dated. It will remain, however, an extremely useful source as long as it is available.

DOI 10.3174/ajnr.A0579

BOOK REVIEW

Pediatric Neuroradiology: Brain, Head, Neck, and Spine (2 Volumes)

P. Tortori-Donati and A. Rossi, eds. New York: Springer; 2005. 1752 pages, 4480 illustrations, \$779.

For years, the standard against which I have judged texts on the subject of pediatric neuroimaging has been A. J. Barkovich's classic *Pediatric Neuroimaging*, currently in its fourth edition and still going strong. After having read the impressive new opus, *Pediatric Neuroradiology*, by Tortori-Donati and Rossi, I may very well have to rethink that standard. In creating this textbook, Tortori-Donati and Rossi set out with the auda-

cious goal of creating perhaps the most comprehensive and sweeping textbook on the subject of pediatric neuroimaging to date, and it appears as if they have done just that.

The 2-volume text spans 45 chapters and 1752 pages. The larger first volume, which accounts for more than two thirds of the book's content, is devoted to imaging of the brain. The second volume covers imaging of the pediatric head, neck, and spine. Topics reviewed in the 27 chapters of the first volume include embryology of the brain, MR of the preterm infant brain, neonatal hypoxic-ischemic encephalopathy, vascular malformations (including a review of endovascular treatment), brain tumors, neurodegenerative disorders, the phakomatoses, and epilepsy. The last 5 chapters of volume 1 focus on state-of-the-art brain imaging techniques and feature in-depth and up-to-date discussions on MR spectroscopy; diffusion-weighted, perfusion-weighted, and functional MR imaging; brain sonography; and MR imaging of the fetal central nervous system.

The considerably shorter second volume is divided nearly evenly between head and neck imaging and spine imaging. Both parts begin with a chapter reviewing embryology and conclude with chapters covering sonographic applications in the head, neck, and spine (including chapters on prenatal sonography). Topics covered in the head and neck section include abnormalities of skull development, craniosynostoses, imaging of the orbits and temporal bones, sinonasal diseases, and cervicofacial vascular malformations. The section on spine imaging includes chapters on congenital malformations, spine and spinal cord tumors, infectious and inflammatory disorders, trauma, and arteriovenous shunts.

A considerable emphasis is placed on understanding imaging in the context of current knowledge about disease pathogenesis, which results in a richer understanding of several diseases that neuroradiologists see on a day-to-day basis. In addition, several topics that have in the past been dealt with superficially in other texts finally get much-deserved attention in this book. Hemolymphoproliferative diseases and treatment-related disorders, rare phakomatoses, pediatric sellar and suprasellar disorders, and spinal arteriovenous shunts are among the more esoteric topics that receive their own chapters. Thankfully, the authors do not allow themselves to become bogged down by excessive minutiae, which is a potential danger in writing a textbook of this scope. Although topics are discussed in exceptional detail within each chapter, none of the information seems superfluous.

The chapters follow a set format and are generally well organized. Within each chapter, sections and subsections are individually numbered. For example, the chapter on brain tumors (Chapter 10) includes discussions on intra-axial tumors and extra-axial tumors, labeled sections 10.2 and 10.3, respectively. The section on intra-axial tumors is further subdivided into subsections on tumors of the posterior cranial fossa (Section 10.2.1) and tumors of the cerebral

