

**Are your MRI contrast agents cost-effective?**

Learn more about generic Gadolinium-Based Contrast Agents.



**FRESENIUS  
KABI**

caring for life

**AJNR**

## **Reassessment of the Craniocervical Junction: Normal Values on CT**

C.A. Rojas, J.C. Bertozzi, C.R. Martinez and J. Whitlow

*AJNR Am J Neuroradiol* 2007, 28 (9) 1819-1823

doi: <https://doi.org/10.3174/ajnr.A0660>

<http://www.ajnr.org/content/28/9/1819>

This information is current as  
of April 18, 2024.

C.A. Rojas  
J.C. Bertozzi  
C.R. Martinez  
J. Whitlow

# Reassessment of the Craniocervical Junction: Normal Values on CT

**BACKGROUND AND PURPOSE:** As the standard of care for the evaluation of the cervical spine shifts from plain radiographs to multidetector row CT (MDCT), a re-examination of the normal anatomic relationships of the occipitovertebral articulations is needed. We aimed to define the normal anatomic relationships of craniocervical articulations on MDCT and address any discrepancies with currently accepted ranges of normal on plain radiographs.

**MATERIALS AND METHODS:** A total of 200 patients underwent an MDCT scan of the cervical spine with multiplanar reconstructions (MPR). We measured the basion-axial interval (BAI), basion-dens interval (BDI), Powers ratio, atlantodental interval (ADI), and atlanto-occipital interval (AOI) in each patient. After statistical analysis, we compared these values to previously accepted data on plain radiographs.

**RESULTS:** Ninety-five percent of the population was found to have a BDI less than 8.5 mm compared with 12 mm on data from plain radiographs. The Powers ratio demonstrated no significant difference compared with data obtained by plain radiographs. Ninety-five percent of the population was found to have an ADI less than 2 mm, compared with 3 mm previously accepted. The AOI demonstrated 95% of the population ranged between 0.5 mm and 1.4 mm. The BAI was difficult to reproduce on CT images.

**CONCLUSION:** Normal values for the craniocervical relationships on MDCT are significantly different from the accepted ranges of normal on plain radiographs. We propose these values as normal for the adult population.

The craniocervical relationships have been studied throughout the decades as indicators of craniocervical dissociation. The cervicocranium is defined as the region extending from the basiocciput to the second cervical interspace.<sup>1</sup> It is held in place by ligaments and articulations between the occiput, atlas, and axis. Unfortunately, this area is difficult to evaluate on plain radiographs because of the multitude of superimposed structures. Therefore, various authors have developed indirect methods to serve as indicators of injury.

Atlanto-occipital dissociation (AOD) injuries include both atlanto-occipital dislocations and atlanto-occipital subluxations. Although dislocations are usually fatal, subluxations are rarely fatal but occur with less frequency than dislocations.<sup>1</sup> Harris et al<sup>2,3</sup> established a reliable and accepted means to diagnose atlanto-occipital dissociations on the contact lateral cervical spine radiograph. The method used by this group included the basion-dens interval (BDI), originally described by Wholey et al,<sup>4</sup> as well as the basion-axial interval (BAI). Harris et al<sup>2</sup> calculated that >95% of adults in their study population had a BDI and BAI less than 12 mm and considered this value as the upper limit of normal.

In 1979, Powers<sup>5</sup> described the Powers ratio, which has been used in the evaluation of atlanto-occipital dissociation. It is considered normal when the value is less than 1. However, this method is only sensitive in the evaluation of anterior atlanto-occipital dissociation. A posterior dissociation or vertical distraction injury could result in a normal value and consequently go undiagnosed.

The atlantodental interval (ADI) is a measurement used to evaluate the atlanto-axial relationship. This distance, described by Hinck et al,<sup>6</sup> is conventionally held to be normal when it is less than 3 mm in men and 2.5 mm in women.

In 1987, Kaufman et al<sup>7</sup> measured the atlanto-occipital joint space in 100 normal children, at 5 evenly spaced points on the cross-table lateral radiograph of the skull. He found that this space was congruent throughout, and at no point should it measure >5 mm. There are no data found in the literature for adults.

Currently, there is no completely reliable approach to the injured cervical spine. As technology advances, MDCT with MPR has become, in many centers, the first step in the evaluation of the acutely injured cervical spine. For this reason, it is in our interest to determine normal anatomic values of the craniocervical junction on the basis of MDCT reconstructed images. Because of magnification in standard radiographic technique, as well as limitations in the accuracy of measurements in plain radiographs, we suspect that the normal values for these measurements are significantly larger than the measurements that would be made on MDCT images.

## Materials and Methods

### Patients

Our patient population consisted of 200 patients who presented to our hospital emergency department between December 2004 and May 2005 and underwent a screening MDCT scan of the cervical spine with multiplanar reconstructions (MPR) as part of a trauma protocol. Patients were evaluated for cervical spine injury and were included in our study if no osseous or soft tissue abnormality was detected on initial CT scan and if the patients were discharged from the hospital without a diagnosis of a cervical spine injury. The subjects selected for our study ranged from 20 to 40 years of age and had no known previous injury or anomaly of the cervical spine. Exclusion

Received February 10, 2007; accepted after revision March 18.

From the University of South Florida College of Medicine, Tampa, Fla.

Paper previously presented at: Annual Meeting of the Radiological Society of North America, November 27, 2006; Chicago, Ill.

Please address correspondence to Carlos A. Rojas, MD, 5225 Bayshore Blvd, Tampa, FL 33611; e-mail: crojas@health.usf.edu

DOI 10.3174/ajnr.A0660

criteria included patients who were further evaluated with flexion-extension radiographs or MR imaging of the cervical spine because of clinical suspicion of a ligamentous injury, as well as patients with endotracheal or nasogastric tubes. Of the 200 patients, 115 were men (57.5%) and 85 were women (42.5%).

### Imaging

We performed cervical spine imaging without intravenous contrast using a 16-section multidetector row scanner, with the following standard protocol:  $16 \times 0.75$ -mm collimation with 1-mm-thick sections, a 0.5-mm overlap, and a pitch of 0.942. Axial images were reconstructed at 1 mm, and 3 contiguous sections were fused for review and storage on a PACS workstation. We routinely obtained reformations in both sagittal and coronal planes from 1-mm axial reconstructions. Multiplanar reformations were reformatted to 3-mm thickness every 3 mm through the cervical spine. A 16-cm FOV,  $512 \times 512$  matrix, 140 kV, and 250 mAs were generally used; however, these factors were sometimes altered to accommodate a patient's body habitus. Examinations selected for inclusion in our study were free from motion artifacts. We analyzed the images using a preset bone window with a window level of 450 HU and a window width of 1700 HU.

### Measurements

We obtained a total of 6 measurements on each patient using a PACS workstation, which included the following: BAI, BDI, Powers ratio, ADI, and bilateral atlanto-occipital interval (AOI). Although the in-plane resolution achievable with the technical parameters mentioned above is 0.325 mm, our workstation provided measurements to the nearest hundredth of a millimeter. These values were rounded to the nearest tenth of a millimeter.

We measured the BAI according to the method described by Harris et al<sup>2,3</sup> as the distance between the basion and the rostral extension of the posterior cortical margin of the body of the axis. The posterior axial line (PAL) is a line drawn along the posterior cortex of the body of the axis and extended cranially. The BAI is the distance between the basion and this line (Fig 1).

We obtained the BDI by measuring the distance from the most inferior portion of the basion to the closest point of the superior aspect of the dens in the midsagittal plane<sup>4</sup> (Fig 2).

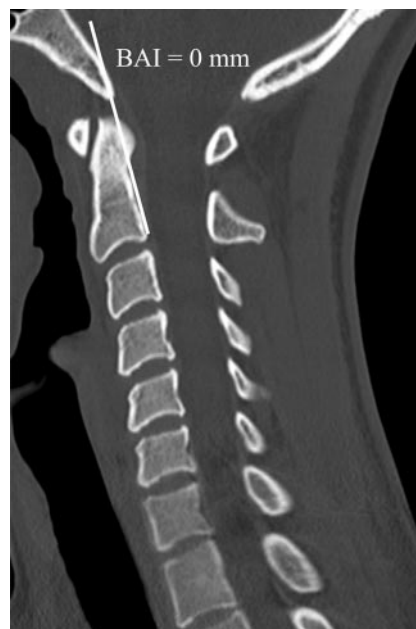We calculated the Powers ratio by dividing the distance between the tip of the basion to the spinolaminar line of the atlas by the distance from the tip of the opisthion to the midpoint of the posterior aspect of the anterior arch of C1<sup>5</sup> (Fig 3).

We measured the ADI by drawing a line from the posterior aspect of the anterior arch of C1 to the most anterior aspect of the dens at the midpoint of the thickness of the arch in craniocaudal dimension.<sup>6</sup> This measurement was performed in the midsagittal plane (Fig 4).

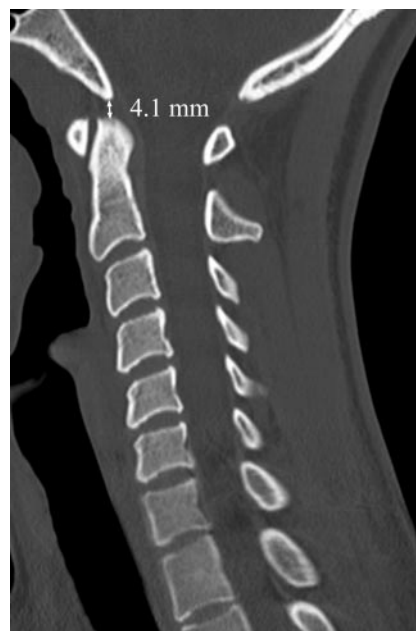We calculated the AOI by drawing a line perpendicular to the articular surfaces of the occipital condyle and the lateral mass of C1. This line was drawn at the center of the articulation by correlating the sagittal and coronal images. Measurements of the AOI were performed bilaterally and the values were averaged (Fig 5).

### Statistical Analysis

For each of the methods, we calculated the mean, SD, standard error of the mean (SEM), and range. Normal maximum values were defined as the value inclusive of 97.5% of the study population. After establishing the normal values, we compared these values to previously accepted data from plain radiographs in the lit-

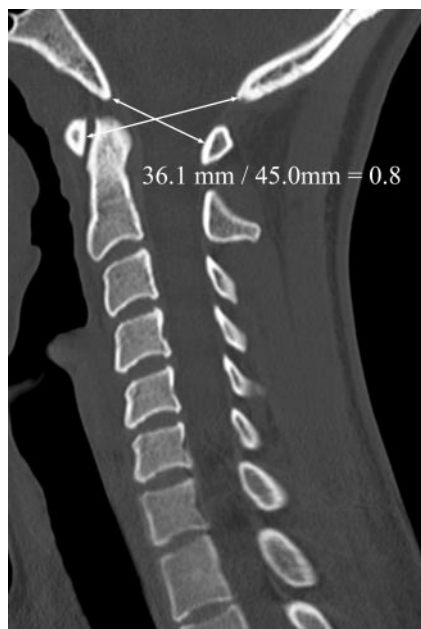

**Fig 1.** BAI. Midsagittal MDCT image of the craniocervical junction demonstrates the posterior axial line drawn along the posterior cortex of the body of the axis and extended cranially. The BAI is the distance between the basion and this line.

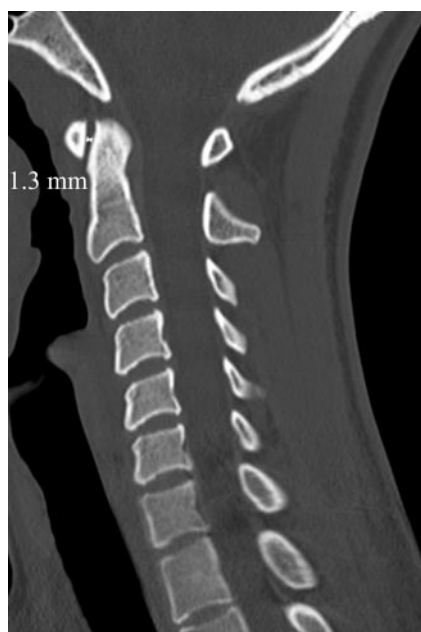

**Fig 2.** Midsagittal MDCT image of the craniocervical junction demonstrates the BDI as the distance from the most inferior portion of the basion to the closest point of the superior aspect of the dens.

erature. In addition, a second examiner repeated each of these measurements on 53 of the patients in our study group, to calculate interexaminer variability. Furthermore, one of the examiners performed each measurement 3 times to calculate intraexaminer variability on 57 of the patients. For interexaminer and intraexaminer comparisons, we used the intraclass correlation measures as described by Shrout and Fleiss.<sup>8</sup> We then calculated correlations for each of the 5 methods of measurement. Finally, we separated the data for male and female subjects and again performed the above calculations to evaluate for sex differences.



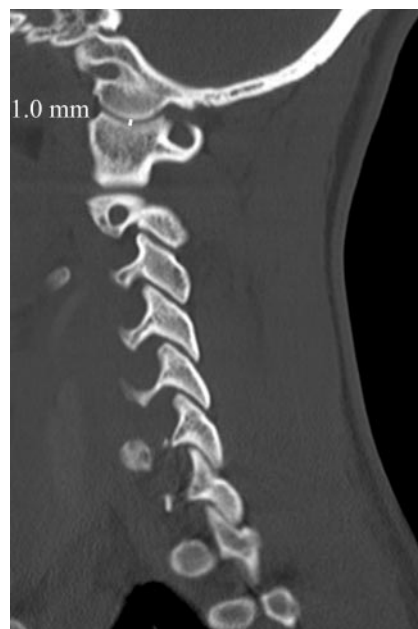**Fig 3.** Midsagittal MDCT image of the craniocervical junction demonstrates the Powers ratio, which is calculated by dividing the distance between the tip of the basion to the spinolaminar line by the distance from the tip of the opisthion to the midpoint of the posterior aspect of the anterior arch of C1.



**Fig 4.** Midsagittal MDCT image of the craniocervical junction demonstrates the AOI, which is calculated by drawing a line from the posterior aspect of the anterior arch of C1 to the most anterior aspect of the dens at the midpoint of the thickness of the arch in craniocaudal dimension.

## Results

Our results demonstrated significant variances from the previously accepted normal values on plain radiographs for several of the methods used (Table 1). The BAI was found to be highly variable and difficult to reproduce on CT images with a large SEM, and a number of subjects measuring greater than the upper accepted norm of 12 mm.<sup>2</sup> When measuring the BAI, we found a large interexaminer and intraexaminer variability, often because of differences in how the PAL was drawn.



**Fig 5.** Sagittal MDCT image of the craniocervical junction demonstrates the AOI, which is calculated by drawing a line perpendicular to the articular surfaces of the occipital condyle and the lateral mass of C1. This line is drawn at the center of the articulation by correlating the sagittal and coronal images.

The commonly accepted BDI normative cutoff<sup>2</sup> of 12 mm was found to be excessive because our maximum distance recorded was 9.1 mm, and a distance of 8.5 mm would be inclusive of >95% of patients. A recently reported article by Gonzalez et al,<sup>9</sup> which echoes the above findings, demonstrated a mean BDI of 4.7 mm and a maximum of 9 mm.

Analysis of the Powers ratio demonstrated >95% of the population to be <0.9, which corresponds with the currently accepted norm.<sup>5</sup> Although the normal maximum ADI is held to be ≤3 mm in men and ≤2.5 mm in women,<sup>6</sup> we found it to be normal when it was less than 2 mm in both sexes.

In addition to being a very interesting measurement, as we will discuss later, the AOI was easily reproducible and had a small SEM. No previous data in adults were found in the literature. Ninety-five percent of our population had an AOI between 0.6 and 1.4 mm, with a mean value of 1.0 mm.

Evaluation of the data for interexaminer variability with the method described by Shrout and Fleiss<sup>8</sup> demonstrated that the BDI and Powers ratio provided the highest degrees of reliability (lowest variability between separate examiners) with values of 0.84 and 0.87, respectively (Table 2). The AOI provided nearly the same degree of consistency. The ADI and BAI provided the least reliability in our study population. Evaluation of the methods for intraexaminer variability failed to reveal any significant variability for any of the methods tested. When comparing men and women, we found no differences in any of the measured values.

## Discussion

Injuries to the craniocervical region can be subtle and impossible to detect on a radiograph of the lateral cervical spine.<sup>1</sup> A recent study has demonstrated that standard cervical spine radiographs are inadequate to fully evaluate the cervical spine after blunt trauma.<sup>10</sup> Meanwhile, the use of CT for the evalu-

**Table 1: Normal anatomic relationships of the craniocervical junction on MDCT in 200 patients and comparison with accepted values on plain radiographs\***

Method	Mean	SD	Range	MDCT Normal Value†	Plain Radiograph Normal Value <sup>2,5,6</sup>
BAI	3.4	4.64	−8.7–26.0	Not reliable	<12.0
BDI	5.7	1.39	1.4–9.1	<8.5	<12.0
Powers ratio	0.8	0.08	0.6–1.2	<0.9	<1.0
ADI	1.3	0.37	0.5–2.4	<2.0 in both sexes	<3.0 men <2.5 women
AOI	1.0	0.23	0.5–1.8	<1.4	No data in adults

**Note:**—MDCT indicates multidetector row CT; BAI, basion-axial interval; BDI, basion-dens interval; ADI, atlantodental interval; AOI, atlanto-occipital interval.

\* Results are given in millimeters with the exception of the Powers ratio.

† Normal value is the maximum value for 97.5% of the population.

**Table 2: Interexaminer variability of methods of craniocervical junction evaluation\***

Method	Shrout-Fleiss Reliability
BAI	0.54
BDI	0.84
Powers ratio	0.87
ADI	0.65
AOI	0.77

**Note:**—BAI indicates basion-axial interval; BDI, basion-dens interval; ADI, atlantodental interval; AOI, atlanto-occipital interval.

\* Value of 1 represents maximum reliability.

ation of the cervical spine has grown rapidly since the advent of helical and multidetector scanners. In many institutions, including our own, it is now the examination used in the initial assessment of an acutely traumatized patient, rather than a standard radiographic evaluation. The cost-effectiveness, ability to be performed rapidly, high sensitivity, and specificity make CT the ideal screening tool.<sup>11</sup> As the technology has advanced, we have felt the need to establish normal values on the now widely used MDCT images. The results revealed significant differences between the normal values of commonly used methods to evaluate for AOD on plain radiograph, as reported in the literature and those obtained from our study population on the basis of MDCT images.

In an ideal setting, our patient population would have only included healthy volunteers or patients undergoing MDCT of the cervical spine for an indication other than trauma. Unfortunately, we did not find this to be practically feasible and have included patients who sustained some form of trauma as an indication for evaluation of the cervical spine. Although this was a limitation of our study, we felt that the strict criteria for inclusion in the patient population markedly reduced the possibility that a patient with a true abnormality of the cervical spine was included in the study.

The accuracy of our measurements could theoretically be limited by the fact that we collected our data using measurements to the nearest tenth of a millimeter, though the true in-plane resolution of the examinations performed is 0.325 mm. Currently, scanning protocols of cervical spine trauma with the use of MDCT are fairly standardized and result in similar in-plane resolution.<sup>12</sup> Furthermore, most radiologists obtain these measurements with workstations similar to the ones used in this study. Therefore, we do not feel that this discrepancy is likely to alter the validity of our data.

We found the BAI method difficult to reproduce for various reasons, including the irregular contour of the posterior cortex of the vertebral body of the axis, as well as the inability

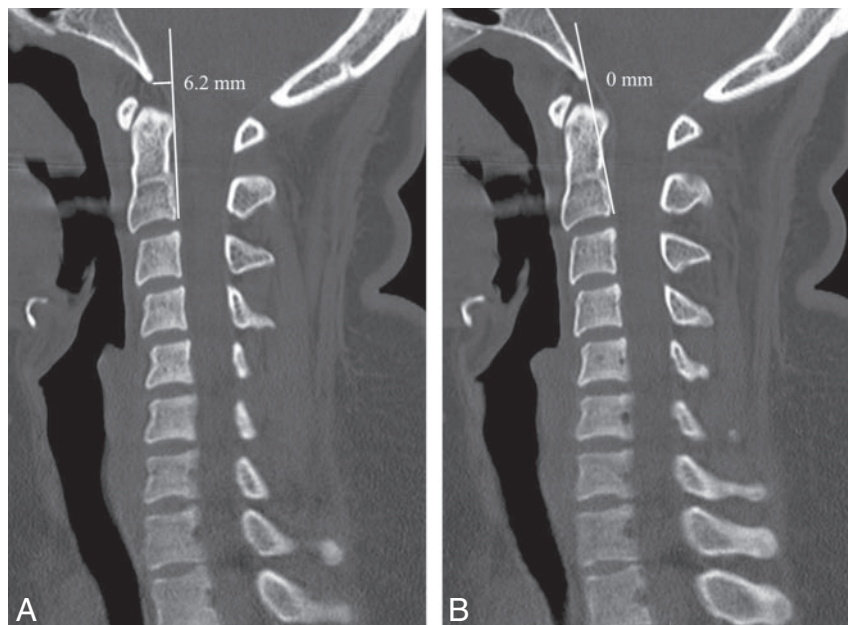
to obtain a pure midsagittal view. Therefore, the examiners tended to draw the PAL in a different manner and on different images, which resulted in significantly different BAI values for the same patient (Figs 6A, B). For these reasons, we believe the BAI is not useful in the evaluation of AOD on MDCT images. In contrast, in studies of radiographs of the cervical spine, the sensitivity of the BAI has been found to be as high as 100%. However, this result was only when combined with the BDI, and only in those patients in whom the necessary osseous landmarks could be identified.<sup>3</sup>

Conversely, the BDI was an easily performed and reproduced measurement on MDCT images. The normal values for our patient population correlated well with data obtained by Gonzalez et al<sup>9</sup> but varied significantly from earlier reported data by Lee et al<sup>13</sup> and Harris et al<sup>2,3</sup> which were based on plain radiographs. Harris et al<sup>2,3</sup> determined the normal values for the BDI to be between 3.2 and 11.8 mm, which are the most commonly accepted values because of the high sensitivity for detecting AOD when used in conjunction with the BAI values. However, use of the BDI method alone has been found to have a sensitivity of 50% on plain radiographs.<sup>13</sup> The differences between BDI data collected from MDCT images and plain radiographs likely result from many factors such as magnification, positioning, and less certainty regarding osseous landmarks on plain radiographs.

The Powers ratio is limited to the detection of anterior atlanto-occipital dissociation<sup>5</sup> and requires identification of the opisthion, which, in studies of lateral cervical spine radiographs, was only identifiable in 56% to 84% of patients.<sup>2,14</sup> It also uses a required landmark, the spinolaminar line of C1, which is not present in congenital nonfusion of the posterior arches of the atlas. The sensitivity of the Powers ratio in the detection of anterior atlanto-occipital dissociation on lateral cervical spine radiographs has been found to be between 33% and 60%.<sup>3,13</sup> Because this value represents a ratio, we found no significant difference when comparing our results of MDCT images with the established normal values in the literature on plain radiographs.

The ADI, also known as the predental space, is very small and is maintained by the presence of the atlantodental ligament, alar ligaments, and transverse atlantal ligament. Thus, an abnormally widened predental space is an indirect indicator of injury to the craniocervical junction ligament, and specifically, injury to the transverse atlantal ligament.<sup>15</sup> Using MDCT images, we could define a smaller range of normal values for this space compared with the published data on plain radiographs.





**Fig 6.** Interexaminer variability of the BAI. Midsagittal MDCT image of the craniocervical junction demonstrates the posterior axial line (PAL) drawn along the posterior cortex of the body of the axis and extended cranially. *A*, Examiner A draws the PAL on the basis of a single interpretation of the posterior cortex of the body of the axis. *B*, Examiner B draws the PAL using a different interpretation of the posterior cortex of the body of the axis.

On review of the literature, the normal values for the AOI had not yet been established in adults. Kaufman et al<sup>7</sup> evaluated this space in children and described their technique for performing these measurements.<sup>7</sup> We found that measurements of the AOI were easily reproducible, were congruent throughout the joint space on sagittal and coronal images, and demonstrated little variability.

From a practical standpoint, the landmarks used to perform the methods discussed above are difficult to precisely localize on plain radiographs and are subject to inherent radiographic magnification. Furthermore, the Powers ratio and BAI involve drawing multiple lines and, in the Powers ratio, performing a calculation. We believe that an effective method in the evaluation of AOD should be simple, accurate, easily reproducible, and able to be performed quickly by the busy radiologist who assesses the acutely traumatized patient in the emergency department.

On MDCT MPR images, magnification is negligible and direct visualization of the joint spaces can be performed. Specifically, with use of MPR, direct evaluation of the atlanto-occipital joint is possible. Therefore, we believe that the relationship between the occipital condyle and the lateral mass of the atlas becomes the single most important method in the detection of AOD. From a conceptual standpoint, any separation between the cranium and cervical spine would be seen as an increase in this space.

## Conclusion

In summary, defining AOD has been the interest of many authors in the past, and several methods on the basis of plain radiographs of the cervical spine have been established in the literature. However, normal values for craniocervical relationships as seen on MDCT are significantly different from the accepted ranges of normal as seen on radiographs. These differences are likely the result of multiple factors including magnification, lack of certainty in

the identification of osseous landmarks, and patient positioning. When normal relationships among the atlas, axis, and occiput are established, the sensitivity of MDCT in the detection of ligamentous and subtle bony injuries will likely be increased. We suggest that these new values be considered as the normal ranges in adults. Furthermore, we found the basion dental and atlanto-occipital intervals to be the most easily performed and reproducible methods of evaluating the craniocervical junction for AOD.

## Acknowledgment

The authors thank David Boulware, MS, senior biostatistician with the Biostatistics Core, H. Lee Moffitt Cancer Center and Research Institute, Tampa, Fla.

## References

- Harris J Jr. The cervicocranium: its radiographic assessment. *Radiology* 2001;218:337–51
- Harris JH Jr, Carson GC, Wagner LK. Radiologic diagnosis of traumatic occipitovertebral dissociation: 1. Normal occipitovertebral relationships on lateral radiographs of supine subjects. *AJR Am J Roentgenol* 1994;162:881–86
- Harris JH Jr, Carson GC, Wagner LK, et al. Radiologic diagnosis of traumatic occipitovertebral dissociation: 2. Comparison of three methods of detecting occipitovertebral relationships on lateral radiographs of supine subjects. *AJR Am J Roentgenol* 1994;162:887–92
- Wholey MH, Bruwer AJ, Baker HL Jr. The lateral roentgenogram of the neck; with comments on the atlanto-odontoid-basion relationship. *Radiology* 1958;71:350–56
- Powers B, Miller MD, Kramer RS, et al. Traumatic anterior atlanto-occipital dislocation. *Neurosurgery* 1979;4:12–17
- Hinck VC, Hopkins CE. Measurement of the atlanto-dental interval in the adult. *Am J Roentgenol Radium Ther Nucl Med* 1960;84:945–51
- Kaufman RA, Carroll CD, Buncher CR. Atlantooccipital junction: standards for measurement in normal children. *AJNR Am J Neuroradiol* 1987;8:995–99
- Shrout PE, Fleiss JL. Intraclass correlations: uses in assessing rater reliability. *Psychol Bull* 1979;86:420–28
- Gonzalez LF, Fiorella D, Crawford NR, et al. Vertical atlantoaxial distraction injuries: radiological criteria and clinical implications. *J Neurosurg Spine* 2004;1:273–80
- Gale SC, Gracias VH, Reilly PM, et al. The inefficiency of plain radiography to evaluate the cervical spine after blunt trauma. *J Trauma* 2005;59:1121–25
- Diaz JJ Jr, Aulino JM, Collier B, et al. The early work-up for isolated ligamentous injury of the cervical spine: does computed tomography scan have a role? *J Trauma* 2005;59:897–903; discussion 903–04
- Hogan GJ, Mirvis SE, Shanmuganathan K, et al. Exclusion of unstable cervical spine injury in obtunded patients with blunt trauma: is MR imaging needed when multi-detector row CT findings are normal? *Radiology* 2005;237:106–13
- Lee C, Woodring JH, Goldstein SJ, et al. Evaluation of traumatic atlantooccipital dislocations. *AJNR Am J Neuroradiol* 1987;8:19–26
- Nance EP Jr, Lams P, Gerlock AJ Jr. The opisthion on the lateral radiograph of the cervical spine. *AJR Am J Roentgenol* 1979;133:905–08
- Deliganis AV, Baxter AB, Hanson JA, et al. Radiologic spectrum of craniocervical distraction injuries [published erratum appears in *Radiographics* 2001;21:520]. *Radiographics* 2000;20:S237–50